

Correspondence

Psychotic depression, subcortical arteriosclerotic encephalopathy and holocaust-conditioned posttraumatic stress disorder

Stefan Kropp, Jann Schlimme, Udo Schneider, Department of Clinical Psychiatry and Psychotherapy, Hanover Medical School, Germany:

We report the case of a 79-year-old, white married patient, who on admission revealed that she was weary of life. On mental state examinations she was alert, clear-thinking and orientated. Formal thinking was coherent, the contents of which showed a marked delusion of poverty without any indication of hallucination. The patient suffered a severe lack of motivation and showed only fleeting signs of emotion. Psychomotor inhibition was prominent. She admitted to continual suicidal thoughts, although lacked the drive to carry out such an attempt. Hamilton Depression Rating Score (HAMD) was 41 points on admission. Relatives reported her screaming out in terror while asleep. Medical history included chronic obstructive lung disease, hyperthyroidism (now stable) and osteoporosis. A subcortical arteriosclerotic encephalopathy was apparent in magnetic resonance imaging.

Throughout World War II, the patient was in hiding in Germany because she was Jewish, and was in constant fear of being detected and deported. Her father and all other members of the family except her mother did not survive the war and the extermination of the Jews.

Despite initial treatment with 30 mg mirtazapine and 2 mg risperidone her condition worsened. The patient became distraught, withdrew into herself, refused to accept any form of liquid or nourishment and became incontinent. She lost orientation as to time, place or person. She was preoccupied with the thought that someone was waiting to kill her. This disturbance of consciousness was most likely associated with flashbacks which occur in patients with posttraumatic stress disorder (PTSD; meeting DSM-IV criteria) and which is common in Holocaust survivors [1,2]. This was probably triggered off by dehydration, exacerbating the subcortical arteriosclerotic encephalopathy. Due to her poor health, all medication was discontinued. She received medical care and her condition stabilized. Then further treatment was started with 75 mg of sertraline due to its proven efficacy on delusional symptoms in depression [3], combined with a kava-extract containing product. After 2 weeks of symptoms such as anxiety and delusions improved, while no severe side-effects were observed. She regained her sense of orientation and no longer had suicidal ideas. She still suffered with a mild degree of delusion of poverty; however, HAMD dropped to 12 points and the patient was discharged home in a satisfactory condition. In conclusion, selective serotonin

re-uptake inhibitor (SSRI) treatment of PTSD-associated major depression seems to be effective and further study might clarify the role of SSRIs in the treatment of this disease.

References

1. Kuch K, Cox BJ. Symptoms of PTSD in 124 survivors of the Holocaust. *American Journal of Psychiatry* 1992; 149:337–340.
2. Beinsheim H. Die K.Z.-Neurose rassistisch Verfolgter. *Nervenarzt* 1960; 31:462–469.
3. Zanardi R, Franchini L, Gasperini M, Perez J, Smeraldi E. Double-blind controlled trial of sertraline versus paroxetine in the treatment of delusional depression. *American Journal of Psychiatry* 1996; 153:1631–1633.

Committal of a patient due to media influence? A case report

Peter J. Dean, Herman E. Lombard, Steve Wilkes, Henry Bennett Centre, Waikato Hospital, Hamilton, New Zealand:

We wish to present a case of committal against the recommendation of the Responsible Clinician, brought about by pressure from the media and patient's family. With recent amendments to the New Zealand Mental Health Act emphasizing consultation with families, we speculate that more cases of this type may occur.

David has a 13-year history of schizophrenia. For 8 months he had a peripatetic lifestyle. On return to his mother's home, he was referred for assessment under the Mental Health Act. David presented with loosening of associations, delusions of identity, ideas of reference, thought insertion, thought broadcast and auditory hallucinations. He expressed no suicidal ideation and no thoughts of harm to others. In view of this, he was committed for further assessment.

David was no management problem, with appropriate social interaction. Plans were made for discharge following trial leave. David declined ongoing psychiatric care.

A number of political agencies made contact to ask about the 'dangerous psychotic' who was about to be released into the community. A second opinion was sought, which concurred with the view that there were no grounds to suspect dangerousness. The Ministry of Health strongly recommended that he remain an inpatient until at least the end of the assessment period, as it was likely that the press would print the story. Unfortunately, a sensationalist article appeared on the front page of the local paper. An application to the District Court for a Treatment Order was made in order to prevent further publication of the outcome.

The Court hearing was unusual in that the Responsible Clinician and supporting clinicians recommended that David be discharged from the Act. The judge ruled that David should be detained as an inpatient on the grounds

of psychological distress to the family and seriously diminished capacity to care for himself due to dysfunctional social interactions. Despite this extreme provocation, David presented himself in a dignified and appropriate manner.

The media's sensational report impacted on the clinical care of our patient. The article conveyed an impression that this psychotic individual was dangerous. It included descriptions of unrelated homicides, while a more balanced article was placed in a less prominent position. Nairn has observed that journalistic devices for creating 'newsworthy' items undermine positive portrayals of the mentally ill [1].

The implication of the judge's ruling is that eccentric social functioning could be grounds for detention under the Mental Health Act. Despite 'serious psychological distress', David's family was very willing to have him under their care for leave. Applebaum notes that judges, across the world, have intuitive criteria and a moral sense of involuntary commitment, allowing a bending of strict interpretations of the law [2].

This case reflects an apparent trend within New Zealand towards more paternalistic care and less autonomy in the care of the mentally ill; similar to that experienced in the UK [3]. There seems to be an increase in the pressure from society, reflected in the media, to restrict our patients, based on an assumption that psychiatric patients are dangerous and community care is failing.

References

1. Nairn R. Does the use of psychiatrists as sources of information improve media depictions of mental illness? A pilot study. *Australian and New Zealand Journal of Psychiatry* 1999; 33:583-589.
2. Applebaum PS. Almost a revolution: an international perspective on the law of involuntary commitment. *Journal of the American Academy of Psychiatry and Law* 1997; 25:135-147.
3. Hotopf M, Wall S, Buchanan A, Wessly S, Churchill R. Changing patterns in the use of the Mental Health Act 1983 in England 1984-96. *British Journal of Psychiatry* 2000; 176:479-484.

Signal transmission, schizophrenia and the limits to biological psychiatry

N. McLaren, Darwin, Australia:

After an extensive review, Dean [1] left no doubt that evidence for a specific neurochemical defect in schizophrenia was contentious at best, even contradictory. He concluded: 'Data from both neuroimaging and post-mortem studies have identified changes in the presynaptic proteins and/or function in the brains of schizophrenic patients . . . Changes in functioning of presynaptic processes could be a component of the pathology . . . It would, therefore, seem that the focus

of future drugs should change from blockade of the post-synaptic receptor to modulation of presynaptic function, that is, "modulate signal transmission" rather than "reduce signal reception"' (p.566).

At first glance, Dean would appear to have espoused the extreme view of biological psychiatry, Maudsley's aphorism that 'Mental disease just is brain disease' (cited in [2, chap.2]). At different points he stated: ' . . . over-active dopaminergic neurones cause the psychoses associated with schizophrenia' (pp.560-561), or 'As the molecules in these processes are isolated and their function better understood, it should be possible to determine if changes in a single protein common to all affected presynaptic processes is the cause of schizophrenia' (p.566). That is, he adopts the reductionist concept of a unitary biological cause of this complex disorder, with all that that view entails. If he had not done so, his search among the proteins of the presynaptic neurones would become incoherent [2, chap.2].

The language of his review appears to soar beyond mere detail. For example, ' . . . the dopamine hypothesis of schizophrenia still requires total validation . . .' (p.562), or the case for an increase in GABA receptors is only 'less compelling' after contradictory evidence, while an inability to replicate results is a 'paradigm' (p.565). Such bold phraseology may induce the less-sceptical reader to believe that the vast outpouring of research he reviewed amounts to something substantial, but it does not. All Dean established was that the case for a biological cause for schizophrenia is no stronger than the case for psychological causation of this mysterious condition. Now this, surely, is a bold claim?

Not really. In arguing that the 'primary lesion' is presynaptic, all he is saying is that input should be accorded greater significance. But input is such a general term as to be nearly meaningless: input from what to what? Which synapses, in which brain nuclei? The brain is an ineffably complex organ; part of its complexity arises from its capacity to act upon itself. In this sense, one part of the brain is presynaptic to another part, and acts upon it as part of its normal function. Therefore, if we say that the 'primary lesion' is presynaptic, we are allowing the possibility that the disorder arises by virtue of the brain acting back upon itself. That recursive action may in fact be mentally determined, and is therefore not necessarily pathological, even if its outcome is. For example, if I decide to close one eye for the rest of my life, I would eventually lose vision in that eye. I expect that the visual pathways in my brain would show pathological changes as a result. In this case, the receptor pathology would clearly be the result of a presynaptic event, which is itself just part of a very long chain of pre- and post-synaptic elements. However, at their initiation, these are the result

of a willed action for which there is no biological substrate [2, chap.2]. Ultimately, such pathology as exists can be traced back to a mental event. Of course, this is not what biological psychiatry dictates, but I am utterly unconvinced by the claims of biological psychiatry [3].

Biological psychiatry looks for pathological changes, and most authors uncritically assume that such changes as they find are necessarily primary. There is no reason to believe this. Any change can be the result of an earlier change; for the brain, since mental function has a physical substrate, the initiating event may well be the subject's own mental state. There is no a priori reason why this should not be the case. Think of programming or input errors in computers. These have a physical substrate, but nobody is interested in the computer's function at that level. What counts is its informational state, not the physical realisation of that state [2, chap.12].

Dean's error, of believing that any changes are necessarily primary, is not new. This type of error will keep on happening because biological psychiatrists refuse to lift their heads from their microscopes to look at the larger issues in their field. The race is on to find the elusive schizococcus; nobody has time to ask the obvious question of whether there can in fact be such a thing, which is a metaphysical question and therefore not amenable to an empirical answer [2, chap.15]. By refusing to acknowledge that there may in fact be metaphysical questions for which their research is incapable of generating answers, biological psychiatrists are placing themselves in the same class as psychoanalysts [2, chap.6] and radical behaviourists [2, chap.4], not so much scientists as propagandists.

References

1. Dean B. Signal transmission, rather than reception, is the underlying neurochemical abnormality in schizophrenia. *Australian and New Zealand Journal of Psychiatry* 2000; 34:560–569.
2. McLaren N. *The future of psychiatry*. Chaps 2–4, 12, 15. www.futurepsychiatry.com. Established January 2000.
3. Guze SB. *Why psychiatry is a branch of medicine*. New York: Oxford University Press, 1992.

Reply to Dr McLaren

Brian Dean, Mental Health Research Institute, Melbourne, Australia:

I would first like to thank Dr McLaren for acknowledging the extensive nature of my recent review [1]. It would seem that Dr McLaren then goes on to conclude that my interpretation of the data in this review is without value. This is because I have made the 'error of believing that any [physical] changes are necessarily

primary [in causing the symptoms of mental illness] . . . [and this] will keep on happening because biological psychiatrists refuse to lift their heads from their microscopes to look at the larger issues'. Dr McLaren has put this argument previously [2], along with the argument that the 'biopsychosocial model' of psychiatry is of no value [3].

To most of us in medical research, science is an inclusive rather than exclusive exercise in attempting to improve the lifestyle of those with illness. As such, rather than simply refuting Dr McLaren's position that the answers to the causation of mental illness lie in the 'mental' rather than 'biological' state of the brain, it would seem better to assess where these two hypotheses may overlap. Dr McLaren rightly points out that the human brain is a complex organ, the function of which is dependent on complex interactive processes. The research I describe in my review is designed to understand how the components of the brain that allow it to carry out many of its function may be deranged in mental illness. It does not exclude the possibility that mental illness is due to a derangement of higher brain function. Like the great Australian neuroscientist, John Carew Eccles [4], Dr McLaren suggests that mental processes may affect the operational integrity of the brain. While this is an excellent working theory, there is a paucity of data on whether an abstract 'mind' exists and how it functions, let alone enough data to allow the study of its abnormalities in mental illness. Even despite this paucity of data, I do view research designed to understand the complex 'mind/brain' relationship [5] to be of value, even though the immediate benefits of such research are not clear. However, until this research generates some convincing and testable hypothesis as to the cause of mental illness, I believe there is also great value in continuing to study the structure of the human brain and how it may be altered in these illnesses. Surely, Dr McLaren would agree that all efforts must be made to reduce the burden that mental illness places on sufferers of those illnesses.

Those committed to a single point of view can take many statements out of context. Unfortunately, Dr McLaren is perhaps over-zealous in taking quotations from my review to support his position. For example, a quote he references back to my review is '... the dopamine hypothesis of schizophrenia still requires total validation . . .' Dr McLaren states that this indicates an idea of 'certainty which soars above mere detail'. Importantly, the sentence quoted actually states that 'While the dopamine hypothesis of schizophrenia still requires total validation, studies using brain tissue obtained at autopsy and PET suggest there are changes in the functioning of the dopaminergic systems in

subjects with schizophrenia'. The key word in the sentence being 'suggest', not a word associated with certainty. Dr McLaren also chooses to totally ignore my closing remark that the most important outcome from the acceptance of my hypothesis that presynaptic abnormalities are important in the pathology associated with schizophrenia would be to re-direct drug design programmes to targets other than postsynaptic receptors. Given the need to develop better drugs with which to treat schizophrenia, I would have thought even Dr McLaren would be in favour of ideas being developed and discussed in this important area of pharmacology.

In closing, I would like to correct another error made by Dr McLaren. I am not a psychiatrist, I am a biologist who chooses to use my expertise in attempting to understand the processes that precipitate schizophrenia. Unfortunately, I have not looked down a microscope in many years, but I have certainly looked away from whatever technology I am using in an attempt to appreciate and understand the views of others. Perhaps this would be a good ethos for the 'mind over brainers' to adopt when reading reviews of other areas within the broad horizons of psychiatric research.

References

1. Dean B. Signal transmission, rather than reception, is the underlying neurochemical abnormality in schizophrenia. *Australian and New Zealand Journal of Psychiatry* 2000; 34:560–569.
2. McLaren N. Is mental disease just brain disease? The limits to biological psychiatry. *Australian and New Zealand Journal of Psychiatry* 1992; 26:270–276.
3. McLaren N. A critical review of the biopsychosocial model. *Australian and New Zealand Journal of Psychiatry* 1998; 32:86–92.
4. Eccles JC. Do mental events cause neural changes analogously to the probability of quantum mechanics? *Proceedings of the Royal Society of London, Series B, Biological Science* 1986; 227:411–428.
5. Eccles JC. Evolution of consciousness. *Proceedings of the National Academy of Sciences* 1992; 89: 7320–7324.

Maintenance electroconvulsive therapy in schizophrenia

John Stevens, Peter Cheung, Tim Lambert, Melbourne, Australia:

The role of electroconvulsive therapy (ECT) is recognized in acute schizophrenia, and as an alternative to antipsychotics in patients with treatment-resistant schizophrenia [1]. However, the use of maintenance electroconvulsive therapy (M-ECT) is less well defined. Our *Index Medicus/Medline* search found only 12 reports of M-ECT in schizophrenia; only six of them specifically describe its use in schizophrenia [2], and only two are systematic research studies.

One study compared continuation electroconvulsive therapy (C-ECT) alone, with combination C-ECT and flupenthixol, and flupenthixol alone [2]. In this study, a significant relapse rate of 93% was noted with the use of either flupenthixol or C-ECT alone compared with only a 40% relapse rate following combination of C-ECT and flupenthixol. It should be noted that C-ECT was only given weekly for 4 weeks, and then bi-weekly for 5 months (total 14 C-ECT treatments), which may explain the high rate of relapse with C-ECT.

The other study was a retrospective study with a mixed sample [3]. However, those with a diagnosis of schizophrenia alone (three patients) received a longer course of M-ECT than patients in the previous study [2], in the order of 35–88 ECT treatments. The three patients were reported to have made significant improvement in the areas of level of functioning, discharge after prolonged hospitalization or reduction in aggression. We would like to report a patient who has required ongoing ECT treatment to avert deterioration of his mental state.

Mr L was a 50-year-old, separated man on a disability support pension living in supported accommodation. He had a 34-year history of chronic, paranoid, treatment-resistant schizophrenia with significant history of violence. He was first diagnosed at age 16, and required multiple prolonged admissions during his late teens and first 10 years of his adult life. He was reasonably stable between the ages of 28 and 38 with regular fluphenazine decanoate. However, following the transfer of his care to his general practitioner, he missed his depot medication and deteriorated rapidly, presenting with acute psychotic symptoms, disinhibition, verbal and physical aggression.

Over the next 6 months, he was admitted on five occasions to acute psychiatric units. Multiple agents including atypical antipsychotics in combination with depot antipsychotics were utilized with virtually no response. However, he did respond satisfactorily, albeit briefly, to short courses of ECT (usually 5–6 treatments) with disappearance of psychotic symptoms and physical aggression. The latter were important target symptoms as there was considerable concern over the potential for violence in this situation of manifest treatment resistance.

During his last admission, Mr L was transferred to a secure extended care ward with the aim of commencing him on clozapine. He remained there for the next 12 months. Unfortunately, he developed clozapine-induced neutropenia and clozapine was ceased. The patient, in addition to his already established treatment-resistant schizophrenia, then developed a super-sensitivity-like exacerbation of his psychosis on withdrawal of the clozapine. Over this period, he received regular short courses of ECT, but deteriorated rapidly each time upon

cessation. Hence, he was prescribed M-ECT, initially weekly. He suffered from confusion (for a couple of days after ECT) and short-term memory impairment, but no other side-effects of the M-ECT.

Mr L was successfully discharged after receiving 42 treatments. He lives alone with intensive case management, and receives M-ECT 4-weekly (66 treatments to date). His improvement has been sustained. He no longer has confusion or memory impairment.

In conclusion, M-ECT has substantially improved Mr L's function and independence. Questions are how long to continue M-ECT and at what frequency? Mr L himself is keen to have ECT treatment terminated.

References

1. Fink M, Sackheim HA. Convulsive therapy in schizophrenia? *Schizophrenia Bulletin* 1996; 220:27–39.
2. Chanpattona W, Chakrabhand MLS, Sackheim HA *et al.* Continuation ECT in treatment-resistant schizophrenic: a controlled study. *Journal of ECT* 1999; 15:178–192.
3. Stiebel VG. Maintenance electroconvulsive therapy for chronic mentally ill patients: a case series. *Psychiatric Services* 1995; 46:765–268.

Uncommon self-mutilation in a borderline personality disorder patient

Jens D. Rollnik, Department of Neurology and Clinical Neurophysiology, Udo Schneider, Felix Wedegaertner, Thomas J. Huber, Hinderk M. Emrich, Department of Clinical Psychiatry and Psychotherapy, Medical School of Hanover, Hanover, Germany:

Self-mutilation (SM) might be understood as a morbid self-help effort providing rapid but temporary relief from feelings of depersonalisation, guilt, rejection and boredom, as well as hallucinations, sexual preoccupations and chaotic thoughts [1]. Self-mutilation in patients suffering from borderline personality disorder is common,

occurring in up to 50% [2]. Therapeutic approaches to self-injurious behaviour employ opioid antagonists [3], neuroleptics such as clozapine and risperidone [4], and behavioural treatment [5].

We report on a 26-year-old woman with a borderline personality disorder associated with anorexia nervosa and substance abuse (diazepam, alcohol) for 7 years. Self-mutilation started in 1996 with a delusion of dermatozoonosis. She started scratching only one place on her head. Several dermatologic consultants could not find an organic cause. Wound infections and an osteomyelitis of the skull bone lead to a large tissue defect in 1998 (about 5×2 cm). In April 2000 our patient experienced a minor head injury. She was admitted to a neurologic clinic with symptomatic focal epilepsy, global aphasia and right hemiparesis. Magnetic resonance imaging revealed the large tissue defect with skull bone damage and intracerebral air inclusion left frontoparietal (Fig. 1). The patient underwent surgery to cover the wound. Hemiparesis and aphasia improved and she was discharged after wound healing. Further therapy was refused.

The bad course of the disease in our patient underlines the necessity of further scientific work to improve the understanding of SM. Dermatologists should be aware of symptoms such as delusion of dermatozoonosis to enable early psychiatric intervention.

References

1. Favazza AR. The coming age of self-mutilation. *Journal of Nervous and Mental Disease* 1998; 186:259–268.
2. Dulit RA, Fyer MR, Leon AC, Brodsky BS, Frances AJ. Clinical correlates of self-mutilation in borderline personality disorder. *American Journal of Psychiatry* 1994; 151:1305–1311.
3. Thompson T, Hackenberg T, Cerutti D, Baker D, Axtell S. Opioid antagonist effects on self injury in adults with mental retardation: response from and location as determinants of medication effects. *American Journal of Mental Retardation* 1994; 99:85–102.

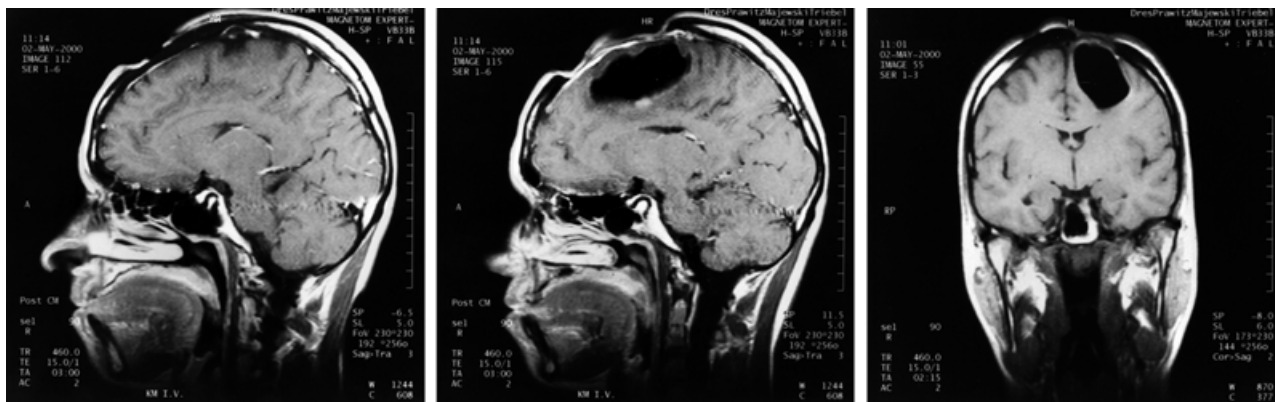


Figure 1. Magnetic resonance imaging of the patient's head. The skull bone is damaged and there are intracerebral air inclusions

4. Chengappa KN, Ebeling T, Kang JS, Levine J, Parepally H. Clozapine reduces severe self-mutilation and aggression in psychotic patients with borderline personality disorder. *Journal of Clinical Psychiatry* 1999; 60:477–484.
5. Bloxham G, Long CG, Alderman N, Hollin CR. The behavioral treatment of self-starvation and severe self-injury in a patient with borderline personality disorder. *Journal of Behavioral Therapy and Experimental Psychiatry* 1993; 24:261–267.

Note

Last year we published a letter ‘Neuroleptic rechallenge following neuroleptic malignant syndrome’ by Raju GVL, Ramesh Kumar TC and Khanna S (p.700). Our apologies to the authors of this letter for the incorrect presentation of their names.