

Susac's Syndrome: Beneficial Effects of Corticosteroid Therapy in a Japanese Case

Kazuhiro TASHIMA, Eiichiro UYAMA, Yoichiro HASHIMOTO*, Toshiro YONEHARA** and Makoto UCHINO

Abstract

Susac's syndrome is a rare disorder characterized by the triad of microangiopathy of the brain and retina with hearing loss. More than 50 affected individuals have been reported worldwide, all Caucasians. We herein identify the first Japanese patient with Susac's syndrome. A 36-year-old man developed recurrent subacute encephalopathy, bilateral sensorineural hearing loss, and retinal arteriolar occlusions, caused by microangiopathy from a year previously. T2-weighted MRI showed multiple high-signal lesions predominantly in the periventricular white matter. During the exacerbated phase both high-dose intravenous methylprednisolone and oral prednisone therapy produced beneficial effects. He showed definite remission within 2 years from the disease onset.

(Internal Medicine 40: 135–139, 2001)

Key words: microangiopathy, subacute encephalopathy, retinal anterior occlusion, sensorineural hearing loss

Introduction

Susac's syndrome is a rare sporadic disorder characterized by the triad of microangiopathy of the brain and retina with hearing loss (1, 2). The syndrome predominantly occurs in young women, with the neurologic features frequently leading to a misdiagnosis, such as multiple sclerosis or collagen vascular diseases, or it is initially managed as a psychiatric disorder (1, 2). Neither a neuropathologic hallmark such as a disease-specific inclusion, nor a serologic marker has been identified. The pathogenesis of the syndrome and the reason for the female predominancy are unknown. Patients tend to improve spontaneously with definite remission within 2 years, thus the efficacy of treatment also remains obscure. So far, at least 50 cases have been reported from communities around the world (1–19), all were Caucasians.

We describe the first Japanese patient with Susac's syndrome. The patient showed beneficial responses to high-dose intravenous methylprednisolone and oral prednisone therapy.

Case Report

A 36-year-old Japanese man with a history of bronchial asthma, noted a partial defect in his visual field, followed by a non-throbbing headache, nausea, and slight fever. Two weeks later, he developed personality changes, his intellectual faculties declined, and he experienced episodic confusion. He was admitted to Hospital A, where the results of serologic studies, ECG, brain CT, and EEG were all normal. Soon thereafter, symptoms such as a numbness in the left hand, and difficulties in speaking and walking developed. Immediately thereafter, he was transferred to Hospital B. A cerebrospinal fluid sample showed 3 lymphocytes/ μ l under normal pressure, a protein level of 288 mg/dl, and IgG level of 16.4 mg/dl (5.7%). Neither myelin basic protein nor the oligoclonal IgG band were positive. On T2-weighted MRI (1.5 tesla, TR: 2,300, TE: 90), there were multiple high-intensity lesions in the internal capsules, bilateral basal ganglia (Fig. 1A), and periventricular white matter (Fig. 1B). These lesions showed nearly iso-intensity on T1-weighted MRI (TR: 600, TE: 15). Several lesions were slightly enhanced with Gd-DTPA and a tentative diagnosis of multiple sclerosis was made. Treatment with intravenous methylprednisolone (1 g/day for 3 days) was instituted, followed by oral prednisone (60 mg/day) with standard tapering. Over the subsequent 3 weeks, his consciousness level and motor functions gradually recovered. However, 3 weeks later, he complained of hearing disturbances in both ears, and visual disturbances in the left eye. He was then admitted to Hospital C, where ophthalmoscopic examination disclosed bilateral narrowing of retinal arteries and multiple segmented branch artery occlusions with retinal microinfarcts (Fig. 2). Six months later, he had a relapse consisting of headache, nausea, time and place disorientation, and behavioral changes. High-dose (1 g) intravenous methylprednisolone was administered for 1 day, followed by oral prednisone (60 mg/day). Soon thereafter, he

From the Department of Neurology, Kumamoto University School of Medicine, *the Department of Neurology, Kumamoto City Hospital and **the Department of Neurology, Cerebrovascular Center, Saiseikai Kumamoto Hospital, Kumamoto

Received for publication May 11, 2000; Accepted for publication August 2, 2000

Reprint requests should be addressed to Dr. Eiichiro Uyama, the Department of Neurology, Kumamoto University School of Medicine, 1-1-1 Honjo, Kumamoto 860-0811

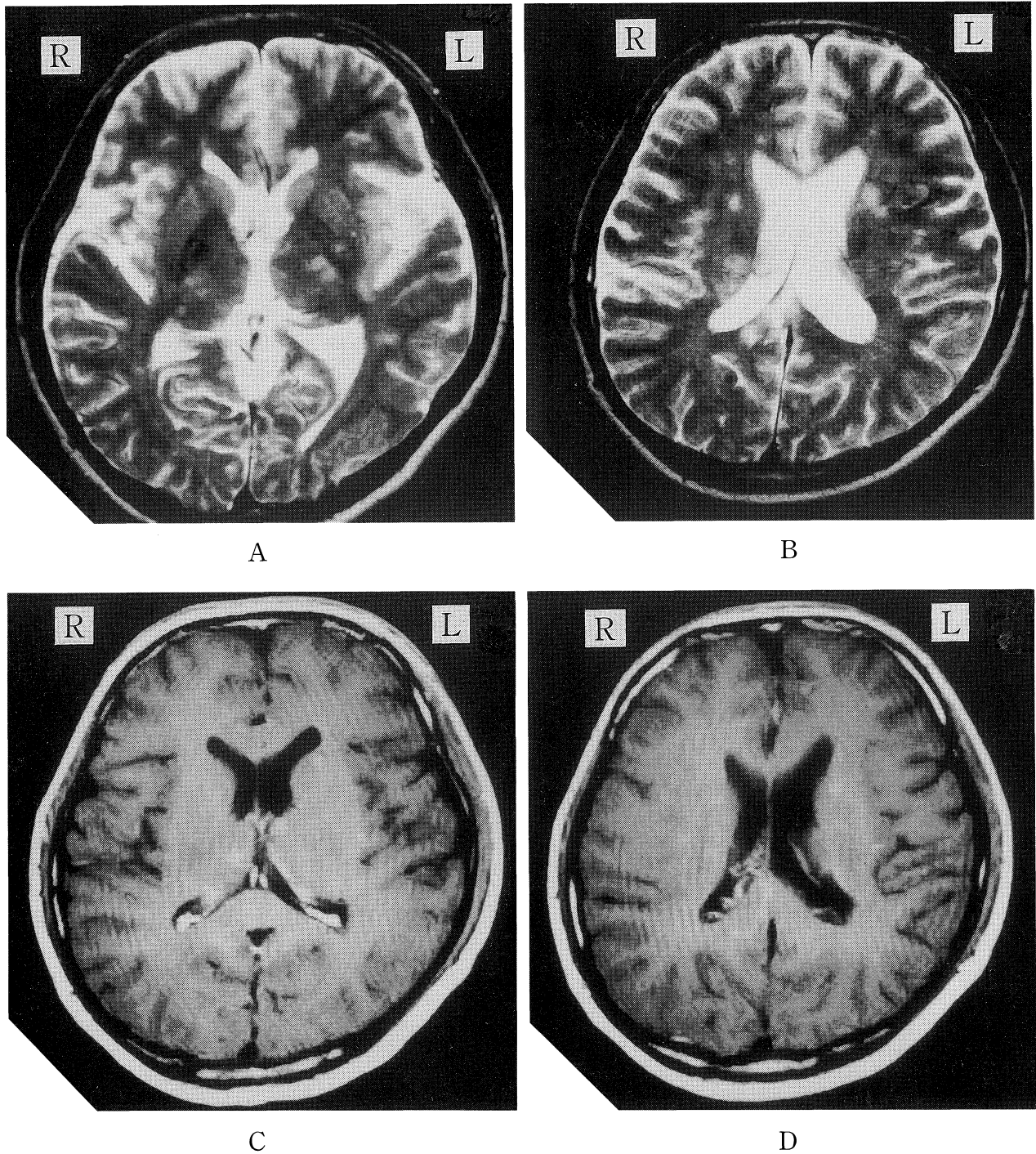


Figure 1. Cranial MRI (1.5 tesla) before corticosteroid treatment. T2-weighted images (TR: 2,300, TE: 90) show multiple high-intensity lesions in the internal capsules, the basal ganglia (A) and periventricular white matter (B). These lesions were shown as iso-intensity on enhanced T1-weighted images (TR: 600, TE: 15) (C, D) and several lesions were enhanced.

showed daily improvement, but the condition was exacerbated again 2 weeks later when oral prednisone was tapered to 20 mg/day. He was then transferred to our hospital.

On admission, physical examination was normal except for scattered livedo reticularis of the skin. Neurologically, he was

alert but disoriented. Recent and remote memories were impaired. Visual acuity was 12/200 (corrected to 30/20) on the right side and 2/200 (uncorrected) on the left. There was bilateral sensorineural deafness, increased tendon reflexes and an ataxic gait. Laboratory studies including C-reactive protein,

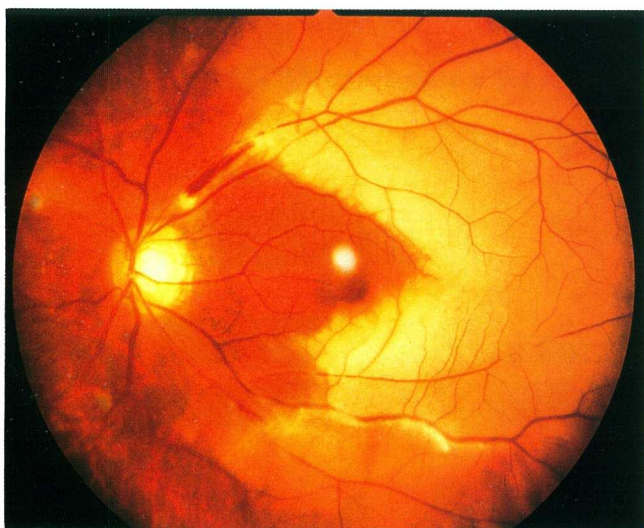


Figure 2. Fundus photograph of the left eye shows multiple branch retinal arterial occlusions and ischemic retinal edema in the temporal side. Ratio of diameter; artery : vein=1 : 2–3, normal, 2 : 3.

antinuclear antibody, lupus anticardiolipin antibody, rheumatoid factor, tests for coagulopathy, syphilis, AIDS, and endocrine diseases were all negative. On T2-weighted MRI (TR: 2,200, TE: 90), there were multiple high-intensity lesions similar to that obtained in Hospital B (Fig. 1), but the size and number of lesions had decreased. An MR angiography and ultrasonographic evaluation for intra- and extra-cerebral vessels showed no abnormal findings. We did not perform four-vessel angiography due to an allergy to iodine solutions. Pure-tone audiometry showed bilateral asymmetric sensorineural hearing loss ranging from 30 dB to 80 dB, predominantly in low to moderate frequency tones (Fig. 3). A recruitment test of short increment sensitivity index was positive. Bekesy audiometry revealed type II pattern on Jerger's classification, indicating cochlear dysfunction. These results and the clinical characteristics led us to a diagnosis of Susac's syndrome. In a therapeutic trial, we increased the dose of oral prednisone to 60 mg/day for 2 weeks. Apparent improvement was observed in his higher brain functions such as acalcuria, dressing apraxia for neck tie, and anterograde amnesia, from the second day of this trial. Oral prednisone therapy was maintained in a range between 40 mg and 30 mg per day together with diltiazem (200 mg/day) and ticlopidine (300 mg/day). Over several months, he apparently recovered. A summary of the clinical course and the effects of treatment are shown in Fig. 4. Although some visual deficit, hearing loss, and a slight dullness of mentality remained, he was able to return to an almost normal lifestyle 2 years after the onset of the disease, and had no relapses in the following 2 years under a regime of 10 mg per every other day of oral prednisone together with diltiazem (200 mg/day) and ticlopidine (300 mg/day).

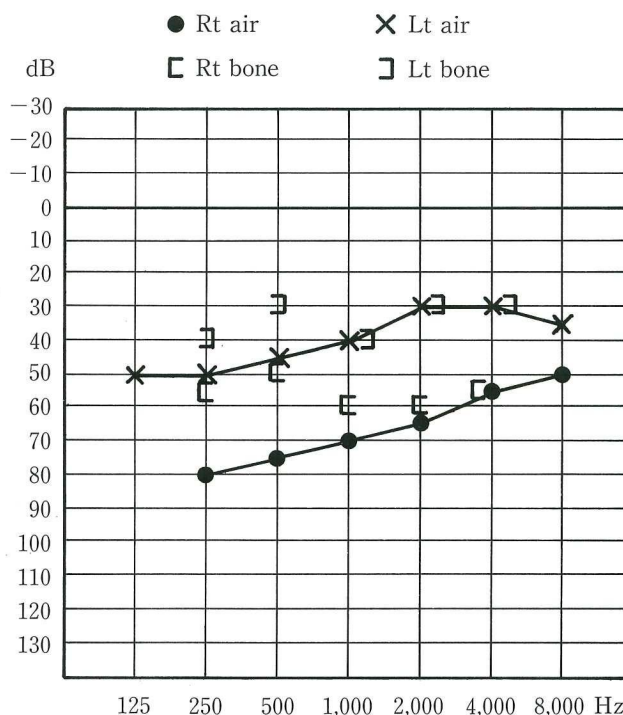


Figure 3. Pure-tone audiometry shows bilateral asymmetric sensorineural hearing loss predominantly in low to moderate frequency tones.

Discussion

In the present case, the diagnosis of Susac's syndrome was made on the basis of its characteristic triad, MRI findings, negative reference data for other disorders, and a definite remission within 2 years. From an epidemiological aspect, this syndrome is a very rare disorder (1), with all previously reported cases being Caucasians (1–19). A recent review (16), however, indicates that this syndrome is more common than previously thought. To our knowledge, the present patient is the first confirmed Japanese case of Susac's syndrome. Internationally, diagnostic criteria have not been established, however characteristic signs consisting of subacute encephalopathy, sensorineural hearing loss, and retinal arteriolar occlusions caused by microangiopathy can lead to the diagnosis. As shown in the present case, the disease is often initially confused with multiple sclerosis due to the similarity of MRI patterns and the presence of exacerbations (2, 14, 16). Hearing loss is usually bilateral and rather prominent in the low to moderate frequency tones, as was shown in the present case. The impairment might be due to microinfarction of the apical turn of the cochlea. Branch retinal artery occlusions are also invariably bilateral. These may impair the vision when they involve the posterior pole but may be asymptomatic if the occlusions occur in the more peripheral portion of the retina. In the present case, visual loss worsened 18 weeks after onset and was persistently

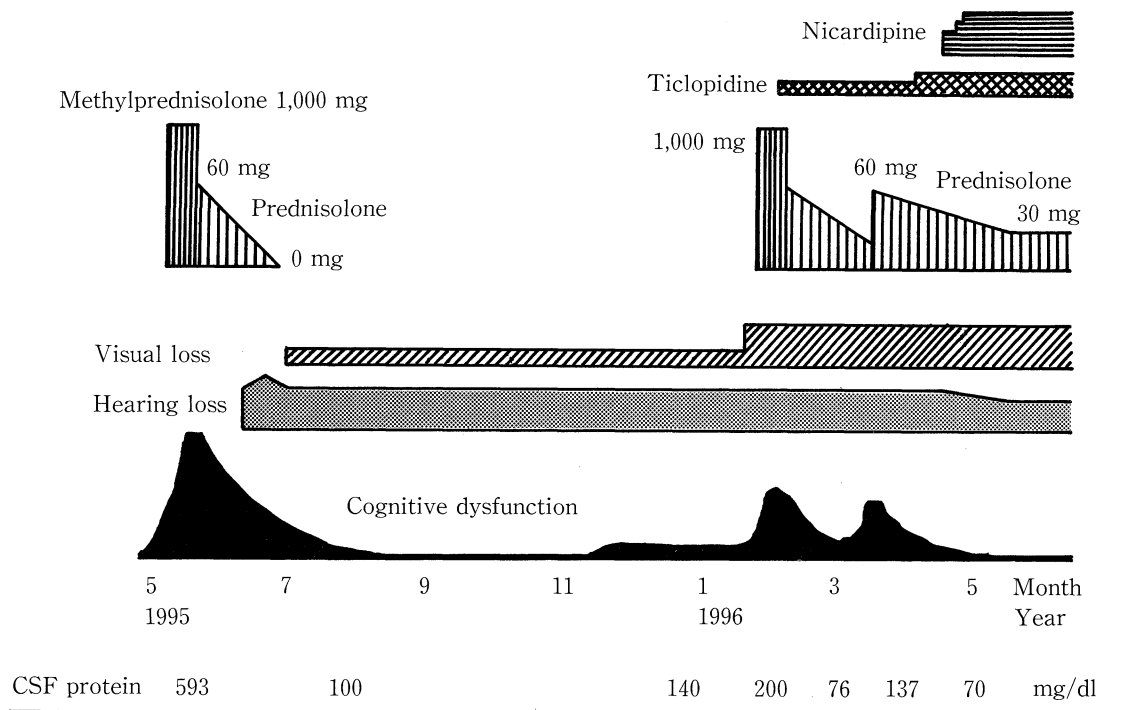


Figure 4. Clinical course. High-dose intravenous methylprednisolone was effective, especially for cognitive dysfunction.

present. Varying degrees of headache and of the migraine type, or a non-throbbing nature, are recognized as prodromal symptoms. Ten previous brain biopsies (2, 5, 15) showed findings of microinfarctions, or perivascular inflammatory infiltrates of small vessels mimicking active small vessel angitis without fibrinoid necrosis. In addition to histopathologic characteristics, the presence of steroid responsive multiple lesions with enhancement on MRI share a similar pattern to that of isolated central nervous system angiopathy (20). However, none of the biopsied tissues revealed granulomatous or necrotising inflammation. Further studies are necessary to clarify the pathogenesis of retinocochleocerebral vasculopathy in this syndrome.

The syndrome has the nature of a self-limiting course, although therapeutic trials are usually required to prevent exacerbation, and for the purpose of avoiding complicating permanent deficits. To date, hyperbaric oxygen (12, 19), dextran (9), plasmapheresis (10, 11), high-doses of intravenous immunoglobulin (10), or various kinds of drugs such as corticosteroid (1, 3, 6, 7, 11, 15, 19), cyclophosphamide (3, 7, 10, 11), warfarin (8), aspirin (8, 9, 13), and nimodipine (13) have been used in treatment. Our review of the literature indicates that early treatment with corticosteroids seems to be the most useful to prevent the progression of the disease. If the patient fails to respond, cyclophosphamide should be tried as an adjunctive agent. Other treatments seem to be less effective. Susac has previously recommended high-dose intravenous methylprednisolone therapy as the second choice, after a first trial with aspirin and nimodipine is ineffective (2). Oral prednisone therapy alone failed to prevent disease progression in several cases (2–4).

Recently, O'Halloran et al, including Susac, recommended intravenous methylprednisone 1 g/day for 3 days followed by prednisone at 80 mg/day with gradual tapering, as the first choice (15). The mechanism of the effect remains obscure, however, we believe that high-dose corticosteroid may immunologically suppress small vessel angitis. Corroboratory results in the present case also indicate the beneficial effects of corticosteroid therapy in patients with exacerbated phases of Susac's syndrome, which can now be seen as a geographically widespread disorder.

Clinical features of the present case were reported at the 135th Regional Meeting In Kyushu of the Japanese Society of Neurology, September 28, 1996, Kagoshima.

References

- 1) Susac JO, Hardman JM, Selhorst JB. Microangiopathy of the brain and retina. *Neurology* **29**: 313–316, 1979.
- 2) Susac JO. Susac's syndrome: the triad of microangiopathy of the brain and retina with hearing loss in young women. *Neurology* **44**: 591–593, 1994.
- 3) Monteiro MLR, Swanson RA, Coppeto JR, Cuneo RA, DeArmond SJ, Prusiner SB. A microangiopathic syndrome of encephalopathy, hearing loss, and retinal arteriolar occlusions. *Neurology* **35**: 1113–1121, 1985.
- 4) MacFadyen DJ, Schneider RJ, Chisholm IA. A syndrome of brain, inner ear and retinal microangiopathy. *Can J Neurol Sci* **14**: 315–318, 1987.
- 5) Heiskala H, Somer H, Kovanen J, Poutiainen E, Karli H, Haltia M. Microangiopathy with encephalopathy, hearing loss and retinal arteriolar occlusions: two new cases. *J Neurol Sci* **86**: 239–250, 1988.
- 6) Bogousslavsky J, Gaio JM, Caplan LR, et al. Encephalopathy, deafness

Susac's Syndrome

- and blindness in young women: a distinct retinocochleocerebral arteriopathy? *J Neurol Neurosurg Psychiatry* **52**: 43–46, 1989 (see comments).
- 7) Kaminska EA, Sadler M, Sangalang V, Hoskinmott A, Silverberg D. Microangiopathic syndrome of encephalopathy, retinal vessel occlusion and hearing loss. *Can J Neurol Sci* **17**: 241, 1990 (Abstract).
 - 8) Gordon DL, Hayreh SS, Adams HP Jr. Microangiopathy of the brain, retina, and ear: improvement without immunosuppressive therapy. *Stroke* **22**: 933–937, 1991.
 - 9) Schwitter J, Agosti R, Ott P, Kalman A, Waespe W. Small infarctions of cochlear, retinal, and encephalic tissue in young women. *Stroke* **23**: 903–907, 1992.
 - 10) Vila N, Graus F, Blesa R, Santamaria J, Ribalta T, Tolosa E. Microangiopathy of the brain and retina (Susac's syndrome): two patients with atypical features. *Neurology* **45**: 1225–1226, 1995.
 - 11) Ballard E, Butzer JF, Donders J. Susac's syndrome: neuropsychological characteristics in a young man. *Neurology* **47**: 266–268, 1996.
 - 12) Li HK, Dejean BJ, Tang RA. Reversal of visual loss with hyperbaric oxygen treatment in a patient with Susac syndrome. *Ophthalmology* **103**: 2091–2098, 1996.
 - 13) Wildemann B, Schulin C, Storch-Hagenlocher B, et al. Susac's syndrome: improvement with combined antiplatelet and calcium antagonist therapy. *Stroke* **27**: 149–151, 1996 (letter).
 - 14) Bateman ND, Johnson IJ, Gibbin KP. Susac's syndrome: a rare cause of fluctuating sensorineural hearing loss. *J Laryngol Otol* **111**: 1072–1074, 1997.
 - 15) O'Halloran HS, Pearson PA, Lee WB, Susac JO, Berger JR. Microangiopathy of the brain, retina, and cochlea (Susac syndrome). *Ophthalmology* **105**: 1038–1044, 1998.
 - 16) Papo T, Biousse V, Lehoang P, et al. Susac syndrome. *Medicine (Baltimore)* **77**: 3–11, 1998.
 - 17) Barker RA, Anderson JR, Meyer P, Dick DJ, Scolding NJ. Microangiopathy of the brain and retina with hearing loss in a 50 year old woman: extending the spectrum of Susac's syndrome. *J Neurol Neurosurg Psychiatry* **66**: 641–643, 1999.
 - 18) Sahin O, Goldstein DA, Tessler HH. Findings typical of Susac's syndrome in a patient with scleroderma. *Retina* **19**: 476–477, 1999.
 - 19) Meca-Lallana JE, Martin JJ, Lucas C, et al. Susac syndrome: clinical and diagnostic approach: a new case report. *Rev Neurol* **29**: 1027–1032, 1999 (In Spanish, Abstract in English).
 - 20) Ehsan T, Hasan S, Powers JM, Heiserman JE. Serial magnetic resonance imaging in isolated angitis of the central nervous system. *Neurology* **45**: 1462–1465, 1995.
-