

channel blockers, thromboxan A2 antagonists, free radical scavengers, intrathecal thrombolytic therapy, etc. Endovascular treatment including transluminal angioplasty and superselective intra-arterial injection of the vasodilator papaverine has also been used. On the other hand, management of vasospasm after tumour surgery has not been discussed in detail. Only hypertensive-hypervolaemic haemodilution therapy has been reported as effective in some cases.^{1,2,5,7} In the present case, combination of treatments with intraarterial injection of papaverine, hypertensive-hypervolaemic haemodilution and thromboxan A2 antagonists resulted in an excellent recovery from the ischaemic condition. We suggest that when secondary SAH is the probable cause of the vasospasm and complete haemostasis can be confirmed, treatments identical to those for vasospasm following aneurysmal SAH should be initiated promptly and aggressively.

Transsphenoidal surgery has become the preferred approach for most pituitary adenomas. Although effectiveness and safety have been well documented and the mortality rate is extremely low, there are many reports about the complication.¹² Cerebrospinal fluid leakage, diabetes insipidus and paranasal sinusitis are the major complications, whereas cerebrovascular complications are uncommon. The four cases,²⁻⁴ including ours, of pituitary adenomas with vasospasm after the transsphenoidal removal were aged from 30 to 50 years, and had three large and one enclosed adenomas. Two cases had associated cerebrospinal fluid rhinorrhoea prior to the onset of symptomatic vasospasm. Two cases died and one lost visual function; the present case was the first to show significant recovery without any neurological deficits. In conclusion, vasospasm may occur in pituitary adenomas after transsphenoidal surgery, though rarely, with a mechanism resembling those following

aneurysmal SAH. If signs or symptoms develop, active and prompt treatments are necessary to prevent serious ischaemic sequelae.

References

- 1 Aoki N, Oigitano TC, Al-Mefty O. Vasospasm after resection of skull base tumors. *Acta Neurochir (Wien)* 1995;132:53-8.
- 2 Barrow DL, Tindall GT. Loss of vision after transsphenoidal surgery. *Neurosurgery* 1990;27:60-8.
- 3 Camp PE, Paxton HD, Buchan GC, Gahbauer H. Vasospasm after trans-sphenoidal hypophysectomy. *Neurosurgery* 1980;7:382-6.
- 4 Hyde-Rowan MD, Roessmann U, Brodkey JS. Vasospasm following transsphenoidal tumor removal associated with the arterial changes of oral contraception. *Surg Neurol* 1983;20:120-4.
- 5 LeRoux PD, Haglund MH, Mayberg MR, Winn HR. Symptomatic cerebral vasospasm following tumor resection: report of two cases. *Surg Neurol* 1991;36:25-31.
- 6 Mawk JR, Ausman JL, Erickson DL, Maxwell RE. Vasospasm following transcranial removal of large pituitary adenomas. Report of three cases. *J Neurosurg* 1979;50:229-32.
- 7 Bejjani GK, Sekhar LN, Yost A-M, Bank WO, Wright DC. Vasospasm after cranial base tumor resection: pathogenesis, diagnosis, and therapy. *Surg Neurol* 1999;52:577-84.
- 8 Wilkins RH. Hypothalamic dysfunction and intracranial arterial spasms. *Surg Neurol* 1975;4:472-80.
- 9 Cardoso ER, Peterson EW. Pituitary apoplexy and vasospasm. *Surg Neurol* 1983;20:391-5.
- 10 Itoyama Y, Goto S, Miura M, Kuratsu J, Ushio Y, Matsumoto T. Intracranial arterial vasospasm associated with pituitary apoplexy after head trauma — case report. *Neurol Med Chir (Tokyo)* 1990;30:350-3.
- 11 Sanno N, Ishii Y, Sugiyama M, Takagi R, Node Y, Teramoto A. Subarachnoid hemorrhage and vasospasm due to pituitary apoplexy after pituitary function test. *Acta Neurochir (Wien)* 1999;141:1009-10.
- 12 Black PMcL, Zervas NT, Candia GL. Incidence and management of complications of transsphenoidal operation for pituitary adenomas. *Neurosurgery* 1987;20:920-4.

Cerebellar mutism caused by arteriovenous malformation of the vermis

A. AL-ANAZI, M. HASSOUNAH¹, B. SHEIKH & S. BARAYAN

Department of Neurosurgery King Fahad Hospital of the University, Al-Khobar, and ¹Department of Neurosurgery King Faisal Specialist Hospital and Research Center, Riyadh, Saudi Arabia

Correspondence: A. Al-Anazi, King Fahad Hospital of the University, PO Box 40010, Al-Khobar 31952, Saudi Arabia. E-mail: alanazi@hotmail.com

Received for publication 6 March 2000. Accepted 1 August 2000.

Abstract

Transient mutism following posterior fossa tumour resection in children is well known in the literature. To our knowledge, this phenomenon has never been reported without surgical intervention. We report a case of cerebellar mutism secondary haemorrhage from a vermian arteriovenous malformation (AVM), which resolved to ataxic dysarthria after 6 weeks. Embolization of the AVM was performed and the patient's clinical status continued to improve gradually till she became normal 6 months from the insult. The mutism was due to rupture of the AVM which might correlate the cerebellar mutism with the transient vasospasm of the blood vessels supplying the cerebellum. It is possible for a spontaneous posterior fossa bleed to result in transient mutism similar to post surgical mutism.

Key words: Arteriovenous malformation, haemorrhage, mutism, vermis.

Introduction

Mutism is the condition of complete absence of speech of a cognitively alert patient without evidence of apraxia to reduce verbal output.¹ The cerebellum has been associated with a wide range of speech dysarthrias. These dysarthrias range from a monotonous, scanning speech to explosive, hesitant outbursts of speech.² Reigate *et al.*³ and Yomemasu⁴ first reported mutism after posterior cranial fossa surgery in 1985. We present a case of cerebellar mutism due to cerebellar AVM haemorrhage.

Case report

A 14-year-old newly-married female woke up early one morning with an attack of acute severe headache followed by loss of consciousness. She was taken to a local hospital where urgent CT of the brain showed a large cerebellar haemorrhage (Fig. 1). The patient was admitted to the Intensive Care Unit, intubated and treated conservatively.

Her condition improved slowly and 5 days later she was transferred to King Fiasal Specialist Hospital and Research Centre for further evaluation and management. The patient was extubated and breathing spontaneously; she was mute, but obeyed commands very well. She moved her four limbs equally well and had brisk reflexes with up-going planter reflexes bilaterally. Repeat CT showed resorption of the haematoma and no hydro-

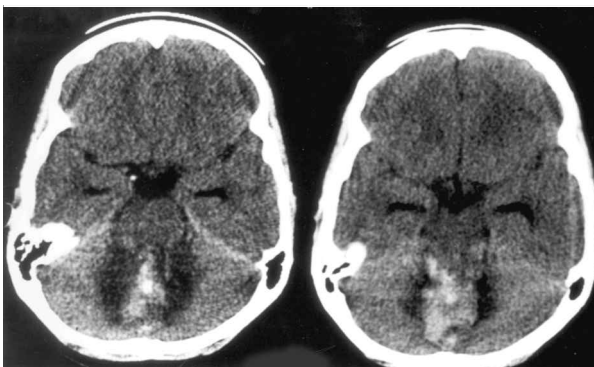


FIG. 1. Enhanced CT scan of the posterior fossa showed high attenuation area due to cerebellar haemorrhage surrounded by low attenuation due to brain oedema. Prominent temporal horns, which indicates mild hydrocephalus.

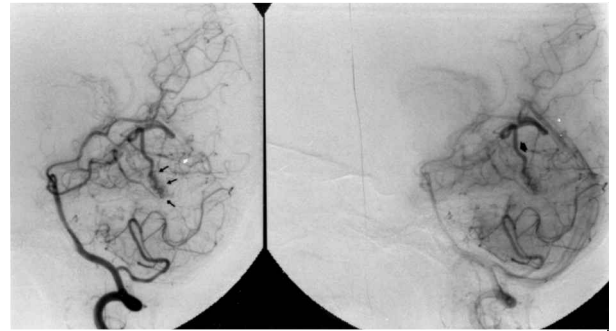


FIG. 2. Vertebral angiogram showed an AVM fed by the right superior cerebellar artery.

cephalus. A four-vessel cerebral angiogram was done which showed a vermian AVM supplied by the right superior cerebellar artery (Figs 2 and 3). The patient's condition continued to improve and 5 weeks after the insult she started saying a few words, which progressed to understandable ataxic speech. She had a good gag reflex and was able to swallow without difficulty. She started to walk with assistance and this progressed to a mildly ataxic gait. Six weeks after the insult, the options of

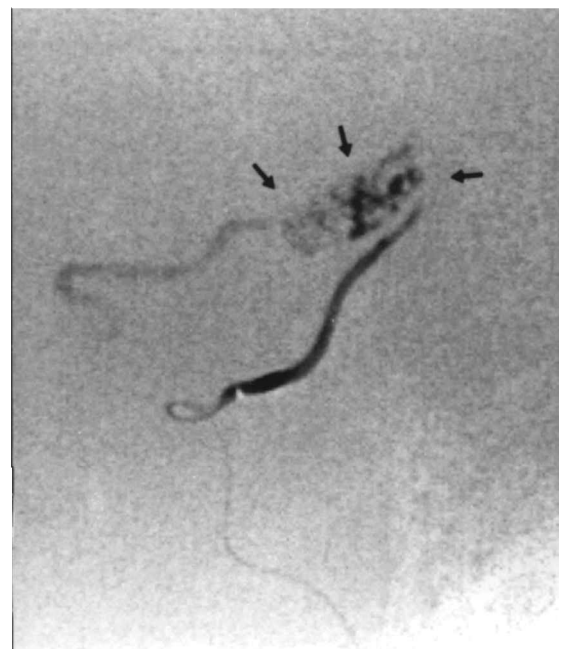


FIG. 3. Super selection of the feeding vessel demonstrating the nidus of the AVM and the draining vein.

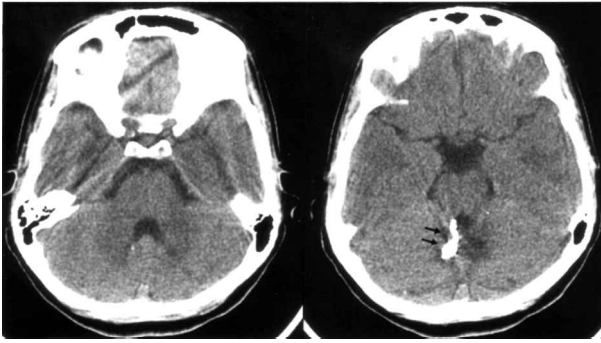


FIG. 4. Postendovascular embolization posterior fossa CT scan showed the glue (NBC) obliterating the AVM.

surgical excision and embolization of the AVM were explained to the patient and her relatives, who preferred embolization. This procedure was later proved to have been successful by follow-up CT and angiogram (Figs 4 and 5). The patients' clinical status continued to improve gradually and she had returned normal clinical status 6 months from the insult.

Discussion

A review of the literature disclosed approximately 78 cases of transient cerebellar mutism after surgical removal of a posterior fossa tumour.^{3,5-24} Dietze & Mickle¹ reported a case of transient mutism after surgical treatment of a vermian AVM in a patient who presented with an acute posterior fossa bleed and acute obstructive hydrocephalus, but because the patient was too sick they could not comment on the patient's ability to speak. Evacuation of the haematoma was performed urgently, as well as a ventriculostomy, which was later converted to a ventriculoperitoneal shunt. A cerebral angiogram showed a superior vermian AVM fed principally by the left superior cerebellar and the right posterior inferior cerebellar arteries, and minimally by the right superior cerebellar artery. A complete resection of the AVM was performed. Three months postoperatively the patient was able to produce sounds, but had a monotonous, slightly laboured and bradykinetic dysarthria. To the best of our knowledge, ours

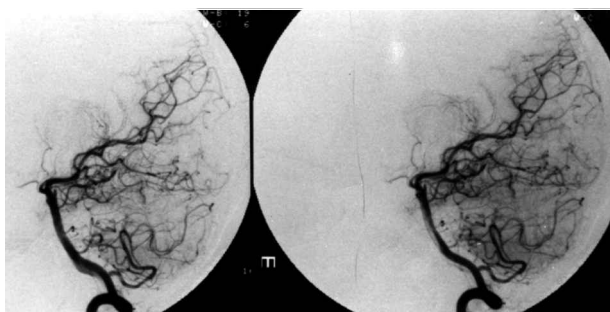


FIG. 5. Postembolization lateral vertebral angiogram showed total obliteration of the AVM in the posterior fossa.

is the second case of transient cerebellar mutism due to rupture of vermian AVM. The association between cerebellar lesion and defects in speech production has long been recognized and reported with a multitude of cerebellar diseases. In 1823 Flourens²⁵ described the tremor, staggering gait and slurred speech accompanying cerebellar disease. In 1917, Holmes²⁶ reported that speech associated with a gunshot wound to the cerebellum was slow, drawling and monotonous with an unnatural separation of the syllables and a jerky, often explosive articulation. He concluded that speech production was more seriously affected when vermis and mesial hemispheres of the lateral lobes of the cerebellum were injured.

Mid-line cerebellar cortical structures have complex nuclear cortical and cortical nuclear projections that link the paravermis and the vermis with the cerebellar nuclei.²⁷ These nuclei, the ventral lateral thalamus, and subsequently motor and sensory association areas such as the supplementary motor area have been proved to be necessary for the initiation of speech.²⁸ The paravermian region uses sensory information from spinocerebellar and cuneocerebellar tracts to compare learned motor programmes with intended cerebral output, and adjust final motor output accordingly.^{29,30} If the cerebellar lesions receiving sensory input from the oral pharynx were damaged, either directly or through postoperative oedema, the motor output (speech and swallowing) could be affected adversely. Van Mourik *et al.*²³ observed marked discrepancy between voluntary and involuntary, both simple and complex orofacial movements, in mute patients after posterior fossa surgery. Crutchfield *et al.*¹⁰ reported mutism after medulloblastoma excision in a child with apparent injury to the dentate nucleus and mutism in an adult after parasagittal meningioma removal with apparent damage to the supplementary premotor area. They conclude that the only pathway connecting these two loci is the dentothalamocortical loop, which they suggest as the basis for the mutism.

Ditze & Mickle¹ concluded that acute injury to the mid-portion of the cerebellum with or without dentate nuclear involvement may be responsible for speech disorders and that the injury to the mid-portion of the cerebellum with dentate nuclear involvement increases the risk of developing postoperative mutism. Ferrante *et al.*¹⁵ and Nagatoni *et al.*¹⁹ have hypothesized that postoperative spasm of the arteries supplying the cerebellum may cause ischaemia and disturbed cerebellar perfusion, or oedema may lead to mutism. Cotsman-Berrevoets *et al.*⁹ reported that the lack of speech may be explained by the transient dysfunction of neurons of the A9 to A10 dopaminergic cell group in the mesencephalon and that those neurons play a major role in the mesencephalofrontal activating system.

On the other hand e.g. Ersahin *et al.*¹⁴ gave their patient who had mutism secondary to brain stem surgery a bromocriptine (dopa agonist), but the patient did not respond.

Clinically cerebellar mutism mostly associated with an abnormal state of consciousness in the absence of long tract signs and supranuclear or nuclear cranial nerve palsies;^{1,5,6,8,31,32} Dunwoody¹² reported a case of cerebellar mutism in association with long tract sign after posterior fossa surgery, but the EEG showed widespread abnormality in the left cerebral hemisphere. Three of Ferrante *et al.*'s patients¹⁵ and one of Humphreys' patients³³ began to recover from their mute state once they gone home, and hence proposed psychological factors as a cause of mutism.

In conclusion, we have reported a second unusual case of cerebellar mutism due to vermian AVM. There was no surgical intervention and the mutism was due to rupture of the AVM, which might correlate the cerebellar mutism with the transient vasospasm of the blood vessels supplying the cerebellum.

Acknowledgements

We thank Dr M. C. Wallace, Department of Neurosurgery, Toronto Western Hospital, Toronto University, for his useful comments and advices on the manuscript.

References

- 1 Dietze DD, Mickle JP. Cerebellar mutism after posterior fossa surgery. *Pediatric Neurosurg* 1990;16:25-31.
- 2 Kent R, Netsell R. A case of an ataxic dysarthria: cine-radiographic and spectrographic observations. *J Speech Hear Disord* 1979;41:115-34.
- 3 Rekatte HL, Grubb RL, Aram DM, Hahn JF, Ratcheson RA. Muteness of cerebellar origin. *Arch Neurol* 1985;42:697-8.
- 4 Yonemasu Y. Cerebellar mutism and speech disturbance as a complication of posterior fossa surgery in children. *13th Annual Meeting of the Japanese Society for Pediatric Neurosurgery*, Tsukuba, Japan, 1985
- 5 Aguiar PH, Plese JP, Ciquini O, Marino R. Transient mutism following a posterior fossa approach to cerebellar tumors in children: a critical review of the literature. *Childs Nerv Syst* 1995;11:306-10.
- 6 Al-Jarallah A, Cook JD, Gascon G, Kanaan I, Sigueira E. Transient mutism Following posterior fossa surgery in children. *J Sur Oncol* 1994;55:126-31.
- 7 Ammirati M, Mirzai S, Samii M. Transient mutism following removal of a cerebellar tumor. *Childs Nerv Syst* 1989;5:614-17.
- 8 Asamoto M, Ito H, Suzuki N, Oiwa Y, Saito K, Haraoka J. Transient mutism after posterior fossa surgery. *Childs Nerv Syst* 1994;10:275-8.
- 9 Catsman-Berrevoets CE, Van Dongen HR, Zwetsloot CP. Transient loss of speech followed by dysarthria after removal of posterior fossa tumor. *Dev Med Child Neurol* 1992;34:1102-9.

- 10 Crutchfield JS, Sawaya R, Meyers CA, Moore BD. Postoperative mutism neurosurgery: report of two cases. *J Neurosurg* 1994;81:115-21.
- 11 Dailey AT, Mc Khann II, Berger MS. The pathophysiology of oral pharyngeal apraxia and mutism following posterior fossa tumor resection in children. *J Neurosurg* 1995;83:467-75.
- 12 Dunwoody GW, Alsagoff ZS, Yuan SY. Cerebellar mutism with subsequent dysarthria in an adult: case report. *Br J Neurosurg* 1997;1:161-3.
- 13 Ersahin Y, Mutluer S, Cagli S, Duman Y. Cerebellar mutism: report of seven cases and review of the literature. *Neurosurgery* 1996;38(1):60-6.
- 14 Ersahin Y, Mutluer S, Saydam S, Barcin E. Cerebellar mutism: report of two unusual cases and review of the literature. *Clin Neurol Neurosurg* 1997;99:130-4.
- 15 Ferrante L, Mastronadi L, Acqui M, Fortuna A. Mutism after posterior fossa surgery in children: report of three cases. *J Neurosurgery* 1990;72:959-63.
- 16 Herb E, Thyen U. Mutism after cerebellar medulloblastoma surgery. *Neuropediatrics* 1992;23:144-6.
- 17 Kai Y, Kuratsu J, Suginoara K, Marubayashi T, Ushio Y. Cerebellar mutism after posterior fossa surgery: two case reports. *Neurol Med Chir* 1997;37:929-33.
- 18 Kingma A, Mooij JJ, Metzemaekers JD, Leeuw JA. Transient mutism and speech disorders after posterior fossa surgery in children with brain tumors. *Acta Neurochir (Wien)* 1994;131:74-9.
- 19 Nagatani K, Waga S, Nakagawa Y. Mutism after removal of a vermian medulloblastoma: cerebellar mutism. *Surg Neurol* 1991;36:307-9.
- 20 Pollack IF, Polinko P, Leland A, Towbin R, Fitz C. Mutism and pseudobulbar symptoms after the resection of posterior fossa tumors in children: incidence and pathophysiology. *Neurosurgery* 1995;37:885-93.
- 21 van Calenbergh F, van de Laar A, Plets C, Goffin J, Casaer P. Transient cerebellar mutism after posterior fossa surgery in children. *Neurosurgery* 1995;37:894-8.
- 22 van Dongen HR, Catsman-Berrevoets CE, van Mourik M. The syndrome of cerebellar' mutism and subsequent dysarthria. *Neurology* 1994;44:2040-6.
- 23 van Mourik M, Catsman-Berrevoets CE, van Dongen HR, Neville BG. Complex orofacial movements and the disappearance of cerebellar mutism: report of five cases. *Dev Med Child Neurol* 1997;39:686-90.
- 24 Valcan I, Cole GP, Johnston K. A case of muteness of cerebellar origin. *Arch Neurol* 1986;43:313-15.
- 25 Flourens MJP. *Histoire de la decouverte de la circulation du sang*. Paris: Garnier Freres, 1857
- 26 Holmes G. The symptoms of acute cerebellar injuries due to gun-shot injuries. *Brain* 1917;40:461-535.
- 27 Tolbert DL, Bantli H, Bloedel JR. Organization features of the cat and monkey cerebellar nucleocortical projections. *J Comp Neurol* 1978;182:39-56.
- 28 Carpenter MB. *Core test of neuroanatomy*, 4th edn. Baltimore: Williams & Wilkins, 1991.
- 29 Lalonde R, Boeta MI. The cerebellum and learning processes in animals. *Brain Rev* 1990;15:325-32.
- 30 Leiner HC, Leiner AL, Dow RS. Reappraising the cerebellum: what does the hindbrain contribute to the forebrain? *Behav Neurosci* 1989;103:98-1008.
- 31 Cakir Y, Karakisi D, Kocanaogullari O. Cerebellar mutism in an adult: case report. *Surg Neurol* 1994;41:342-4.
- 32 Gaskill SJ, Marlin AE. Transient eye closure after posterior fossa tumor surgery in children. *Pediatr Neurosurg* 1991-92;17:196-8.
- 33 Humphreys RP. Mutism after posterior fossa tumor surgery. In: Marlin AE, ed. *Concepts in pediatric neurosurgery* vol. 9, Basel: Karger, 1989;57-64.