

Eur Neurol 2001;45:182–183

Hemiballism-Hemichorea and Posterior Communicating Artery StenosisJong S. Kim^a, Dae C. Suh^bDepartments of ^aNeurology and ^bNeuroradiology, University of Ulsan, Asan Medical Center, Seoul, Korea

Although recent studies emphasized a striatal lesion as an important cause of hemiballism-hemichorea (HB-HC) [1, 2], subthalamic stroke has long been recognized as a prototype lesion producing this syndrome [3]. These lesions can either be ischemic [4] or hemorrhagic [3, 5], but underlying vascular pathology has been rarely investigated. Previous autopsy studies have described extensive atherosclerotic lesions in arteries including the posterior cerebral artery or the posterior communicating artery in some patients, but the brain lesions examined usually extended far beyond the subthalamic nucleus [6]. We herewith present a patient with subthalamic infarction pro-

ducing HB-HC, which was related to focal stenosis in the posterior communicating artery.

Case Report

A 72-year-old man with a history of hypertension and angina pectoris suddenly developed involuntary movements of the left limbs. On admission the next day, he was alert and cranial nerves were normal. Muscle strength, muscle tone and deep tendon reflexes were within normal limits. Sensory and cerebellar function test results were normal. The patient showed nearly continuous, irregular, ballistic movements of the left limbs, more markedly in the arm than in the leg, and in proximal than in distal parts. There also were occasional choreic movements of the left hand and foot. All these involuntary movements were exaggerated when the patient was speaking, walking or became anxious, and disappeared while he was sleeping.

Brain MRI showed an acute infarct involving the right subthalamic/low thalamic area (fig. 1). Transfemoral angiography showed that the right posterior cerebral artery was supplied from the right

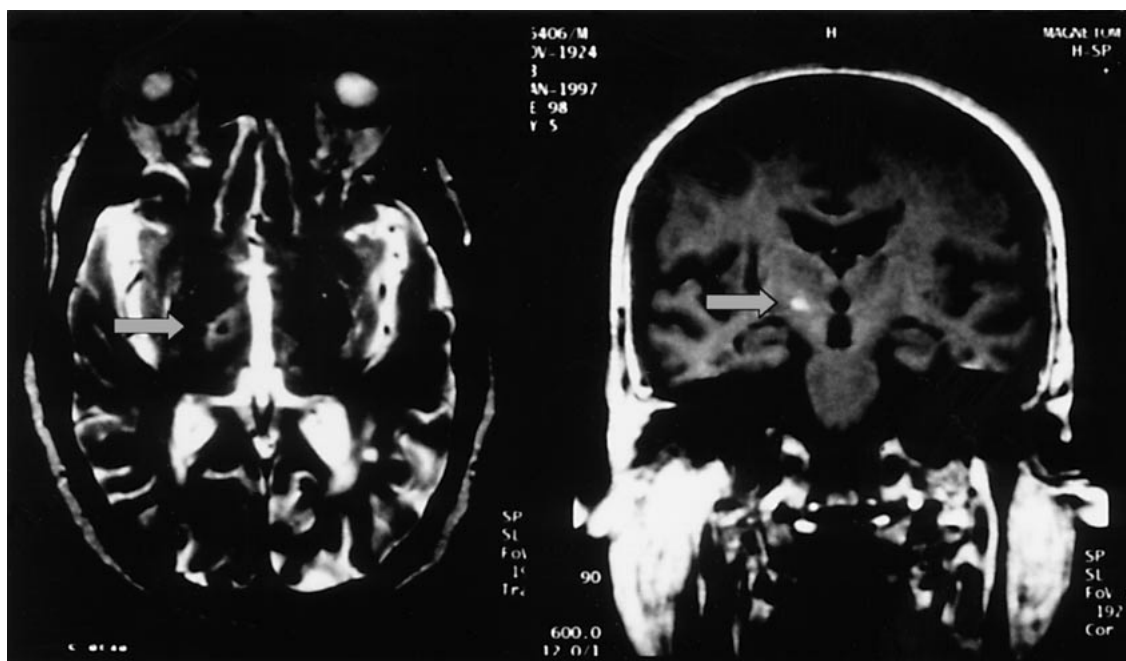
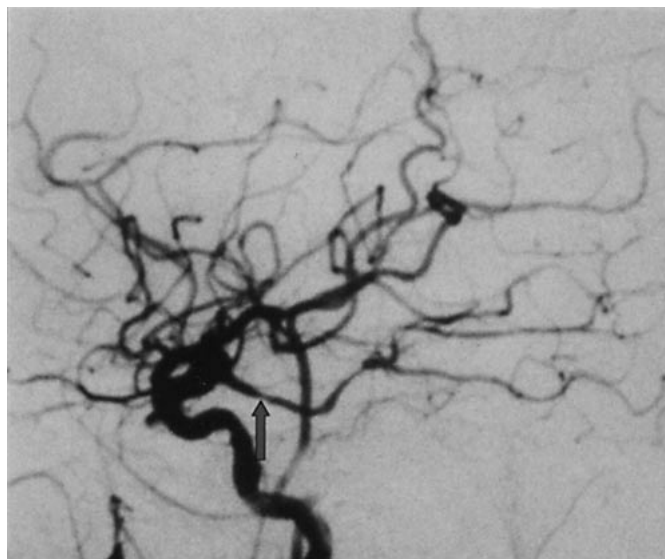


Fig. 1. T₂-weighted MRI (left) showing high signal intensity in the right thalamic-subthalamic area (arrow). T₁-weighted gadolinium-enhanced MRI (right) showing an enhanced lesion in the right subthalamic area (arrow).

Fig. 2. Angiography (lateral view) showing focal stenosis of the right posterior communicating artery (arrow).



carotid system via the posterior communicating artery (fetal circulation). Anteroposterior and lateral views demonstrated that there was a significant stenosis in the midportion of the right posterior communicating artery (fig. 2). There was no significant stenosis/occlusion in other vessels including the posterior cerebral artery. The patient was treated with diazepam 2 mg and haloperidol 0.5 mg \times 3/day in addition to antihypertensives and aspirin. The HB-HC gradually improved, but mild, intermittent choreic movements of the left hand were still present when he was last followed up 14 months later.

Discussion

The patient described here presented with HB-HC due to cerebral infarction. T₂-weighted axial MRI along with gadolinium-enhanced T₁ imaging showed that the lesion mainly involved the subthalamic-low thalamic area (fig. 1). Although subthalamic infarction has long been known as a classical lesion producing HB-HC [3], the underlying vascular lesion has been rarely described. In our patient, the angiography revealed a focal stenosis in the right posterior communicating artery. Because the subthalamic nucleus/low thalamus has been shown to be supplied by posteromedian group branches from the posterior communicating artery, anterior choroidal artery and, less importantly, from the proximal portion of the posterior cerebral artery [6, 7], the vascular lesion of the posterior communicating artery shown in our patient appears to have resulted in the infarction, probably by way of occlusion of the penetrating branches arising from the stenosed vessel. This case therefore corroborates with a capsular infarction due to middle cerebral artery stenosis and pontine infarction secondary to basilar artery disease [8]. To our knowledge, this is the first *in vivo* documentation of focal posterior communicating artery disease causing isolated subthalamic infarction resulting in HB-HC. Nevertheless, this anecdotal case study does not inform us of the actual frequency of posterior communicating artery disease as an etiology of HB-HC, which should be investigated with a large number of patients.

References

- 1 Ghika J, Bogousslavsky J: Abnormal movements; in Bogousslavsky J, Caplan LR (eds): *Stroke Syndromes*. New York, Cambridge University Press, 1995, pp 91–101.
- 2 Lee BC, Hwang S-H, Chang GY: Hemiballism-hemichorea in older diabetic women: A clinical syndrome with MRI correlation. *Neurology* 1999;52: 646–648.
- 3 Martin JP: Hemichorea resulting from a local lesion of the brain (The syndrome of the body of Luys). *Brain* 1927;50:637–651.
- 4 Ghika-Schmid F, Ghika J, Regli F, Bogousslavsky J: Hyperkinetic movement disorders during and after acute stroke: The Lausanne Stroke Registry. *J Neurol Sci* 1997;146:109–116.
- 5 Melamed E, Korn-Lubetzki I, Reches A, et al: Hemiballismus: Detection of focal hemorrhage in subthalamic nucleus by CT scan. *Ann Neurol* 1978;4: 582.
- 6 Martin JP: Hemichorea (hemiballismus) without lesions in the corpus Luy-sii. *Brain* 1957;80:1–10.
- 7 Foix C, Hillemand J: Irrigation de la couche optique. *CR Soc Biol (Paris)* 1925;92:52–54.
- 8 Caplan LR: Intracranial branch atheromatous disease: A neglected, under-studied, and underused concept. *Neurology* 1989;39:1246–1250.

Jong S. Kim, MD
Department of Neurology, Asan Medical Center, Song-Pa PO Box 145
Seoul 138-600 (South Korea)
Tel. +82 2 2224 3442, Fax +82 2 474 4691
E-Mail jongskim@www.amc.seoul.kr

Copyright: S. Karger AG, Basel 2001. Reproduced with the permission of S. Karger AG, Basel. Further reproduction or distribution (electronic or otherwise) is prohibited without permission from the copyright holder.

Copyright: S. Karger AG, Basel 2001. Reproduced with the permission of S. Karger AG, Basel. Further reproduction or distribution (electronic or otherwise) is prohibited without permission from the copyright holder.