

# Isolated angiitis of the CNS in children

S. Lanthier, MD; A. Lortie, MD; J. Michaud, MD; R. Laxer, MD; V. Jay, MD; and G. deVeber, MD

**Article abstract**—*Objective:* To clarify the clinical features and pathologic manifestations of isolated angiitis of the CNS (IACNS) in children. *Methods:* The authors report two new cases and summarize the literature of childhood IACNS confirmed by pathology. *Results:* IACNS affecting small vessels (n = 5)—Neurologic manifestations included headaches, focal seizures, and progressive, behavioral, or multifocal neurologic impairment. MRI showed multifocal, T2-hyperintense, cerebral lesions without mass effect or tumor-like lesions. CSF, erythrocyte sedimentation rate, and cerebral angiograms were often normal. CNS biopsy disclosed a nongranulomatous vasculitis. Children were treated with prednisone alone or combined with cyclophosphamide. One child died. Four children had a favorable outcome. IACNS affecting large and medium arteries (n = 5)—Three children presented with acute ischemic stroke or TIA. Brain CT showed ischemic infarcts. Two children presented with subarachnoid hemorrhage. In this group, CSF, erythrocyte sedimentation rate, and angiograms were often abnormal. No patient received immunosuppressive therapy. Five children died. Autopsy showed granulomatous IACNS (n = 5) *Conclusions:* Clinical and radiologic features correlate with the size of affected vessels. Prognosis differs between groups. Potential markers of poor outcome are acute stroke presentation secondary to large and medium-sized artery involvement, granulomatous angiitis, and delayed institution of immunosuppressive therapy.

NEUROLOGY 2001;56:837–842

Isolated angiitis of the CNS (IACNS), also known as primary angiitis of the CNS, is an idiopathic vasculitis confined to the CNS.<sup>1</sup> A definitive diagnosis requires confirmation by pathology and exclusion of disorders that mimic the disease.<sup>2–4</sup> Experience in adults shows that IACNS embraces a full spectrum of clinical and pathologic manifestations and degrees of severity.<sup>3</sup> Literature of childhood IACNS is limited to a few case reports,<sup>5–13</sup> with fatal outcome in most instances. We report two children with nongranulomatous IACNS proven by biopsy with good outcomes after follow-up periods of 8 months and 8 years. We also summarize pediatric cases documented by pathology and reported over the last 35 years. Our objective is to clarify the spectrum of clinical and pathologic manifestations in children with IACNS in order to define a clinical approach tailored to this age group.

We reviewed pediatric cases of IACNS identified from two large stroke cohorts: Hôpital Sainte-Justine, Montréal, 1991–1997,<sup>14</sup> and The Hospital for Sick Children, Toronto, 1999–2000. We also searched the English and French literature to identify reported cases in children, using Embase (1980–June 2000) and Medline (1966–May 2000) databases, and cross-checked references listed in retrieved articles. We contacted some authors for additional data.<sup>5,7</sup> We included all patients

age 0 to 18 years with IACNS proven by CNS biopsy or autopsy. IACNS was classified as granulomatous (presence of giant cells or granulomatous inflammation within vessel wall) and nongranulomatous.<sup>1</sup> Artery sizes as determined by angiograms were divided into large (carotid arteries and vertebrobasilar system and their primary branches, including A1, M1, and P1 segments), medium (secondary and tertiary branches of the large arteries), and small (quaternary branches, usually  $\leq 1$  mm and best seen on magnification).<sup>15</sup> Using pathology and angiography to determine the size of the CNS blood vessels that were predominantly affected, we classified cases with brain involvement as IACNS affecting small vessels and IACNS affecting large and medium-sized arteries.

**Case 1.** A 10-year-old girl presented with left-sided focal seizures. The history and examination were unremarkable. Electroencephalograms showed moderate right central and posterior slowing. Brain MRI revealed two large, T2-hyperintense, gadolinium-enhancing lesions involving the right parietal cortex and white matter with no mass effect. Four subcortical lacune-like lesions were also present in the right middle and posterior cerebral artery distributions. Cerebral angiogram disclosed a single stenosis in a quaternary branch of the right middle cerebral artery (figure 1). Erythrocyte sedimentation rate (ESR), C-reactive protein, and other laboratory tests; renal angiography;

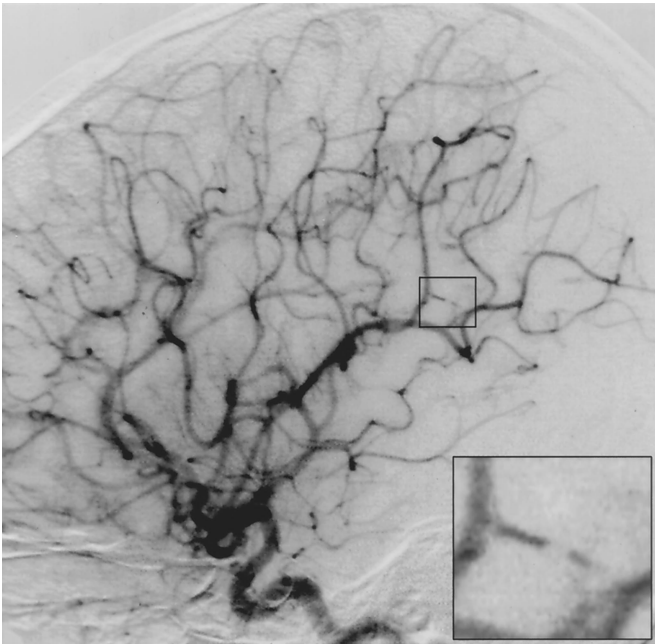
From the Department of Pediatrics, Divisions of Neurology (Drs. Lanthier and deVeber) and Rheumatology (Dr. Laxer), and Department of Pathology (Dr. Jay), The Hospital for Sick Children and University of Toronto; the Département de Médecine, Service de Neurologie, Centre Hospitalier de l'Université de Montréal (Dr. Lanthier) and Département de Pédiatrie, Service de Neurologie, Hôpital Sainte-Justine (Dr. Lortie), and Université de Montréal; and the Department of Pathology (Dr. Michaud), Children's Hospital of Eastern Ontario and University of Ottawa, Canada.

Supported by grants from the Bloorview Children's Hospital Foundation and the Heart and Stroke Foundation of Ontario.

Presented at the 52nd annual meeting of the American Academy of Neurology; May 4, 2000; San Diego, CA.

Received August 22, 2000. Accepted in final form December 23, 2000.

Address correspondence and reprint requests to Dr. Gabrielle deVeber, Division of Neurology, The Hospital for Sick Children, 555 University Avenue, Toronto, Ontario, Canada, M5G 1X8; e-mail: deveber@sickkids.on.ca

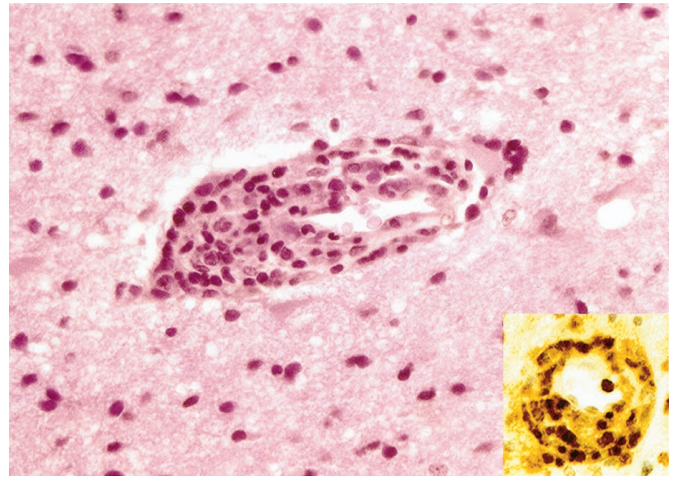


*Figure 1. Case 1: Selective cerebral angiography (mid-arterial phase). Single small-artery stenosis in a quaternary branch of the right middle cerebral artery. Insert: magnification of the stenosis.*

chest radiography; transthoracic echocardiography; and abdominal ultrasonography showed normal hemostasis and no evidence of rheumatic disease, infection, or neoplasm. Results of CSF analysis and cultures and spinal MRI were normal.

The patient's seizures were controlled with carbamazepine and clobazam. Six weeks after presentation, she developed headaches, nausea, and a left hemiparesis. Repeat brain MRI showed an increase in size of the pre-existing parietal lesions, with mass effect and additional small T2-hyperintense lesions. A right temporal lobe open-brain and leptomeningeal biopsy was performed. A multifocal, vascular and perivascular, predominantly T-lymphocytic infiltrate with occasional eosinophils and B-cell lymphocytes, including plasma cells, was found in the arterioles, capillaries, and venules of the leptomeninges and white matter (figure 2). There were no giant cells, granulomas, or areas of fibrinoid necrosis. The cortical vasculature was minimally affected. However, within the neocortex, small ischemic infarcts and areas of neuronal loss containing macrophages were identified, some adjacent to the infiltrated leptomeningeal vessels. Within the white matter, small areas of necrosis with numerous macrophages, reactive gliosis, and occasional axonal swellings were found. Few small vessels with fibrosis and scanty inflammatory cells were also present. Relatively diffuse myelin pallor, without perivascular distribution, was also noted. There were no microglial nodules, viral inclusions, or evidence of parasitic infection. Stains, cultures, and immunofluorescence testing of the biopsied brain tissue for Ig, C1q, C3, and fibrinogen were negative.

Nongranulomatous IACNS was diagnosed. Treatment with prednisone 2 mg/kg/day was initiated 7 weeks after onset. At 15 weeks, owing to development of truncal obesity and mild hypertension, slow prednisone tapering was



*Figure 2. Case 1: Right temporal lobe open biopsy. White matter small venule surrounded by a chronic inflammatory infiltrate obliterating the vessel lumen. Reactive gliosis is present in the white matter. Insert: CD3 antibody showing a predominance of T-lymphocytes.*

attempted. Her headaches recurred at 25 weeks, and repeat laboratory testing showed elevated blood leukocytes ( $13.3 \times 10^9/L$ ), C-reactive protein (21.2 mg/L, normal  $\leq 6$  mg/L), and ESR (26 mm/hour, normal  $\leq 10$  mm/hour). Repeat brain CT showed only small residual hypodensities in the right parietal lobe and right basal ganglia. She was treated for an additional 20 months with combined prednisone 2 mg/kg/day and cyclophosphamide 2 mg/kg/day. She has now been off all immunosuppressive treatment for 6 years and has had no recurrent symptoms. Neurologic examination shows only mild residual left hemiparesis.

**Case 2.** A 16-year-old girl presented with severe headaches, neck pain, nausea, and vomiting for 2 days. Over the previous year, she had had mild headaches and depression that was improved by fluoxetine. One month before admission, she developed a cough and sore throat that resolved, but headaches increased and became unresponsive to regular analgesics. The history was otherwise unremarkable. The examination showed intact cognition, bilateral optic disk swelling, persistent conjugated right gaze-evoked nystagmus, diffuse hyperreflexia, neutral plantar responses bilaterally, right-sided dysmetria and dysdiadochokinesis, and ataxic gait.

Blood leukocytes were elevated at  $11.9 \times 10^9/L$  (predominantly polymorphonuclears). Toxicology screening was negative. Brain MRI revealed a right cerebellar lesion producing mass effect on the fourth ventricle with obstructive hydrocephalus (figure 3). She received antibiotics, acyclovir, and dexamethasone. A right frontal external ventricular drain was inserted and the initial CSF flow was noted to be under high pressure. CSF analysis showed 747 leukocytes per liter (74% lymphocytes, 18% monocytes, 6% eosinophils, and 2% polymorphonuclears); protein and glucose levels were not measured. CSF stains and cultures were negative. PCR testing was positive for human herpesvirus-7 (HHV-7), but negative for other herpesviruses, *Mycobacterium pneumoniae*, and *Mycoplasma tuberculosis*.

The following day, the patient deteriorated with pro-

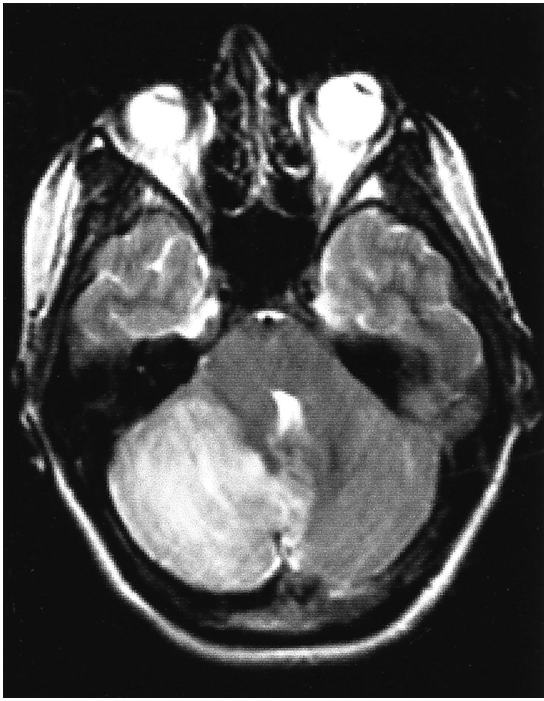

Figure 3. Case 2: T2-weighted brain MRI. Right cerebellar, hyperintense, pseudo-tumoral lesion producing mass effect on the fourth ventricle.

gressive loss of consciousness and decerebration. Brain CT revealed increased hydrocephalus. She underwent drain repositioning and suboccipital craniotomy for posterior decompression and cerebellar biopsy. On pathology, the most striking abnormality was a dense, perivascular and transmural, inflammatory infiltrate affecting small arteries and venules. The infiltrate consisted predominantly of T lymphocytes, as well as many eosinophils and a few neutrophils. There was no evidence of granulomatous angiitis or fibrinoid necrosis. Leptomeningeal vessels were more affected than those of the cerebellar cortex and white matter. The small amount of necrotic and hemorrhagic cerebellar tissue indicated some acute damage, but the marked Purkinje cell loss, Bergmann gliosis, and gliosis of the white matter implied a more chronic process. There were no intraparenchymal granulomas, viral inclusions, microglial nodules, or evidence of a parasitic infection. Tissue stains and cultures disclosed no infection. Electron microscopy showed endothelial cell necrosis in some vessels and transmural inflammatory infiltrate indicating vasculitis. There were no viral inclusions, tubuloreticular inclusions, or Birbeck granules (specifically evaluated in view of the presence of eosinophils in the inflammatory infiltrate).

Investigations performed after the surgery showed elevated ESR (20 mm/hour, normal  $\leq 10$  mm/hour) and C-reactive protein (45.6 mg/L, normal  $\leq 8$  mg/L), normal hemostasis, and no evidence of rheumatic disease, infection, or neoplasm. Findings of chest radiography and selective cerebral angiography were normal. A diagnosis of nongranulomatous IACNS was made. The patient improved on prednisone 1 mg/kg/day. C-reactive protein and ESR are normalized. After 8 months of follow-up, she is asymptomatic on a tapering dose of prednisone.

**Discussion.** One child with granulomatous IACNS limited to the spinal cord has been reported.<sup>13</sup> He presented with progressive myelopathy and responded to prednisone therapy. Eight children with IACNS with brain involvement have been previously reported<sup>5-12</sup>; they are summarized together with Cases 1 and 2 from the current report in the table and below in terms of caliber of involved vessels.

*IACNS affecting small vessels.* Children in this group ( $n = 5$ , including Cases 1 and 2)<sup>5-7</sup> had gradual symptom onset consisting of persistent headaches ( $n = 3$ ), additive multifocal neurologic deficits ( $n = 2$ ), cognitive decline ( $n = 1$ ), and mood disorder ( $n = 1$ ), and presented with focal seizures ( $n = 3$ ). Brain MRI was abnormal in all children. In two of them, it showed a single, large, cortico-subcortical, gadolinium-enhanced lesion producing mass effect and suggesting the diagnosis of brain tumor. Cerebral angiography was normal in all except one child (Case 1). In this group, the diagnosis of IACNS was established by CNS biopsy, which revealed a nongranulomatous (lymphocytic) vasculitis affecting small vessels ( $n = 5$ ) and medium arteries ( $n = 1$ ). Fibrinoid necrosis was not reported. The two children with tumor-like lesions on MRI remained clinically stable without recurrence at 8 months (Case 2) and 2 years after initiation of prednisone therapy.<sup>7</sup> One child (Case 1) had recurrent symptoms after a 4-month course of prednisone therapy but had no further recurrence over 6 years after an additional 20 months with combined prednisone and cyclophosphamide. A fourth child first received prednisone 60 mg/day, which was tapered over 6 weeks.<sup>5</sup> After he developed a pontine hematoma 4 months after presentation, he was treated with combined prednisone and cyclophosphamide but experienced seizures and progressive cognitive decline. He died of status epilepticus 18 months after presentation. Autopsy disclosed a granulomatous IACNS limited to small cerebral arteries and veins. The fifth child in this group was reported to improve on combined prednisone and cyclophosphamide therapy during a 20-month follow-up period.<sup>6</sup>

*IACNS affecting large and medium-sized arteries.* In this group ( $n = 5$ ),<sup>8-12</sup> reasons for seeking medical attention were large arterial ischemic stroke ( $n = 2$ ),<sup>8,10</sup> TIA ( $n = 1$ ),<sup>12</sup> and subarachnoid hemorrhage ( $n = 2$ ).<sup>9,11</sup> Minor prodromal symptoms were reported in two children. Four children in this group died within 10 days of presentation.<sup>8-11</sup> The fifth child developed cerebral hematomas secondary to recurrent aneurysm ruptures.<sup>12</sup> Pathologic analysis of one resected aneurysm revealed an inflammatory infiltration of the aneurysm wall. This child did not receive immunosuppressive therapy. He lapsed into a persistent vegetative state and died 7 years after presentation. In this group, autopsy showed a granulomatous infiltration of large and medium CNS arteries ( $n = 5$ ), inconsistent extension to small CNS arteries ( $n = 2$ ),<sup>9,11</sup> and vessel wall (fibrinoid) necrosis ( $n = 2$ ).<sup>9,10</sup> Tuberculosis, sarcoidosis, Wegener granulomatosis, Churg–Strauss syndrome, and other granulomatous

**Table** Clinical manifestations, treatment, and outcome in 10 cases of childhood IACNS with brain involvement

| Variable                  | IACNS affecting small vessels*   | IACNS affecting large and medium-sized arteries   |   |
|---------------------------|--|---|---|
|                           |  | AIS (n = 2) <sup>8,10</sup> and TIA (n = 1) <sup>12</sup>   | SAH (n = 2) <sup>9,11</sup>   |
| Age, y (M/F)              | 6–16 (2/3)   | 3–15 (1/2)  | 1.25–15 (1/1)   |
| Neurologic manifestations | Headache with progressive, behavioral or multifocal neurologic impairment for $\leq 1$ y (3/5); focal seizures (3/5)                       | Mild headaches and dizziness for 2 wk (1/3); acute headache and sudden focal neurologic deficit (3/3) | Mild headaches for 6 mo (1/2); acute headache and loss of consciousness or sudden death (2/2) |
| Initial neuroimaging      | Brain MRI: multiple lacunes (2/5), large T2-hyperintense cortico-subcortical areas without mass effect (2/5), large tumorlike lesion (2/5) | Brain CT: multiple lacunes and a single small hypodense area (1/2); large hypodense area (1/2)        |   |
| ESR                       | Elevated (1/3); <sup>†</sup> normal (2/3)  | Elevated (1/1)  |   |
| CSF                       | Inflammation (1/3); normal (2/3)   | Inflammation (2/3); normal (1/3)  | Hemorrhagic (1/1)   |
| Cerebral angiography      | Normal (4/5); single small-artery stenosis (1/5)   | Normal (1/2); multiple medium-sized artery stenoses and aneurysms (1/2)                               | Single aneurysm (1/1)   |
| Treatment                 | Immunosuppression (5/5)  | No immunosuppression (3/3)  | No immunosuppression (2/2)  |
| Outcome                   | Death 18 mo after presentation (1/5); alive, no recurrence (4/5)   | Death within 3 d (2/3) and 7 y after presentation (1/3)   | Death within 10 d after presentation (2/2)  |

\* N = 5, including our two cases.<sup>5-7</sup>

<sup>†</sup> Measured after brain surgery.

IACNS = isolated angitis of the CNS; AIS = arterial ischemic stroke; SAH = subarachnoid hemorrhage; ESR = erythrocyte sedimentation rate.

processes affecting CNS vessels in children were excluded by the absence of systemic involvement and pathologic hallmarks of these conditions.

We used the size of the affected vessels, as determined by angiography and pathology, to define two groups of IACNS patients with brain involvement. Although the groups are not mutually exclusive, as shown by the coexisting involvement of small vessels and large or medium arteries in two children<sup>9,11</sup> and some adults,<sup>16</sup> their clinical manifestations and short-term prognosis differ. This classification is therefore relevant clinically and may help distinguish the approach to therapy.

**IACNS affecting small vessels.** Most adults with IACNS documented by pathology have small vessel involvement.<sup>3</sup> Children and adults with IACNS and small vessel involvement are similar in several aspects: they are more likely to experience a clinical course that is gradual and variable, with headaches, focal seizures, multifocal neurologic deficits, and neurobehavioral impairment, reflecting multifocal or diffuse brain damage. Neuroimaging reveals multiple cerebral ischemic lesions and tumor-like lesions. In comparison with the adult series,<sup>3</sup> seizures and

tumor-like presentations were reported more frequently in children with small vessel disease. CSF and ESR are often normal. Angiograms are generally unremarkable, because the size of the affected vessels is often below the resolution of this technique. CNS biopsy directed at cerebral lesions identified on neuroimaging leads to antemortem diagnosis of IACNS and initiation of immunosuppressive treatment. Response to treatment varies from long-term remission, possibly achievable with prednisone alone, to resistance to combined prednisone and cyclophosphamide, resulting in gradual neurologic decline and death.

In this series, CNS biopsy revealed a nongranulomatous form of IACNS in all children with small vessel involvement. In the only patient who failed to respond to immunosuppressive therapy, granulomas were found within small vessel walls at autopsy performed 14 months after biopsy. In children with IACNS affecting small vessels, the absence of granulomas on CNS biopsy could be due to sampling error, given the segmental distribution and pathologic heterogeneity of vascular lesions in IACNS.<sup>1</sup> However, the existence of a lymphocytic (nongranulomatous)

form of IACNS has been repeatedly confirmed by autopsy reports,<sup>16</sup> and associated with a better outcome in adults.<sup>17</sup> The lymphocyte infiltration may represent one of the first changes in IACNS, whereas the presence of granulomas may signal a more aggressive or advanced form of the disease.

In one of our patients (Case 2), PCR assay on CSF was positive for HHV-7. This adolescent had no recent or current exanthema and no fever. Pathologic examination and electron microscopy showed no evidence of viral encephalitis. HHV-7, like HHV-6, is a causal agent of roseola, which can be complicated by acute encephalopathy.<sup>18</sup> We are not aware of any report linking HHV-7 with IACNS. Several viruses have been associated with CNS vasculopathies, including herpes zoster virus.<sup>19</sup> The detection of HHV-7 by PCR on CSF should be interpreted with caution.<sup>18</sup> HHV-6 DNA can persist in the CSF after childhood infection.<sup>20</sup> The same may be true for HHV-7.

*IACNS affecting large and medium-sized arteries.* Children in this group are more likely to present with TIA, arterial ischemic stroke, or hemorrhagic stroke, and to die of neurologic complications of acute stroke. Elevated ESR, inflammatory CSF, and abnormal angiograms are more frequent than in the first group. For this group, granulomatous IACNS was diagnosed at autopsy. We suspect that presumptive cases of IACNS are often treated on the basis of clinical evaluation and "vasculitic" changes seen on angiograms.<sup>21</sup>

*Clinical approach.* The clinical evaluation and investigation should exclude drug exposure, systemic infections, thromboembolic processes, childhood rheumatic diseases, and other mimics of IACNS.<sup>2-4</sup> Systemic lupus erythematosus and microscopic polyangiitis should be considered in children with involvement of small-sized CNS vessels.<sup>22</sup> Polyarteritis nodosa, Kawasaki disease, Churg–Strauss syndrome, and Wegener granulomatosis affect small and medium arteries.<sup>22</sup> IACNS affecting medium and large arteries should be differentiated from benign angiopathy of the CNS<sup>3</sup> and post-varicella arteriopathy,<sup>23</sup> which generally follow a monophasic course. Typically, post-varicella arteriopathy occurs within 9 months of the chickenpox primary infection and affects the proximal segments of the middle and anterior cerebral arteries unilaterally. Takayasu arteritis affects the aorta and its branches but spares intracranial vessels.<sup>22</sup> Giant cell temporal arteritis rarely or never affects children.<sup>22</sup> Inflammatory bowel disease, sarcoidosis,<sup>24</sup> and Behçet disease<sup>25</sup> can be complicated by CNS vasculitis, which may involve arteries and veins of any size. Systemic rheumatic diseases are diagnosed based on their distinct pattern of systemic manifestations and laboratory markers, although in rare cases they may be unrecognizable early in their course if the CNS is involved first.

In children with suspected IACNS, our approach is to attempt to confirm the diagnosis of CNS vasculitis and to exclude intracranial infection and neo-

plasm by leptomenigeal and brain biopsy of a radiologically affected area before initiating immunosuppression. CSF and biopsied CNS tissue should be analyzed and cultured. On pathology, vascular changes consistent with a diagnosis of IACNS include multifocal and segmental infiltrates, fibrinoid necrosis, and vessel fibrosis indicating healing lesions. The vessel infiltrates consist predominantly of lymphocytes, variably associated with giant cells that form granulomas and eosinophils. The risk of false-negative CNS biopsy (17 to 53% in adults with IACNS<sup>26</sup>) is greater if the disease is restricted to large arteries not sampled by this procedure, and if pathologic study is limited to the leptomeninges<sup>5</sup> or to evacuated necrotic tissue from cerebral infarction.<sup>10</sup> Occasionally, systemic rheumatic diseases can be identified by the presence of typical pathologic findings (e.g., necrotizing vascular lesions with polymorphonuclear leukocytes infiltrating branching points of small and medium arteries, associated with microaneurysms, suggest polyarteritis nodosa).<sup>27</sup>

Subarachnoid hemorrhage is rarely reported and usually mild in adults with IACNS.<sup>19</sup> Subarachnoid hemorrhage from rupture of aneurysm or nonaneurysmal dilatation is unusual in childhood<sup>28</sup> and should raise the possibility of CNS vasculitis, especially when atypical features are found (e.g., nonsaccular aneurysm, location distal to bifurcations) and after infectious and traumatic causes have been excluded. Clipped aneurysms should be biopsied whenever feasible and analyzed by pathology. When an intracranial aneurysm located in a peripheral branch artery is treated by occluding its proximal segment, the sacrificed distal segment of artery should be submitted for pathologic analysis.

In children presenting with acute stroke, supportive care, appropriate antithrombotic treatment, and measures to prevent stroke complications should be initiated with the aim of decreasing early morbidity.<sup>29</sup> A combination of cyclophosphamide and prednisone is the recognized treatment of IACNS in adults.<sup>2,19</sup> The efficacy of prednisone or cyclophosphamide alone in IACNS is undetermined and should be assessed prospectively in patients selected on the basis of prognostic factors. In children with IACNS, potential markers of poor outcome are an acute stroke presentation secondary to large and medium-sized artery involvement, a granulomatous IACNS on pathology, and delayed institution of immunosuppressive therapy. Response to immunosuppressive treatment should be monitored, its effects shown by stabilization of clinical and radiologic manifestations and by normalization of laboratory results, including CSF analysis and ESR. Because CNS involvement may herald rheumatic diseases in some patients, vigilant appraisal of delayed systemic manifestations is an essential part of the follow-up.

#### Acknowledgment

The authors thank Ms. C. Tunney for her assistance in the search of Embase and Medline databases; Ms. T. Domi, Dr. S. Mayank,

and Dr. M. Salmon for their assistance in the preparation of this manuscript; and Dr. M.W. Bojanowski, Centre Hospitalier de l'Université de Montréal, for valuable discussion on the surgery of intracranial aneurysm. This paper was prepared with the assistance of Editorial Services, The Hospital for Sick Children, Toronto.

## References

1. Lie JT. Primary (granulomatous) angiitis of the central nervous system: a clinicopathological analysis of 15 new cases and review of the literature. *Hum Pathol* 1992;23:164-171.
2. Moore PM. Diagnosis and management of isolated angiitis of the central nervous system. *Neurology* 1989;39:167-173.
3. Calabrese LH, Duna GF, Lie JT. Vasculitis in the central nervous system. *Arthritis Rheum* 1997;40:1189-1201.
4. Alrawi A, Trobe JD, Blaivas M, Musch DC. Brain biopsy in primary angiitis of the central nervous system. *Neurology* 1999;53:858-860.
5. Matsell DG, Keene DL, Jimenez C, Humphreys P. Isolated angiitis of the central nervous system in childhood. *Can J Neurol Sci* 1990;17:151-154.
6. Stübgen JP. Isolated angiitis of the central nervous system. *S Afr Med J* 1993;83:618-619. Letter.
7. Katsicas MM, Russo R, Taratuto A, Pocięcha J, Zelazko M. Primary angiitis of the central nervous system presenting as a mass lesion in a child. *J Rheumatol* 2000;27:1297-1298.
8. Marsden HB. Basilar artery thrombosis and giant cell arteritis. *Arch Dis Child* 1974;49:75. Abstract.
9. Shuangshoti S. Localized granulomatous (giant cell) angiitis of brain with eosinophil infiltration and saccular aneurysm. *J Med Assoc Thai* 1979;62:281-289.
10. Nagaratnam N, James WE. Isolated angiitis of the brain in a young female on the contraceptive pill. *Postgrad Med J* 1987;63:1085-1086.
11. Kumar R, Wijidicks EFM, Brown Jr RD, Parisi JE, Hammond CA. Isolated angiitis of the CNS presenting as subarachnoid haemorrhage. *J Neurol Neurosurg Psychiatry* 1997;62:649-651.
12. Nishikawa M, Sakamoto H, Katsuyama J, Hakuba A, Nishimura S. Multiple appearing and vanishing aneurysms: primary angiitis of the central nervous system. *J Neurosurg* 1998;88:133-137.
13. Giovanini MA, Eskin TA, Mukherji SK, Mickle JP. Granulomatous angiitis of the spinal cord: a case report. *Neurosurgery* 1994;34:540-543.
14. Lanthier S, Carmant L, David M, Larbrisseau A, deVeber G. Stroke in children: the co-existence of multiple risk factors predicts poor outcome. *Neurology* 2000;54:371-378.
15. Alhalabi M, Moore PM. Serial angiography in isolated angiitis of the central nervous system. *Neurology* 1994;44:1221-1226.
16. Rhodes RH, Madelaire NC, Petrelli M, Cole M, Karaman BA. Primary angiitis and angiopathy of the central nervous system and their relationship to systemic giant cell arteritis. *Arch Pathol Lab Med* 1995;119:334-349.
17. Pou Serradell A, Masó E, Roquer J, Oliveras C, Herraiz J, Alameda F. Angéite isolée du système nerveux central: étude clinique et neuropathologique de deux cas. *Rev Neurol* 1995;151:258-266.
18. van den Berg JSP, van Zeijl JH, Rotteveel JJ, Melchers WJG, Gabreëls FJM, Galama JMD. Neuroinvasion by human herpesvirus type 7 in a case of exanthem subitum with severe neurologic manifestations. *Neurology* 1999;52:1077-1079.
19. Moore PM, Richardson B. Neurology of the vasculitides and connective tissue diseases. *J Neurol Neurosurg Psychiatry* 1998;65:10-22.
20. Caserta MT, Breese Hall C, Schnabel K, et al. Neuroinvasion and persistence of human herpesvirus 6 in children. *J Infect Dis* 1994;170:1586-1589.
21. Ilhan A, Budak F. Primary angiitis of the central nervous system: unusual clinical presentation. *Int J Angiol* 2000;9:23-26.
22. Sheets RM, Ashwal S, Szer IS. Neurologic manifestations of rheumatic disorders of childhood. In: Swaiman KF, Ashwal S, eds. *Pediatric neurology: principles and practice*. St. Louis: Mosby, 1999:1125-1146.
23. Sébire G, Meyer L, Chabrier S. Varicella as a risk factor for cerebral infarction in childhood: a case-control study. *Ann Neurol* 1999;45:679-680.
24. Shetty AK, Gedalia A. Sarcoidosis in children. *Curr Probl Pediatr* 2000;30:153-176.
25. Koné-Paut I, Chabrol B, Riss JM, Mancini J, Raybaud C, Garnier JM. Neurologic onset of Behçet's disease: a diagnostic enigma in childhood. *J Child Neurol* 1997;12:237-241.
26. Chu CT, Gray L, Goldstein LB, Hulette CM. Diagnosis of intracranial vasculitis: a multi-disciplinary approach. *J Neuropathol Exp Neurol* 1998;57:30-38.
27. Kalimo H, Kaste M, Haltia M. Vascular diseases. In: Graham DI, Lantos PL, eds. *Greenfield's neuropathology*. London: Arnold, 1997:315-396.
28. Allison JW, Davis PC, Sato Y, et al. Intracranial aneurysms in infants and children. *Pediatr Radiol* 1998;28:223-229.
29. Andrew M, deVeber G, eds. *Pediatric thromboembolism and stroke protocols*. Hamilton: BC Decker, 1999.

# Neurology<sup>®</sup>

## Isolated angiitis of the CNS in children

S. Lanthier, A. Lortie, J. Michaud, et al.

*Neurology* 2001;56;837-842

DOI 10.1212/WNL.56.7.837

**This information is current as of April 10, 2001**

|   |   |
|---|---|
| <b>Updated Information &amp; Services</b> | including high resolution figures, can be found at:<br><a href="http://www.neurology.org/content/56/7/837.full.html">http://www.neurology.org/content/56/7/837.full.html</a>  |
| <b>References</b>                         | This article cites 25 articles, 9 of which you can access for free at:<br><a href="http://www.neurology.org/content/56/7/837.full.html#ref-list-1">http://www.neurology.org/content/56/7/837.full.html#ref-list-1</a>                         |
| <b>Citations</b>                          | This article has been cited by 19 HighWire-hosted articles:<br><a href="http://www.neurology.org/content/56/7/837.full.html#otherarticles">http://www.neurology.org/content/56/7/837.full.html#otherarticles</a>                              |
| <b>Permissions &amp; Licensing</b>        | Information about reproducing this article in parts (figures, tables) or in its entirety can be found online at:<br><a href="http://www.neurology.org/misc/about.xhtml#permissions">http://www.neurology.org/misc/about.xhtml#permissions</a> |
| <b>Reprints</b>                           | Information about ordering reprints can be found online:<br><a href="http://www.neurology.org/misc/addir.xhtml#reprintsus">http://www.neurology.org/misc/addir.xhtml#reprintsus</a>   |

*Neurology*® is the official journal of the American Academy of Neurology. Published continuously since 1951, it is now a weekly with 48 issues per year. Copyright . All rights reserved. Print ISSN: 0028-3878. Online ISSN: 1526-632X.

