

Thrombotic Stroke in a Child with Diarrhea-Associated Hemolytic-Uremic Syndrome with a Good Recovery

TOHRU NAKAHATA, HIROSHI TANAKA, TAKASHI TATEYAMA, TOMOMI UEDA, KOICHI SUZUKI, SHIN-ICHI OSARI,¹ MIKIO KASAI¹ and SHINOBU WAGA

Department of Pediatrics, Hirosaki University School of Medicine, Hirosaki 036-8562 and

¹Division of Pediatrics, Hirosaki Municipal Hospital, Hirosaki 036-8182

NAKAHATA, T., TANAKA, H., TATEYAMA, T., UEDA, T., SUZUKI, K., OSARI, S., KASAI, M. and WAGA, S. *Thrombotic Stroke in a Child with Diarrhea-Associated Hemolytic-Uremic Syndrome with a Good Recovery.* Tohoku J. Exp. Med., 2001, 193 (1), 73-77 — A boy aged 3.5 years with post-diarrheal hemolytic-uremic syndrome (HUS) was referred to our hospital because of convulsion and stupor. He had been admitted to a regional hospital with a 3-day history of bloody diarrhea, colic abdominal pain and fever. Two days later, he had complained of generalized seizures and oliguria. On admission, he developed anuria, and serum blood nitrogen and creatinine increased to 56 mg/100 ml and 2.8 mg/100 ml, respectively. Platelets decreased to 42 000/ μ l. Under the diagnosis of HUS, a continuous hemodiafiltration treatment had to be instituted. Computed tomography of his head at hospital day 5 revealed abnormal low density area of infarction with edema in both the basal ganglia involving with the posterior limb of internal capsule. Serum titer of IgM antibody to *Escherichia coli* O157 showed positive value. Although his anuria and stupor persisted over 10 days, he recovered without serious complications. These clinical observations may indicate that patients with similar lesions do not necessarily have serious morbidity. ——— central nervous system involvement; continuous hemodiafiltration; favorable outcome; hemolytic-uremic syndrome; stroke

© 2001 Tohoku University Medical Press

Received November 1, 2000; revision accepted for publication January 29, 2001.

Address for reprints: Hiroshi Tanaka, M.D., Department of Pediatrics, Hirosaki University School of Medicine, 5 Zaifu-cho, Hirosaki 036-8562, Japan.

e-mail: hirokana@cc.hirosaki-u.ac.jp

Although the hemolytic-uremic syndrome (HUS) is the common cause of acute renal failure in young children, the central nervous system (CNS) involvement has been reported to be a major contributor to mortality or chronic morbidity of the HUS (Bale et al. 1980; Upadhyaya et al. 1980; Hamano et al. 1993; Siegler 1994; Gallo and Gianantonio 1995). It is generally assumed that the HUS encephalopathy is due to metabolic derangement and action of Shiga-like toxin causing microvascular damage (Upadhyaya et al. 1980; Hamano et al. 1993; Siegler 1994). Of the CNS involvement, about 3% to 5% of children with HUS have identifiable structural brain damage in the form of infarcts (Siegler 1994). Despite the general assertion that severe CNS manifestations such as generalized seizures and prolonged coma/stupor portend a poor prognosis (Bale et al. 1980; Trevathan and Dooling 1987; Siegler 1994; Gallo and Gianantonio 1995), some children with HUS complicated with identifiable structural brain damage have been reported to have a good recovery (Steele et al. 1983; Steinberg et al. 1986; Signorini et al. 2000).

We observed a boy with HUS complicated with thrombotic stroke, who showed a good recovery despite prolonged stupor.

CASE REPORT

A Japanese boy aged 3.5 years referred to our hospital because of generalized tonic seizures and lethargy. He had had bloody diarrhea, colic abdominal pain and fever for 3 days, and had been treated with oral fosfomycin (Meiji Co., Tokyo) by a physician. Then he was admitted to a regional hospital. Laboratory studies revealed the following values: white blood cells (WBC) 27 800/ μ l, hemoglobin 14.7 g/100 ml, platelets 376 000/ μ l, serum urea nitrogen (UN) 14 mg/100 ml, creatinine 0.3 mg/100 ml and C-reactive protein (CRP) 5.0 mg/100 ml. Stool culture and a latex aggregation test for Shiga-like toxin were negative. Two

days later, he developed generalized tonic seizures and oliguria. Computed tomography (CT) of the brain at that time was unremarkable. Serum UN and creatinine increased to 62 mg/100 ml and 2.4 mg/100 ml, respectively. Platelets decreased to 73 000/ μ l. He was transferred to us under the diagnosis of post-diarrheal HUS.

On admission, the patient was pale and insensitive to pain. Blood pressure was 120/70 mmHg. He developed anuria. Laboratory studies revealed the following: WBC, 27 500/ μ l with neutrophils of 74%; hemoglobin, 7.7 g/100 ml; hematocrit, 23.6%; platelets, 42 000/ μ l; serum total protein, 4.8 g/100 ml; albumin, 2.1 g/100 ml; UN, 56 mg/100 ml; creatinine, 2.8 mg/100 ml; sodium, 120 mEq/liter; potassium, 4.4 mEq/liter; chloride, 97 mEq/liter; calcium, 7.7 mg/100 ml and CRP, 11.8 mg/100 ml. Immunological studies showed the following values: IgG, 1310 mg/100 ml; IgA, 128 mg/100 ml; IgM, 148 mg/100 ml; C3, 80 mg/100 ml (normal range, 79–152 mg/100 ml); C4, 26 mg/100 ml (normal range, 16–38 mg/100 ml) and hemolytic complement activity, 37.8 U/ml (normal range, 23–46 U/ml). Anti-nuclear antibody was absent. Neither acidemia nor hyperammonemia were identified. Peripheral blood smear showed red blood cell (RBC) fragments. Serum lactate dehydrogenase (LDH) increased to 3652 U/liter (normal range, 80–200), and haptoglobin decreased to less than 6 mg/100 ml (normal range, 36–195 mg/100 ml). The serum level of fibrin/fibrinogen degradation products (FDP) showed a significant increase at 104.9 mg/100 ml (normal range, 0–5.0 mg/100 ml). Although repeated stool cultures were negative, serum IgM antibody to *E. coli* O157 (measured by enzyme-linked immunosorbent assay at Institute of Infectious Diseases, National Children's Hospital) showed positive value. The diagnosis was HUS associated with acute renal failure and CNS involvement. Because of technical problems, measurement of serum antibodies to Shiga-like toxin (Verotoxin 1 and

2) was not done.

He was treated with continuous hemodiafiltration (CHDF) and anticoagulants (nafamostat mesilate and heparin), since CHDF had been reported to be effective in treating and preventing fluid overload in children with multiorgan failure (Lowrie 2000). Blood pressure and body weight were well controlled by CHDF treatment. When the level of hemoglobin dropped to less than 6.5 g/100 ml, transfusion of packed RBC (200 ml) was performed.

Seizures recurred and stupor persisted. Electroencephalogram showed diffuse high voltage slow waves without seizure discharges. Head CT images obtained 4 days after admission disclosed abnormal widespread low density area around both basal ganglia (Fig. 1). There was no evidence of hemorrhage. Since the brain images seemed to be edematous, intravenous dexamethasone administration (1.6 mg/8 hours) for 5 days was started. Treatment with midazolam and phenobarbital was also

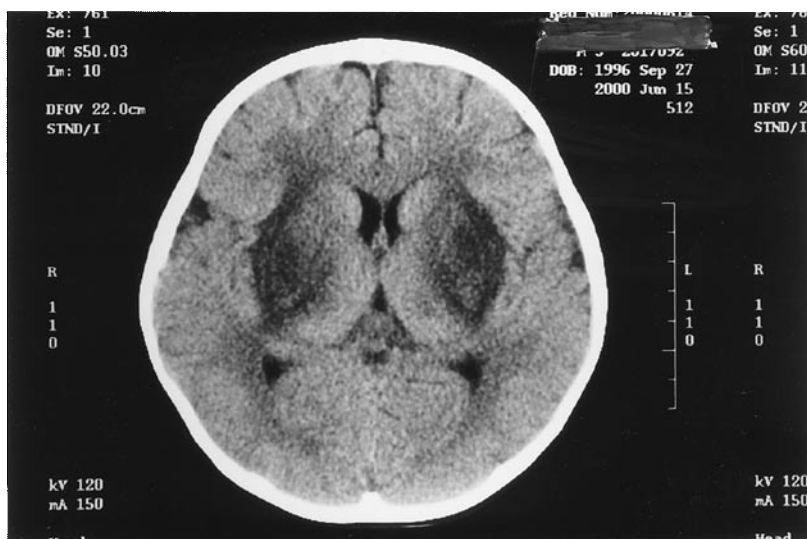


Fig. 1. Axial CT scan, showing areas of decreased density in both basal ganglia in the region of the putamen.

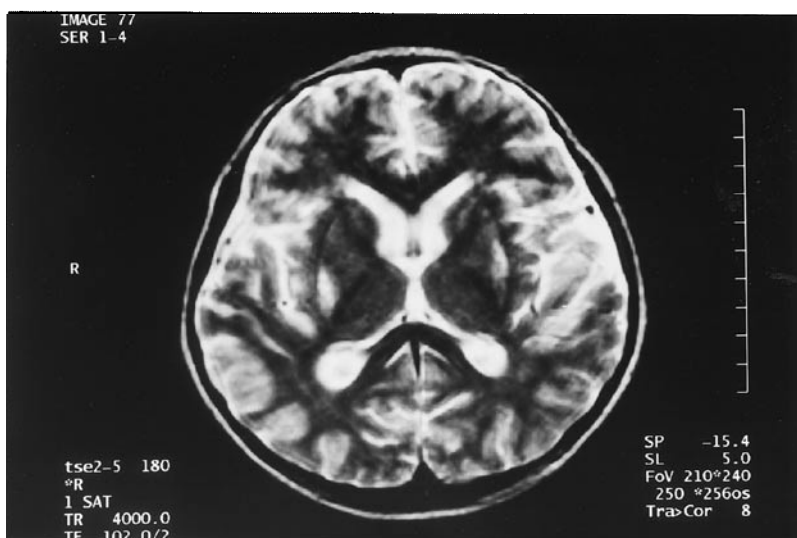


Fig. 2. T2-weighted magnetic resonance imaging on hospital day 33, showing slit-shaped high signal images on the both putamen.

started and he had no further definite convulsions.

After 12 days of these treatment, his urine output was gradually increased and the level of serum UN and creatinine gradually decreased to the normal ranges by hospital day 24. The CHDF treatment was discontinued at hospital day 18. A total of 11 times of packed RBC transfusion was performed. Neither platelets transfusion nor fresh frozen plasma infusion were performed. Platelets count, serum LDH and FDP returned to the normal ranges by hospital day 10, 19 and 24, respectively. The duration of stupor was 32 days. Thereafter, steady improvement in neurologic function was seen. Magnetic resonance images (MRI) obtained hospital day 33 disclosed marked resolution of the lesion except for a slit area of high signal intensity on T2-weighted images in both putamen (Fig. 2).

At present, 5 months after our first observation, he is well except for a residual left hemiparesis, mild dysphemia and mild proteinuria (approximately 60 mg/100 ml).

DISCUSSION

So far the importance of the CNS involvement in HUS patients has been reported (Bale et al. 1980; Upadhyaya et al. 1980; Cimolai et al. 1992; Hamano et al. 1993; Siegler 1994; Gallo and Gianantonio 1995). Although pathogenesis of the CNS involvement in HUS remained to be elucidated, several factors, such as metabolic derangement, action of Shiga-like toxin or microvascular damage may be responsible for the lesion (Upadyaya et al. 1980; Cimolai et al. 1992; Siegler 1994; Gallo and Gianantonio 1995). Recent report (Gallo and Gianantonio 1995) described that extensive microvascular damage and thrombosis may contribute to the multiorgan involvement in diarrhea-associated HUS. Further, Fujii et al. (1996) reported that rabbits given intravenous verotoxin 2 showed a variety of brain damage,

and that the edematous changes determined by MRI and ultrastructural studies were caused by the toxicity of verotoxin 2 which was conveyed from the endothelial and ependymal cell layers.

In our patient, despite persistent anuria, no metabolic derangement or hypertension were seen during the clinical course. Hence, microvascular damage probably caused by Shiga-like toxin from *E. coli* O157, and subsequent vascular thrombosis was the most likely cause of the stroke lesion.

It has also been reported that the importance of systemic release of proinflammatory cytokines in acute inflammatory processes in HUS patients is emphasized (Karpman et al. 1995; Inward et al. 1997). Karpman et al. (1995) reported that serum interleukin (IL)-6 is higher in children with HUS who developed extrarenal manifestations. Also, Inward et al. (1997) reported that a patient with fatal CNS involvement exhibited high concentration of IL-6 in the plasma. From the current literature, circulating inflammatory cytokines as well as thrombosis caused by microvascular damage may be responsible for the CNS involvement.

In our patients, although measurement of serum cytokines was not done, prompt initiation of CHDF treatment may have contributed to remove circulating inflammatory cytokines and to prevent fluid overload, and subsequently resulted in a good recovery.

Since severe CNS manifestations in HUS patients are assumed to portend a poor prognosis (Bale et al. 1980; Trevathan and Dooling 1987; Hamano et al. 1993; Siegler 1994; Gallo and Gianantonio 1995), CHDF treatment may be of benefit in a proportion of HUS patients with severe CNS involvement to change the natural course of the disease as in the recent report describing children with multiorgan failure (Lowrie 2000).

Several patients with severe CNS involvement with a favorable outcome have been reported sporadically to date (Steele et al. 1983; Steinberg et al. 1986; Signorini et al. 2000).

The treatment of these patients varies, i.e., peritoneal dialysis (PD) (Steele et al. 1983), PD with fresh frozen plasma infusion (Steinberg et al. 1986) and hemodialysis with plasma changes (Signorini et al. 2000). Hence, an appropriate therapeutic intervention for HUS patients with severe CNS involvement remains to be elucidated. Further reports to describe similar cases are needed.

Long-term prognosis regarding quality of life in children with episodes of HUS has been reported to be deficit in verbal intelligence and in the verbally based skills of reading comprehension, vocabulary use and in behavior (Schlieper et al. 1992). In our patient, residual left hemiparesis, mild dysphemia and mild proteinuria remained. Careful follow up should be done.

Acknowledgments

The authors thank Dr. Hirofumi Ohkawa and Dr. Toshihito Tsubo for medical care in the emergency room of Critical Care and Emergency Medicine, Hirosaki University and Dr. Tae Takeda, Institute of Infectious Diseases, National Children's Hospital for kindly measurement of IgM antibody to *E. coli* O157.

References

- Bale, J.F., Jr., Brasher, C. & Siegler, R.L. (1980) CNS manifestations of the hemolytic-uremic syndrome. Relationship to metabolic alterations and prognosis. *Am. J. Dis. Child.*, **134**, 869-872.
- Cimolai, N., Morrison, B.J. & Carter, J.E. (1992) Risk factors for the central nervous system manifestations of gastroenteritis-associated hemolytic-uremic syndrome. *Pediatrics*, **90**, 616-621.
- Fujii, J., Kinoshita, Y., Kita, T., Higuchi, A., Takeda, T., Tanaka, N. & Yoshida, S. (1996) Magnetic resonance imaging and histopathological study of brain lesions in rabbits given intravenous verotoxin 2. *Infect. Immun.*, **64**, 5053-5060.
- Gallo, G.E. & Gianantonio, C.A. (1995) Extrarenal involvement in diarrhoea-associated haemolytic-uraemic syndrome. *Pediatr. Nephrol.*, **9**, 117-119.
- Hamano, S., Nakanishi, Y., Nara, T., Seki, T., Ohtani, T., Oishi, T., Joh, K., Oikawa, T., Muramatsu, Y., Ogawa, Y. & Akashi, S. (1993) Neurological manifestations of hemorrhagic colitis in the outbreak of *Escherichia coli* O157: H7 infection in Japan. *Acta Paediatr.*, **82**, 454-458.
- Inward, C.D., Varagunam, M., Adu, D., Milford, D.V. & Taylor, C.M. (1997) Cytokines in haemolytic uraemic syndrome associated with verocytotoxin-producing *Escherichia coli* infection. *Arch. Dis. Child.*, **77**, 145-147.
- Karpman, D., Andreasson, A., Thysell, H., Kaplan, B.S. & Svanborg, C. (1995) Cytokines in childhood hemolytic uremic syndrome and thrombotic thrombocytopenic purpura. *Pediatr. Nephrol.*, **9**, 694-699.
- Lowrie, L.H. (2000) Renal replacement therapies in pediatric multiorgan dysfunction syndrome. *Pediatr. Nephrol.*, **14**, 6-12.
- Schlieper, A., Rowe, P.C., Orrbine, E., Zoubek, M., Clark, W., Wolfish, N. & McLaine, P.N. (1992) Sequelae of haemolytic uraemic syndrome. *Arch. Dis. Child.*, **67**, 930-934.
- Siegler, R.L. (1994) Spectrum of extrarenal involvement in postdiarrheal hemolytic-uremic syndrome. *J. Pediatr.*, **125**, 511-518.
- Signorini, E.S., Lucchi, S., Mastrangelo, M., Rapuzzi, S., Edefonti, A. & Fossali, E. (2000) Central nervous system involvement in a child with hemolytic uremic syndrome. *Pediatr. Nephrol.*, **14**, 990-992.
- Steele, B.T., Murphy, N., Chuang, S.H., McGreal, D. & Arbus, G.S. (1983) Recovery from prolonged coma in hemolytic uremic syndrome. *J. Pediatr.*, **102**, 402-404.
- Steinberg, A., Ish-Horowitz, M., El-Peleg, O., Mor, J. & Branski, D. (1986) Stroke in a patient with hemolytic-uremic syndrome with a good outcome. *Brain Dev.*, **8**, 70-72.
- Trevathan, E. & Dooling, E.C. (1987) Large thrombotic strokes in hemolytic-uremic syndrome. *J. Pediatr.*, **111**, 863-866.
- Upadhyaya, K., Barwick, K., Fishaut, M., Kashgarian, M. & Siegel, N.J. (1980) The importance of nonrenal involvement in hemolytic-uremic syndrome. *Pediatrics*, **65**, 115-120.