

Musical Hallucinations Associated With Seizures Originating From an Intracranial Aneurysm

DANIEL L. ROBERTS, MD; USHA TATINI, MD; RICHARD S. ZIMMERMAN, MD; JENNIFER J. BORTZ, PhD; AND JOSEPH I. SIRVEN, MD

Hallucinations are defined as sensory phenomena in the absence of external sensory stimuli. Auditory hallucinations have been shown to arise from many different intracranial lesions, but seizures manifesting as musical hallucinations triggered by unruptured intracranial aneurysms are rare. We present a case of persistent, episodic musical hallucinations associated with seizures that led to the discovery of 2 small intracranial aneurysms. Typical electro-

encephalographic findings for seizure activity were observed but resolved after surgical clipping of the aneurysms. Concomitantly, the patient's hallucinations resolved. The literature on musical hallucinations is reviewed.

Mayo Clin Proc. 2001;76:423-426

ECoG = electrocorticography; ICA = internal carotid artery; MRI = magnetic resonance imaging

The work-up of patients with hallucinations, especially auditory hallucinations, can be complicated and often confusing because inner ear disease is a possible cause as are psychiatric disorders, particularly schizophrenia. Musical hallucinations attributable to a discrete intracranial focus are rare. A thorough history, physical examination, neuropsychological testing, and neuroimaging may lead to the identification of a treatable cause. We describe a patient whose musical hallucinations were shown to be associated with seizures originating from an unruptured intracranial aneurysm, which was surgically corrected.

REPORT OF A CASE

A 61-year-old right-handed woman presented with a 2-year history of spells and a 1-year history of musical hallucinations. Her symptoms initially began as episodes of nausea, fatigue, and disorientation that arose without warning and lasted several minutes. She did not lose consciousness or experience stereotyped movements. One year before presentation, during hospitalization for pneumonia, she noticed tinnitus. After the patient was discharged, tinnitus became a persistent, episodic, and bilateral hallucination of music that she recognized but could not control voluntarily. The music had a seasonal variation; she heard Christmas

music during the month of December. Other times, the music had religious overtones (eg, "Amazing Grace").

The patient's medical history was notable for an isolated seizure of unknown cause 27 years previously, hyperlipidemia, and a graft of the right jaw bone. Her only medication was cerivastatin. She had no history of hearing loss or psychiatric illness. Before presentation at our institution, she had been evaluated by an audiologist for tinnitus, but no abnormality was noted. Findings on magnetic resonance imaging (MRI) of the brain had been interpreted as normal.

The patient sought psychiatric help for the hallucinations but received no diagnosis. She then sought evaluation at our institution. On initial physical examination, the patient was pleasant, alert, and in no acute distress. A thorough neurologic examination showed no abnormalities of motor or sensory function, cranial nerves, reflexes, balance, gait, speech, or mental status. Findings on the rest of the examination were otherwise normal.

Repeated MRI with use of thin cuts of the brain revealed a tiny area of enhancement in the right uncus with a small amount of increased signal on T2-weighted imaging, suggesting an unruptured aneurysm with surrounding edema or gliosis (Figure 1). No hippocampal atrophy or mesial temporal sclerosis was noted. At that time, video electroencephalographic monitoring showed no scalp changes. Cerebral angiography revealed 2 right-sided 5-mm saccular aneurysms arising from the anterior choroidal artery and proximal anterior cerebral artery (Figure 2). The former projected directly into the uncus. Memory and language testing was performed. Each internal carotid artery (ICA) was injected with 125 mg of amobarbital sodium 30 minutes apart. The patient reported cessation of music after injection into the right ICA and resumption of music after

From the Division of Community Internal Medicine (D.L.R.), Division of Regional and International Medicine (U.T.), Department of Neurologic Surgery (R.S.Z.), Department of Psychiatry and Psychology (J.J.B.), and Department of Neurology (J.I.S.), Mayo Clinic, Scottsdale, Ariz.

Individual reprints of this article are not available. Address correspondence to Daniel L. Roberts, MD, Division of Community Internal Medicine, Mayo Clinic, 13400 E Shea Blvd, Scottsdale, AZ 85259 (e-mail: roberts.daniel@mayo.edu).

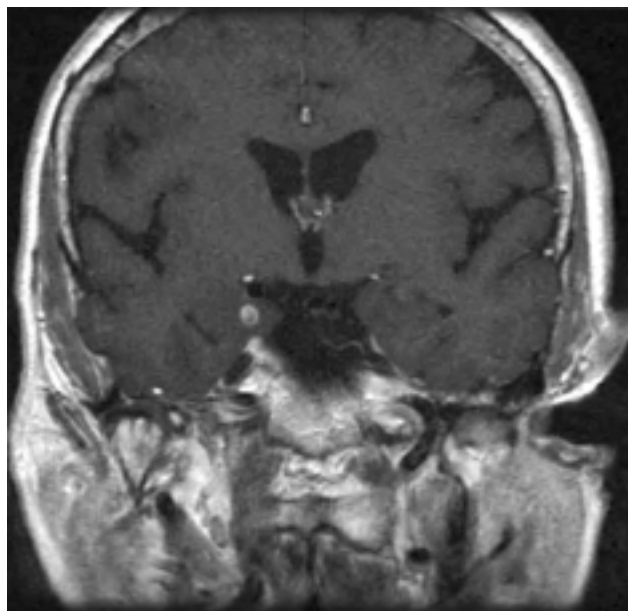


Figure 1. Magnetic resonance image of the brain shows a small focus of enhancement in the right uncus with a small amount of surrounding edema.

return of left upper extremity strength. This effect was not observed with left ICA injection. The patient was found to be left hemisphere–dominant for language.

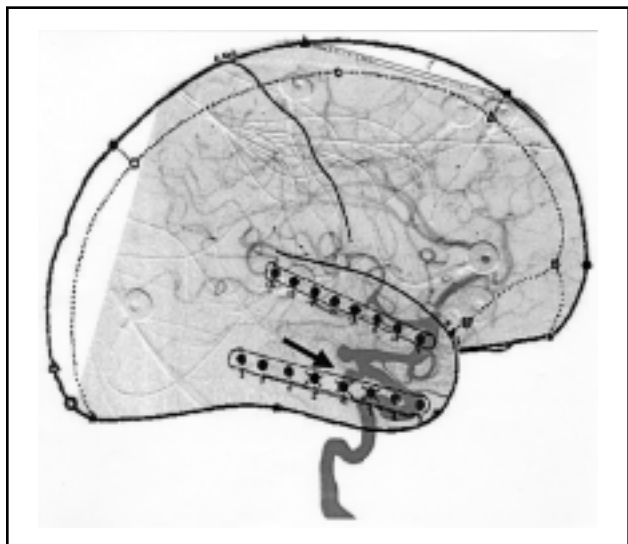


Figure 3. Electrocohortography (ECoG) map with 2 eight-contact strip electrodes shows placement of the electrodes in relation to the aneurysms. This map of the brain represents a cortical diagram with the superimposed lateral cerebral angiogram. The Xs on the strip represent the area of spike discharges. Note that the offending aneurysm (arrow) was mesially located and that the ECoG map is a 2-dimensional representation of 3-dimensional anatomy.

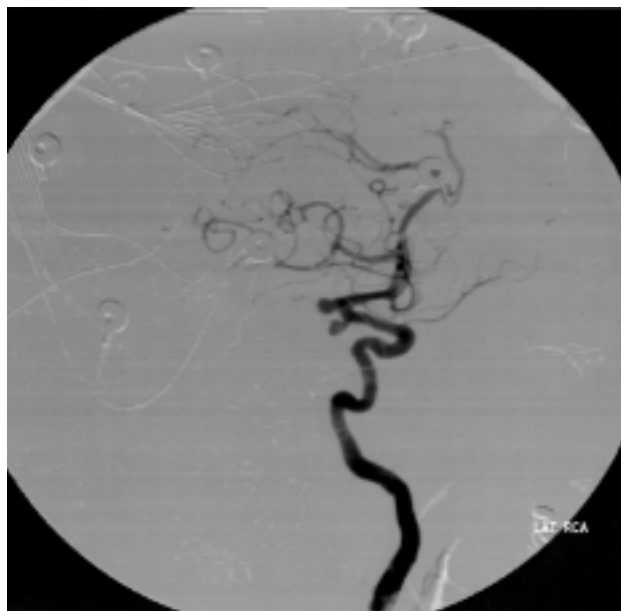


Figure 2. Cerebral angiogram shows a 5-mm aneurysm arising from the anterior choroidal artery and a 5-mm aneurysm arising at the bifurcation of the internal carotid artery. LAT RCA = lateral right carotid artery.

The patient was scheduled for surgical clipping of the aneurysms. As part of this procedure, intraoperative electrocorticography (ECoG) was performed over the area of the aneurysms; spike discharges were evident (Figure 3). After successful clipping of the aneurysms with small focal resection of the surrounding uncus, repeated ECoG showed normalization of the spike discharges (Figure 4). On awakening and recovering, the patient noted cessation of the musical hallucinations.

DISCUSSION

Auditory hallucinations range from simple tinnitus to unformed hallucinations (simple repeated sounds) to formed hallucinations (highly complex series of sounds); musical hallucinations are rare. Most reported cases have been noted in elderly women with hearing loss, although psychiatric illness is a known association. True central nervous system sources include intracerebral hemorrhages,¹ neoplasms,² arteriovenous malformations,³ and rhombencephalitis.⁴ Several drugs have been proposed to induce musical hallucinations, including tricyclic antidepressants,⁵ triazolam,⁶ propranolol,⁷ salicylates,⁸ clomipramine,⁹ and pentoxifylline.¹⁰ Our patient's musical hallucinations were due to an unruptured aneurysm in the right uncus.

Although case reports have described musical hallucinations, seizures manifested as auditory hallucinations have been reported infrequently; musical hallucinations

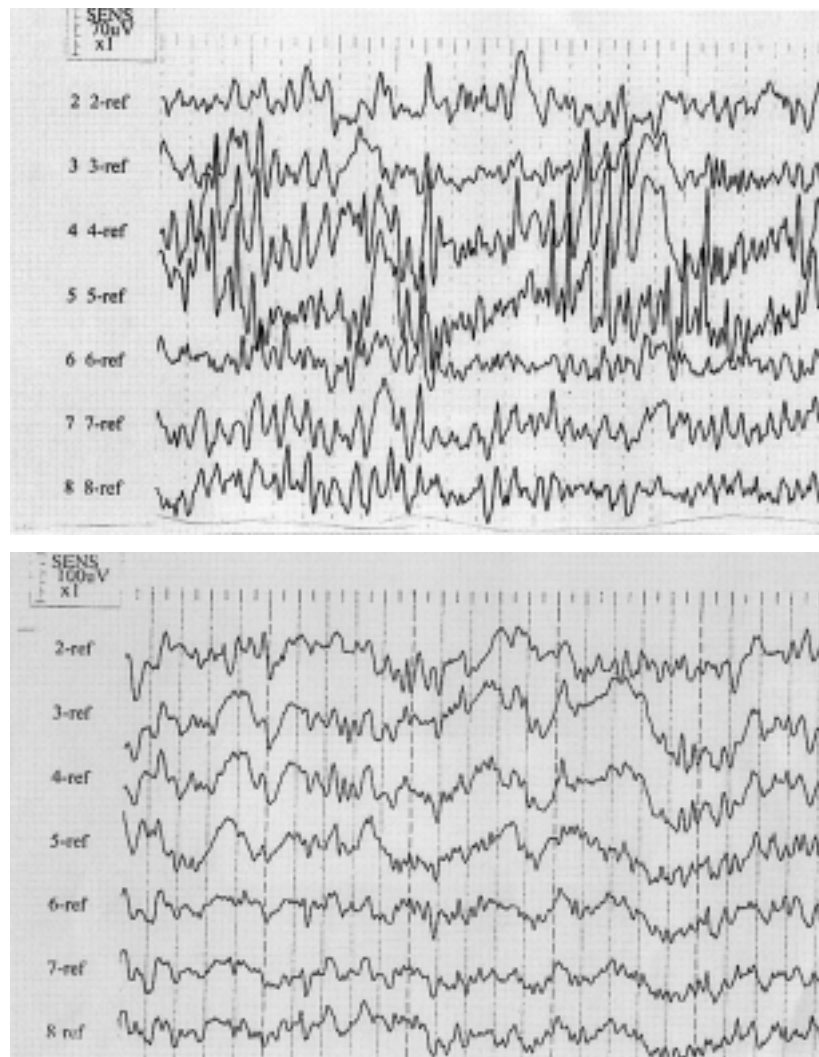


Figure 4. Electrocorticography (ECoG) before (upper) and after (lower) clipping of aneurysms and focal resection of the surrounding uncus. Note the high amplitude rhythmic spike discharges on contacts 3, 4, and 5 before resection and their absence after resection. The ECoG was performed while the patient was anesthetized with propofol.

originating from a seizure are rare. Fish¹¹ classified musical hallucinations with other “psychic seizures,” seizures that tend to have a strong affective component, connect with elements of the patient’s distant memory, and localize almost exclusively to the temporal lobes. Our patient’s seizures fulfilled this description; her hallucinations were of music that she had learned at a young age and that had a religious or seasonal meaning. Intraoperative ECoG localized her seizures to the nondominant right temporal lobe.

Provenzale et al¹² reported seizure activity associated with unruptured intracerebral aneurysms. They observed that an increased signal on T2-weighted imaging around

the aneurysm site on MRI may be associated with an increased predilection for epileptogenesis. In our patient, MRI showed an increased T2 signal at the site of the aneurysms. Provenzale et al further noted that their literature review produced no epileptogenic aneurysms that were smaller than 1 cm in diameter. Our patient’s offending aneurysm was approximately half that size.

Functional neuroimaging techniques provide preliminary evidence of an association between auditory hallucinations and temporal lobe changes in regional glucose uptake, as measured by positron emission tomography.¹³ Similarly, functional MRI “symptom capture” protocols

suggest a relationship between auditory hallucinations and altered neuronal activation.¹⁴

Establishing cogent theories about the mechanism or mechanisms of musical hallucinations has been difficult and controversial because of the lack of consensus about the neurologic pathways that mediate musical processing. Berrios¹⁵ states that central nervous system hallucinations arise from the nondominant hemisphere, consistent with the known localization of musical function on this side of the brain. However, Gordon¹⁶ disputes the existence of true central nervous system musical hallucinations. Although Gordon allows for the possibility of epilepsy, our case seems to support the viewpoint of Berrios.

REFERENCES

1. Murata S, Naritomi H, Sawada T. Musical auditory hallucinations caused by a brainstem lesion. *Neurology*. 1994;44:156-158.
2. Nagaratnam N, Virk S, Brdarevic O. Musical hallucinations associated with recurrence of a right occipital meningioma. *Br J Clin Pract*. 1996;50:56-57.
3. Cascino GD, Adams RD. Brainstem auditory hallucinosis. *Neurology*. 1986;36:1042-1047.
4. Douen AG, Bourque PR. Musical auditory hallucinosis from Listeria rhombencephalitis. *Can J Neurol Sci*. 1997;24:70-72.
5. Terao T. Tricyclic-induced musical hallucinations and states of relative sensory deprivation. *Biol Psychiatry*. 1995;38:192-193.
6. Nevins MA. Musical hallucinations and triazolam use. *N J Med*. 1991;88:907-908.
7. Fernandez A, Crowther TR, Vieweg WV. Musical hallucinations induced by propranolol. *J Nerv Ment Dis*. 1998;186:192-194.
8. Allen JR. Salicylate-induced musical perceptions [letter]. *N Engl J Med*. 1985;313:642-643.
9. Vallada HP, Gentil V. Musical hallucinations triggered by clomipramine? [letter]. *Br J Psychiatry*. 1991;159:888-889.
10. Gilbert GJ. Pentoxifylline-induced musical hallucinations. *Neurology*. 1993;43:1621-1622.
11. Fish DR. Psychic seizures. In: Engel J Jr, Pedley TA, Aicardi J, eds. *Epilepsy: A Comprehensive Textbook*. Vol 1. Philadelphia, Pa: Lippincott-Raven Publishers; 1998:543-548.
12. Provenzale JM, Gorecki JP, Koen JL. Cerebral aneurysms associated with seizures but without clinical signs of rupture: seemingly distinctive MR imaging findings in two patients. *AJR Am J Roentgenol*. 1996;167:230-232.
13. Cleghorn JM, Franco S, Szechtman B, et al. Toward a brain map of auditory hallucinations. *Am J Psychiatry*. 1992;149:1062-1069.
14. Woodruff PW, Wright IC, Bullmore ET, et al. Auditory hallucinations and the temporal cortical response to speech in schizophrenia: a functional magnetic resonance imaging study. *Am J Psychiatry*. 1997;154:1676-1682.
15. Berrios GE. Musical hallucinations: a historical and clinical study. *Br J Psychiatry*. 1990;156:188-194.
16. Gordon AG. Do musical hallucinations always arise from the inner ear? *Med Hypotheses*. 1997;49:111-122.

