

Mycotic Aneurysm of the Carotid Bifurcation in the Neck: Case Report and Review of the Literature

Remi Nader, M.D., Gérard Mohr, M.D.,
Nathan M. Sheiner, M.D., Donatella Tampieri, M.D.,
Jack Mendelson, M.D., Steffen Albrecht, M.D.

Departments of Neurosurgery (RN, GM), Vascular Surgery (NMS), Neuroradiology (DT), Infectious Diseases (JM), and Pathology (SA), Sir Mortimer B. Davis-Jewish General Hospital and Montreal Neurological Hospital (DT), McGill University, Montreal, Quebec, Canada

OBJECTIVE AND IMPORTANCE: Mycotic aneurysms of the extracranial carotid artery are rare and difficult to diagnose. A search of the world literature published since 1966 reveals at least six cases of mycotic carotid aneurysms due to a *Salmonella* septicemia. We present an exceptional case of mycotic pseudoaneurysm of the bifurcation of the carotid artery due to *Salmonella* septicemia and discuss the pathogenesis as well as various aspects of the diagnosis and surgical management.

CLINICAL PRESENTATION: A 68-year-old man presented in Poland with *Salmonella* sepsis; 1 month later, he was admitted to the emergency department of the Sir Mortimer B. Davis-Jewish General Hospital in Montreal with a bulky and pulsatile right cervical mass. An angiogram and a computed tomographic scan revealed a voluminous and partially thrombosed aneurysm the size of a tangerine originating from the posterior aspect of the carotid junction.

INTERVENTION: Balloon trapping was attempted at the Montreal Neurological Hospital. Subsequently, the patient developed a significant neurological deficit, which was quickly reversed by the administration of hypertensive, hypervolemic, and hemodilution therapy. Thereafter, the pseudoaneurysm was resected surgically, and the internal and external carotid arteries were sacrificed. Pathological examination of the excised specimen of the carotid junction revealed a pseudoaneurysm. Bacterial culture of the lesion showed growth of *Salmonella*.

CONCLUSION: The postoperative course was satisfactory except for laryngeal paralysis due to involvement of the vagus nerve. Four months later, a computed tomographic scan showed only small lacunae in both centrum semiovale. (Neurosurgery 48:1152–1156, 2001)

Key words: Carotid artery, Carotid bifurcation, Mycotic pseudoaneurysm, *Salmonella*

Mycotic aneurysms of the extracranial carotid artery (ECA) are rare and difficult to diagnose. A literature review of publications during the period 1966 to 2000 identified about 45 reported cases. The organism most fre-

quently mentioned as a cause of these aneurysms is *Staphylococcus*, but other organisms, such as *Streptococcus*, *Klebsiella*, *Escherichia coli*, and *Salmonella* (12), can also cause this lesion. We present an exceptional case caused by *Salmonella*

arteritis and discuss the pathogenesis as well as various aspects of the diagnosis and surgical management.

CASE REPORT

A 68-year-old man presented in Poland with *Salmonella* sepsis. One month later, he was admitted to the emergency department of the Sir Mortimer B. Davis-Jewish General Hospital in Montreal with a bulky, pulsatile, and tender right cervical mass. He had a temperature of about 39°C and had been somewhat confused and somnolent during the past few weeks. He had no shortness of breath, dysphagia, hoarseness, chest pain, or palpitations. Blood cultures obtained at the time of admission were positive for *Salmonella* species. He underwent gastroscopy and biopsy for melena and anemia, and these tests revealed mild to moderate chronic gastritis. The patient was placed on a regimen of intravenously administered ampicillin for 10 days. A computed tomographic scan of the neck obtained 4 days after admission revealed a 4 × 4.5-cm rim-enhancing and partially thrombosed mass originating from the posterior aspect of the carotid bifurcation (Fig. 1). A significant hypodense component was present within the mass. A focus of hyperdense enhancement measuring 2 cm in length was seen to connect to the right common carotid artery (CCA), which seemed to course through the mass. Extensive inflammatory changes surrounding the lesion were noted. Angiography revealed an extraluminal irregularly shaped collection extending from the medial wall of the right internal carotid artery (ICA) near the carotid bifurcation and measuring 1.5 × 1.0 cm, representing either an aneurysm or a pseudoaneurysm (Fig. 2).

The patient was transferred to the Montreal Neurological Hospital for an attempt at balloon trapping. The original therapeutic plan was to trap the pseudoaneurysm between two balloons, after ensuring patent contralateral flow to the peripheral branches of the right ICA via the circle of Willis by means of balloon test occlusion (Fig. 3). Retro-

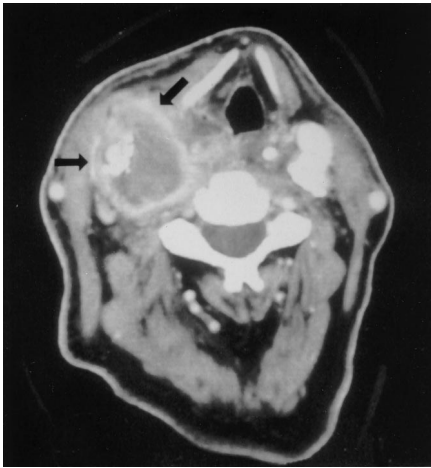


FIGURE 1. Computed tomographic scan of the neck showing a 4- × 4.5-cm rim-enhancing lesion originating from the posteromedial aspect of the carotid bifurcation (arrows). The hypodense peripheral component represents thrombosed blood, and the hyperdense center (2 cm) represents fresh blood. Significant inflammation surrounds the mass.

grade flow would be expected to occur in the right ECA through anastomosis of the right ophthalmic artery to the ECA. The following stage of the plan would be to excise the well-isolated pseudoaneurysm surgically.

Balloon test occlusion was performed with an Endeavor 0.5-ml balloon (Boston Scientific/Medi-Tech, Natick, MA), which was navigated in a 7.3-French system and positioned in the distal cervical portion of the right ICA just before the level of the kinking. The balloon was inflated for 30 minutes. During this time, the patient underwent an electroencephalogram and a neurological examination; the results of both of these examinations were within normal limits. The patient also underwent angiography of the right CCA, left ICA, and dominant left vertebral artery during this time. The right CCA demonstrated complete occlusion, and there was evidence of contralateral flow to the right side via the anterior communicating artery (Fig. 4). Right CCA balloon occlusion was then performed with one No. 19 Goldvalve balloon (Nycomed, Paris, France) navigated to the ICA and two No. 16 Goldvalve balloons placed in the

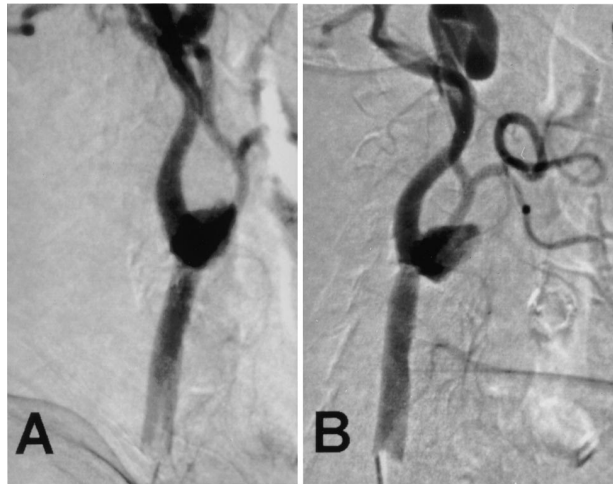

FIGURE 2. Right carotid angiogram (A, lateral view; B, anteroposterior view) showing an extraluminal filling defect originating from the medial wall of the right ICA near the carotid bifurcation and measuring 1.5 × 1 cm.

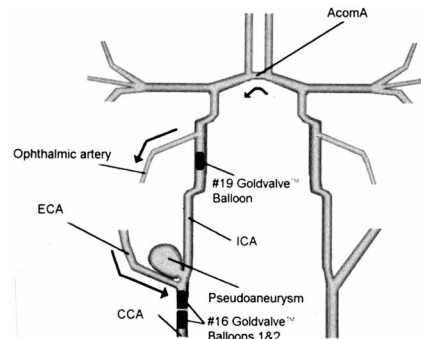


FIGURE 3. Outline of the initially planned procedure, showing balloon trapping of the pseudoaneurysm as well as contralateral flow to the aneurysm from the ECA via the circle of Willis. *AcomA*, anterior communicating artery.

CCA near the carotid bifurcation (Fig. 5). During the next 24 hours, the patient developed significant neurological deficits, including facial asymmetry, left-sided lack of response to spatial stimuli (“neglect”), and weakness of the left upper and lower extremities. After administration of hypertensive, hypervolemic, and hemodilution (“triple-H”) therapy, he had a quick reversal in his neurological deficit with no cerebral infarction.

The patient underwent surgical resection of the mass 48 hours after the angiographic procedure because of the persistence of pulsations in the neck. All pulsations in the aneurysm ceased after dissection and temporary cross-clamping of the CCA were performed. Intense inflammation was noted around the angle of the mandible and inferiorly in relation to the CCA and internal jugular vein.

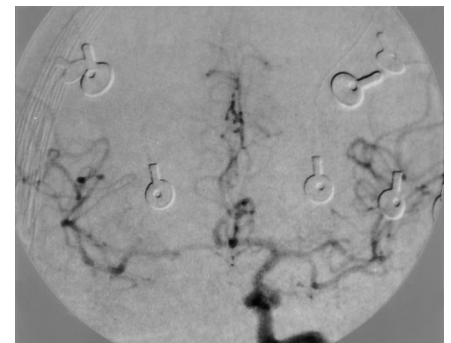


FIGURE 4. Balloon test occlusion angiogram demonstrating contralateral flow through the anterior communicating artery via the left ICA, after occlusion of the right ICA.

Complete division of the blood supply to the mass was performed by isolating and ligating the CCA, the ICA, and the ECA. The internal jugular vein was intimately adherent to the large mass; it was likewise divided and left attached to the mass. Several enlarged lymph nodes were resected. It was difficult to define the vagus nerve, as it appeared to be caught in the inflammatory mass. The mass, which was then dissected out, appeared to partly extend into the muscular layer of the pharynx and superiorly up to the base of the cranium. The incision was copiously irrigated in antibiotic solution and closed in layers. The patient tolerated the operative procedure well and, upon awakening, was able to move all extremities.

The pathological examination of the excised specimen revealed a defect in the wall at the posterior aspect of the junction between the CCA and ICA. The

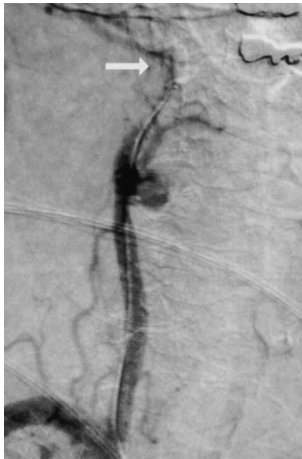

FIGURE 5. Angiogram performed during the balloon occlusion procedure showing No. 19 Goldvalve balloon at the level of the ICA, distal to the pseudoaneurysm (arrow). Note that neither of the two No. 16 Goldvalve balloons is visualized, as they were placed after this angiogram was obtained.

defect was filled with friable debris and measured 0.4 cm in diameter. Attached to this was a cystic nodule of soft tissue and recent blood clot measuring 2.5 cm in greatest diameter with a central cavity of 1.5 cm (Fig. 6). Histological examination of the pseudoaneurysm revealed severe chronic inflammation associated with abscess and soft tissue hemorrhage (Fig. 7). The final diagnosis was that of a pseudoaneurysm of the posterior wall of the carotid bifurcation. Gram stains of part of the specimen did not show convincingly any causal organism, but a

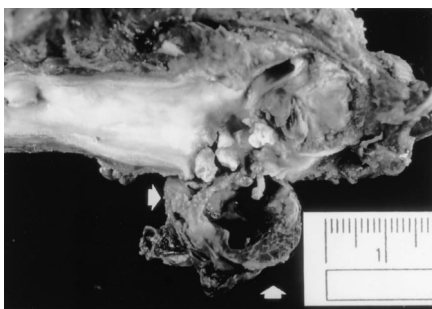


FIGURE 6. Gross pathological specimen showing cystic nodule (arrows) with soft tissue demonstrating significant inflammation and hemorrhage. The wall defect (ostium of the pseudoaneurysm) filled with friable debris is also seen.

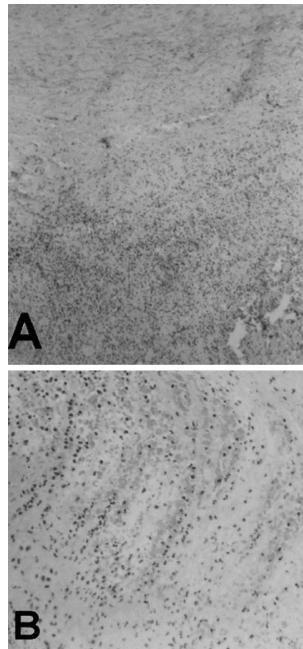


FIGURE 7. Histopathology of the pseudoaneurysm showing severe chronic inflammation (A) as well as abscess and soft tissue hemorrhage (B).

bacterial culture of the lesion revealed the growth of *Salmonella*.

The postoperative course was satisfactory except for laryngeal paralysis, which was due to involvement of the vagus nerve. A computed tomographic scan obtained 4 months later showed only small lacunae in the centrum semiovale on each side. Because of his hoarseness, the patient will soon undergo a reconstructive procedure with implantation of a prosthesis in his thyroid cartilage.

DISCUSSION

Mycotic aneurysms of the ECA are very rare lesions. A review of the world literature published between 1966 and 2000 reveals about 45 reported cases. Jebara et al. (12) reviewed 27 cases of mycotic aneurysms of the ECA reported from 1966 to 1992. At least 18 new cases have been published as case reports between 1992 and 2000 (2, 4, 5, 8, 10, 13–17, 19–21, 23, 24, 26–28). Only six cases were proved to be caused by *Salmonella* infection (4, 6, 7, 16, 24, 25).

The introduction of antibiotics significantly decreased the incidence of mycotic aneurysms (16). Common organ-

isms causing mycotic aneurysms before the antibiotic era included *Streptococcus pyogenes* (7, 20), *Treponema pallidum*, and *Mycobacterium tuberculosis* (12, 16). Today, the most frequent causative agent is believed to be *Staphylococcus aureus* (7, 12, 16, 20). Aneurysms caused by *Streptococcus*, *Salmonella*, *Klebsiella*, *Escherichia coli*, *Proteus mirabilis*, *Corynebacterium*, and *Yersinia enterocolitica* (7, 12, 16, 20) have also been reported.

Salmonella has been reported to cause multiple mycotic aneurysms as well as organ abscesses (16). The most common *Salmonella* species involved are *S. choleraesuis* and *S. enterica* subspecies *enteritidis* (3, 16). The majority of *Salmonella* arterial infections arise in atherosclerotic infrarenal aortic aneurysms (3). Other frequent sites of infection include the thoracic aorta, coronary arteries, peripheral arteries, and arteriovenous fistulae (3). Mechanisms of pathogenesis may include postoperative infection, septicemia with invasion of the vasa vasorum, contiguous site of infection, iatrogenic introduction of bacteria through catheterization, dental sepsis, intravenous drug use, bacterial endocarditis, and penetrating neck wounds (7, 8, 12, 20). Given the histological appearance in the case described in this report, two possible mechanisms can be considered. A primary endovascular infection, possibly of an atheromatous plaque, with secondary perforation and abscess formation in the surrounding soft tissue, may have occurred. Alternatively, the abscess may have been the primary lesion that secondarily eroded the artery.

The mycotic aneurysm most commonly presents as a growing, pulsatile cervical mass in the lateral aspect of the neck (7, 12, 16). Pain, tenderness, fever, dysphonia, or dysphagia (7, 12) may be associated with the aneurysm. If untreated, the aneurysm may rupture or send septic emboli to the brain (16). The differential diagnosis includes carotid body tumor, carotid artery kinking and redundancy, enlarging cervical lymphadenitis, and peritonsillar abscess (7, 20). Diagnosis is usually confirmed with duplex ultrasound scanning, a noninvasive technique, or with arteriography, which is more invasive but precise and enables accurate visualization of the

anatomy as well as the collateral flow (7, 12, 20).

Management consists of the use of systemic antibiotics, surgical carotid artery resection, and placement of a graft to restore vascular continuity (7, 12, 16, 20). The graft may be taken from the saphenous vein, jugular vein, or internal iliac artery (7, 8, 12, 20). Autologous reconstruction, associated with a mortality rate of 7%, remains the primarily used method, with the saphenous vein as the graft of choice (12, 16). Heterologous or prosthetic grafts are not recommended because of the high risk of infection (12, 20). Alternative surgical approaches include end-to-end anastomosis and ligation of the carotid artery proximal to the aneurysm (7, 12). Carotid ligation, which was more commonly used in the past, carries a mortality risk of 25 to 60% and is considered in cases in which revascularization is impossible or contralateral flow via the ICA can be demonstrated (12, 16, 20), as in the case described here.

Endovascular stenting or occlusion may offer interesting and less invasive therapeutic alternatives (9, 22). Such techniques have commonly been reported in cases of traumatic or atherosclerotic pseudoaneurysms. Both endovascular procedures allow preservation of the CCA and are significantly less time consuming than conventional bypass procedures (1). Covered and non-covered stents, as well as endovascular coils, have been used in patients with pseudoaneurysms and aneurysms of the carotid artery (1, 9, 11, 18). Stents are not without complications; they may require lifelong anticoagulation, may kink or become deformed, or may result in neointimal hyperplasia (18). Another approach, described by Marotta et al. (18), is based on the use of a stent covered with saphenous vein. The rationale behind this technique is rapid complete occlusion of the pseudoaneurysm without the need to use a coil and risk wall rupture. In the case presented in this report, our initial therapeutic plan of endovascular occlusion may have been theoretically realizable, given the presence of contralateral flow through the anterior communicating artery, as demonstrated by angiography. However some difficulties were encountered

while the balloons were being navigated, possibly owing to the relatively large size of the pseudoaneurysm or to instability of the arterial wall. The temporary neurological deficit that was observed may have been attributable to either rupture of emboli from the distal ICA upon balloon inflation or to rapid hypoperfusion of the right hemisphere upon ICA occlusion. Nevertheless, the patient was taken on an urgent basis, 48 hours later, to the operating room for definitive treatment by carotid ligation. The patient did very well postoperatively, and the follow-up examination disclosed minimal residual deficit.

CONCLUSION

In conclusion, mycotic aneurysms of the ECA are very rare lesions. Our report of a case caused by *Salmonella* is exceptional, as only six such cases have been reported since 1966. The aneurysms usually present as enlarging, pulsatile neck masses and are commonly associated with generalized sepsis. The most accurate diagnostic procedure remains angiography. Management is primarily surgical. Several options are available, including aneurysm excision and use of an autologous graft for revascularization, carotid artery ligation, end-to-end anastomosis, and endovascular stenting, occlusion, and coiling.

Received, August 4, 2000.

Accepted, November 14, 2000.

Reprint requests: Gérard Mohr, M.D., Department of Neurosurgery, McGill University, 3755 Cote Ste-Catherine, Montreal, Quebec, Canada H3T 1E2. Email: gmohr@neu.jgh.mcgill.ca

REFERENCES

1. Bejjani GK, Monsein LH, Laird JR, Satler LF, Starnes BW, Aulisi EF: Treatment of symptomatic cervical carotid dissections with endovascular stents. *Neurosurgery* 44:755-761, 1999.
2. Buerger T, Meyer F, Halloul Z: Ruptured cervical aneurysm of the carotid artery: Case report of a rare disease. *Vasa* 27:122-124, 1998.
3. Cohen JJ, Bartlett JA, Corey GR: Extra-intestinal manifestations of salmonella infections. *Medicine (Baltimore)* 66:349-388, 1987.
4. Dawson KJ, Stansby G, Novell JR, Hamilton G: Mycotic aneurysm of the cervical carotid artery due to *Salmonella* enteritidis. *Eur J Vasc Surg* 6:327-329, 1992.
5. Desimpelaere J, Seynaeve P, Kockx M, Appel B, Gyselincx J, Mortelmans L: Mycotic pseudoaneurysm of the extracranial carotid artery. *J Belge Radiol* 80:170-171, 1997.
6. Farah I, Magne JL, Guinard D, Guidicelli H: Aneurysme infectieux carotidien compliqué d'une rupture: Problèmes diagnostiques et thérapeutiques. *Lyon Chir* 85:109-111, 1989.
7. Grossi RJ, Onofrey D, Tvetenstrand C, Blumenthal J: Mycotic carotid aneurysm. *J Vasc Surg* 6:81-83, 1987.
8. Heyd J, Yinnon AM: Mycotic aneurysm of the external carotid artery. *J Cardiovasc Surg* 35:329-331, 1994.
9. Hosoda K, Fujita S, Kawaguchi T, Shibata Y, Tamaki N: The use of an external-internal shunt in the treatment of extracranial internal carotid artery saccular aneurysms: Technical case report. *Surg Neurol* 52:153-155, 1999.
10. Hubaut JJ, Albat B, Frapier JM, Chaptal PA: Mycotic aneurysm of the extracranial carotid artery: An uncommon complication of bacterial endocarditis. *Ann Vasc Surg* 11:634-636, 1997.
11. Hurst RW, Haskal ZJ, Zager E, Bagley LJ, Flamm ES: Endovascular stent treatment of cervical internal carotid artery aneurysms with parent vessel preservation. *Surg Neurol* 50:313-317, 1998.
12. Jebara VA, Acar C, Dervanian P, Chachques JC, Bischoff N, Uva MS, Julia P, Deloche A, Fabiani JN, Carpentier A: Mycotic aneurysms of the carotid arteries: Case report and review of the literature. *J Vasc Surg* 14:215-219, 1991.
13. Kato T, Oto K, Endo T, Furusho J, Iwasaki A, Sasaki Y, Iikura Y: Microbial extracranial aneurysm of the internal carotid artery: Complication of cervical lymphadenitis. *Ann Otol Rhinol Laryngol* 108:314-317, 1999.
14. Khalil I, Nawfal G: Mycotic aneurysms of the carotid artery: Ligation vs. reconstruction—Case report and review of the literature. *Eur J Vasc Surg* 7:588-591, 1993.
15. Llorente A, Bronte E, Ramos G, Carpintero M, Gimenez C: Cervical epidural anesthesia for carotid mycotic aneurysms [in Spanish]. *Rev Esp Anestesiol Reanim* 42:341-343, 1995.
16. Lloret MD, Escudero JR, Hospedales J, Viver E: Mycotic aneurysm of the carotid artery due to *Salmonella* enteritidis associated with multiple brain abscesses. *Eur J Vasc Endovasc Surg* 12:250-252, 1996.
17. Lueg EA, Awerbuck D, Forte V: Ligation of the common carotid artery for the management of a mycotic pseudoaneurysm of an extracranial internal carotid artery: A case report and review of the literature. *Int J Pediatr Otorhinolaryngol* 33:67-74, 1995.
18. Marotta TR, Buller C, Taylor D, Morris C, Zwimpfer T: Autologous vein-covered stent repair of a cervical internal carotid artery pseudoaneurysm: Technical case report. *Neurosurgery* 42:408-413, 1998.
19. Michielsen D, Van Hee R, Discart H: Mycotic aneurysm of the carotid artery: A case report and review of the literature. *Acta Chir Belg* 97:44-46, 1997.
20. Naik DK, Atkinson NR, Field PL, Milne PY: Mycotic cervical carotid aneurysm. *Aust N Z J Surg* 65:620-621, 1995.

21. Regina G, Fullone M, Impedovo G, Testini M, Greco L, Plantamura M, Ciavarella M, De Robertis C, Magistro G, D'Amely P: Mycotic aneurysm of the carotid artery [in Italian]. *Minerva Cardioangiol* 46:282-283, 1998.
22. Reisner A, Marshall GS, Bryant K, Postel GC, Eberly SM: Endovascular occlusion of a carotid pseudoaneurysm complicating deep neck space infection in a child: Case report. *J Neurosurg* 91:510-514, 1999.
23. Remy P, Massin H, Blampain JP: Bacterial aneurysm of the internal carotid: A rare condition. *Eur J Vasc Surg* 8:524-526, 1994.
24. Rice HE, Arbabi S, Kremer R, Needle D, Johansen K: Ruptured Salmonella mycotic aneurysm of the extracranial carotid artery. *Ann Vasc Surg* 11:416-419, 1997.
25. Sandmann W, Hennerici M, Aulich A, Kniemeyer H, Kremer KW: Progress in carotid artery surgery at the base of the skull. *J Vasc Surg* 1:734-743, 1984.
26. Wells RG, Sty JR: Cervical lymphadenitis complicated by mycotic carotid artery aneurysm. *Pediatr Radiol* 21:402-403, 1991.
27. Willemssen P, De Roover D, Kockx M, Gerard Y: Mycotic common carotid artery aneurysm in an immunosuppressed pediatric patient: Case report. *J Vasc Surg* 25:784-785, 1997.
28. Worley GA, Hern JD, O'Sullivan GJ, Tassone P, Hinton AE: Mycotic aneurysm of the external carotid artery. *J Laryngol Otol* 112:793-795, 1998.

COMMENTS

Nader et al. have presented an entity that I have never seen (and most of us probably will never encounter), an infectious pseudoaneurysm at the cervical carotid bifurcation. Their case is beautifully documented radiographically and

clinically. They obtained a successful outcome for the patient.

I have a question regarding the management strategy of what is, admittedly, a very difficult case. I am curious why the authors did not perform a reconstruction procedure with saphenous vein rather than simply ligation of the artery in a patient who had a neurological deficit from carotid occlusion that was responsive only to triple-H therapy. Certainly, they had access to and control of all three major branches before the mass was resected. The patient had a successful outcome and was well treated, but I think I would have been worried that, with the inevitable cessation of triple-H therapy, a neurological deficit might have recurred. This is a small point, however. The authors successfully treated an entity that most of us will never face and most likely would approach with great caution if it were to appear on our doorstep.

Christopher M. Loftus
Oklahoma City, Oklahoma

Nader et al. have presented a rare case of mycotic aneurysm of the carotid artery in the neck. In the United States, most aneurysms in the extracranial vessels are attributable to trauma or penetrating injuries, and those caused by infection have become a rare entity. This case report adds to the literature and

emphasizes the findings and management for these uncommon lesions. My personal bias would be to consider saphenous vein bypass grafting initially, particularly for a younger patient.

Anil Nanda
Shreveport, Louisiana

In this report, the authors describe the surgical management of an infectious pseudoaneurysm of the carotid bifurcation in the neck. Balloon test occlusion without hypotensive challenge did not predict a resulting hemiparesis that occurred after complete trapping of the lesion with balloons placed in the internal carotid and common carotid arteries. The deficit resolved with hypertensive therapy, allowing definitive surgical resection of the infectious aneurysm 48 hours later. Although we agree in principle with the authors' approach, in recent years we have used a hypotensive challenge with balloon test occlusion, as that technique seems to be a more accurate predictor of deficit after permanent balloon occlusion. Revascularization options in the setting of a widely infected carotid bifurcation would involve long vein grafting from the more proximal common carotid artery.

Bob S. Carter
Christopher S. Ogilvy
Boston, Massachusetts



Early Sunday Morning (1930), by Edward Hopper. Oil on canvas. Courtesy, Whitney Museum of American Art, New York, New York.