

## Embolization of Arteriovenous Malformations with Onyx: Clinicopathological Experience in 23 Patients

Reza Jahan, M.D., Yuichi Murayama, M.D.,  
Y. Pierre Gobin, M.D., Gary R. Duckwiler, M.D.,  
Harry V. Vinters, M.D., Fernando Viñuela, M.D.

Division of Interventional Neuroradiology (RJ, YM, YPG, GRD, FV), Department of Radiological Sciences, and Section of Neuropathology (HVV), Department of Pathology and Laboratory Medicine and Brain Research Institute, University of California at Los Angeles School of Medicine, Los Angeles, California

**OBJECTIVE:** To report our experience in treatment of arteriovenous malformations (AVMs) using a new liquid embolic agent, Onyx (Micro Therapeutics, Inc., Irvine, CA).

**METHODS:** Between January 1998 and May 1999, 23 patients (8 men and 15 women) were treated. The patients' average age was 40 years, with seizure being the most common presenting symptom (39%). The average Spetzler-Martin grade on presentation was 3. The average AVM volume before embolization was 14.5 cm<sup>3</sup>.

**RESULTS:** We observed an average 63% reduction in AVM volume after 129 arterial feeders were embolized. There were four adverse events. Two patients experienced ischemia because of inadvertent occlusion of an arterial feeder. One of these patients made a full recovery, but the other patient had a permanent deficit. Two other patients experienced transient neurological deficits that resolved within 1 week of embolization. Permanent morbidity was thus 4% (1 of 23 patients). There were no deaths. Twelve patients underwent subsequent radiosurgery, and 11 patients had surgery that resulted in complete resection of their AVMs. Histopathological examinations showed mild acute inflammation in specimens resected 1 day after embolization. Chronic inflammatory changes were observed in specimens resected more than 4 days after embolization. In two patients, angioneurosis of the embolized vessels was noted. No evidence of parenchymal hemorrhage was observed in these patients, and vessel wall integrity was maintained as well.

**CONCLUSION:** Onyx is a new nonadhesive liquid embolic agent that has been used to treat 23 patients at our institution with good results. Its nonadhesive nature and ease of use make it a promising agent in the future treatment of AVMs. (Neurosurgery 48:984–997, 2001)

**Key words:** Cerebral arteriovenous malformation, Embolic material, Embolization, Endovascular therapy

Modern treatment of arteriovenous malformations (AVMs) of the brain includes the following interventions alone or in combination: surgery, radiosurgery, and endovascular embolization (7, 16, 18, 26, 29, 30, 35, 46, 47). Preoperative embolization of AVMs is induced to enhance the safety of surgery by occluding the AVM nidus. Before radiosurgery, reduction in AVM volume, occlusion of aneurysms, and high-flow fistulae are the desired outcomes of endovascular embolization. A variety of embolic agents are used to induce embolization (3, 7, 10, 15, 18, 21, 22, 30, 31, 36, 37, 39, 47). The most commonly used agents include polyvinyl alcohol (PVA) particles, acrylic polymers, and coils (7, 15, 18, 25, 30, 31, 37, 38, 47). PVA and coils are commercially available in the United States (i.e., approved by the Food and Drug Ad-

ministration). Microspheres (precisely calibrated, spherical particles) have been evaluated for embolization of cerebral AVMs (2). 2-hexyl-cyanoacrylate (Provasis Therapeutics, Inc., El Cajon, CA) is currently being evaluated for embolization of cerebral AVMs as well. More recently, the Food and Drug Administration has approved *n*-butylcyanoacrylate (NBCA; Cordis Neurovascular, Inc., Miami, FL) for the treatment of cerebral AVMs (21). The Onyx Liquid Embolic System (Onyx; Micro Therapeutics, Inc., Irvine, CA) is a new, nonadhesive liquid embolic agent that is currently being evaluated at our institution for embolization of AVMs. We previously reported our laboratory experience in which we found acute and chronic changes in the vasculature of laboratory animals after inducing embolization with Onyx (24). The purpose of this

## Embolization of Arteriovenous Malformations with Onyx

article is to report our clinical experience with Onyx in the preoperative and preradiosurgical treatment of AVMs in the human brain.

### PATIENTS AND METHODS

Onyx is supplied in ready-to-use vials. Each vial contains ethylene-vinyl alcohol copolymer (EVOH), dimethyl sulfoxide (DMSO), and tantalum (24). EVOH is formed of 48 mol/L ethylene and 52 mol/L vinyl alcohol. The polymer is dissolved in DMSO and is prepared in three different concentrations, 6.0, 6.5, and 8.0%. Onyx 6.0% contains 6.0% copolymer and 94% DMSO, Onyx 6.5% contains 6.5% copolymer and 93.5% DMSO, and Onyx 8.0% contains 8.0% copolymer and 92% DMSO. Micronized tantalum powder (35% weight/volume) is added for radiopacity. The lower the concentration of the copolymer, the less viscous the agent and the more distal penetration can be achieved. Onyx viscosity of 6.0% and 6.5% is 18 and 20 centipoise (cps; unit of viscosity), respectively. In our embolizations, we generally use Onyx 6.0% or 6.5% for embolization of a plexiform nidus. Onyx 8.0% has a viscosity of 34 cps and is used for embolization of large arteriovenous shunts in the AVM. Onyx 6.0%, 6.5%, and 8.0% are manufactured as Onyx 18, Onyx 20, and Onyx 34, respectively.

The patients underwent embolization with approval from our institution's Institutional Review Board, and informed consent was obtained from all patients. Numerous authors have previously described the techniques of embolization of AVMs, including provocative testing (7, 13, 14, 16, 21), and thus are not reviewed in detail here. Briefly, procedures were performed with the patients under general endotracheal anesthesia. In patients in whom provocative testing was necessary, the procedure was begun with the patient awake, then, after completion of the testing, the patient was placed under general endotracheal anesthesia. Catheterization was performed via a transfemoral approach using standard coaxial techniques. Systemic anticoagulation was achieved during the procedures with heparin 5000 U bolus followed by 1000 U of heparin every hour. The microcatheters (Micro Therapeutics, Inc.) used for the embolization procedure were DMSO-compatible. The microcatheter tip was placed as close as possible to the AVM nidus to ensure that the liquid embolic agent would penetrate and occlude the nidus. Once the microcatheter tip was in optimal position, the injection of Onyx was carried out as follows: 1) the microcatheter was flushed with 5 ml of normal saline; 2) 0.25 ml DMSO is injected into the microcatheter to fill the catheter dead space; 3) the Onyx is aspirated into a 1-ml syringe, and 0.25 ml of this amount is injected slowly for 40 seconds to fill the microcatheter and replace the DMSO in the catheter dead space; 4) slow injection of the Onyx is then continued under fluoroscopy.

From January 1998 to May 1999, 23 patients with AVMs of the brain underwent embolization procedure before surgery

or radiosurgical treatment at our institution. The patients' average age was 40 years (range, 19–71 yr). The patient group comprised 8 men and 15 women. Presenting symptoms are outlined in *Table 1*, with the most common presentation being seizures (9 [39%] of 23 patients). The patients' clinical status was assessed at presentation and at 24 hours after embolization using the National Institutes of Health Stroke Scale and the Barthel Index. *Tables 2* and *3* show the classification of the AVMs using the Spetzler-Martin grading system (40). The average Spetzler-Martin grade in the series was 3 (range, 1–4). Of our 23 patients, 10 had involvement of the right cerebral hemisphere, 11 had involvement of the left hemisphere, and 2 had cerebellar lesions. AVM size was obtained from the angiographic images, and AVM volume was calculated retrospectively by the method that Pasqualin et al. (27) described ( $V = \text{width} \times \text{height} \times \text{length} \times 0.52$ ). Reduction in AVM volume was calculated as follows:  $[(\text{preembolization } V - \text{postembolization } V) / \text{preembolization } V] \times 100$ . Eleven patients underwent subsequent surgical resection of their AVMs, and the remaining 12 had stereotactic radiosurgery. At our institution, postoperative angiography is performed only in patients in whom the surgeon wants to confirm complete AVM resection. As such, eight patients underwent cerebral angiography after surgical resection. Three patients did not have postoperative angiography, because the surgeons were confident of complete resection. One patient underwent follow-up angiography 20 months after radiosurgery. The remainder of the patients who had radiosurgery were followed with magnetic resonance imaging (MRI), as is the routine at our institution.

Histological examination of the resected AVMs was performed. The resected specimens were routinely fixed in formalin and embedded in paraffin. Serial 6- to 8- $\mu\text{m}$  sections were then obtained and stained with hematoxylin and eosin and elastica van Gieson stain before review.

### RESULTS

#### Anatomic results

Our 23 patients underwent an aggregate total of 33 procedures, with an aggregate total of 129 feeding arterial vessels embolized. The AVMs' average maximal diameter was

**TABLE 1. Presenting Symptoms of 23 Patients with Arteriovenous Malformations**

| Presenting Symptoms  | No. of Patients (%) |
|----------------------|---------------------|
| Seizure              | 9/23 (39.1%)        |
| Hemorrhage           | 6/23 (26.1%)        |
| Headache             | 4/23 (17.4%)        |
| Neurological deficit | 4/23 (17.4%)        |

**TABLE 2. Spetzler-Martin Classification of Arteriovenous Malformations in Patients Studied**

| Grade | No. of Patients (%) |
|-------|---------------------|
| I     | 2 (8.7%)            |
| II    | 5 (21.7%)           |
| III   | 11 (47.8%)          |
| IV    | 5 (21.7%)           |
| V     | 0 (0%)              |

3.6 cm (range, 1.7–6.5 cm), and their average volume was 14.5 cm<sup>3</sup> (range, 0.6–39 cm<sup>3</sup>). Average AVM volume reduction after embolization was 63%. In four patients, large arteriovenous shunts were occluded with a combination of platinum coils and Onyx. Single injections of Onyx were carried out for up to 12 minutes with good nidus penetration. Long injection times were possible because of the nonadhesive nature of Onyx. During injections, we were able to pause, obtain an angiogram to assess nidus occlusion and the status of the draining veins, and then continue the injection with the same catheter. In several instances, we were also able to complete injection of one pedicle, withdraw the catheter and place it in a more proximal pedicle, and continue the injection through the second arterial feeder. These maneuvers allowed for controlled delivery of the embolic agent. Nidus penetration was particularly good when the catheter achieved a wedge position in the vessel. No venous occlusions occurred as a result of venous migration of the embolic material. When any venous migration was noted, the injection was stopped to allow for solidification, then the injection was continued. The Onyx then filled a different portion of the nidus, with no further filling of that particular vein. No instances of gluing of the catheter to the vessel occurred. In one instance, however, a moderate amount of reflux around the catheter tip was allowed during injection, and this occurrence made retrieval of the catheter difficult, with moderate tension required for withdrawal.

Eleven patients underwent surgical resection of their AVMs 1 to 14 days after embolization. Eight of these 11 patients had subsequent cerebral angiography after resection, and in all eight, no residual AVM was observed. Of the 12 patients who had radiosurgery, 1 had follow-up angiography at 20 months posttreatment. This patient showed marked reduction in the size of the nidus and no evidence of recanalization of previously embolized vessels. MRI follow-up of the remainder of the patients showed reduction in the size of the nidus, as evidenced by decreases in nidus flow voids seen on cross-sectional imaging and decreases in the size of the draining veins.

### Clinical results

Neurological evaluation was performed on admission and 24 hours after the procedure. The patients' preprocedure av-

erage National Institutes of Health Stroke Scale and Barthel Index scores were 2.0 and 97.0, respectively. After the procedure, the patients' average National Institutes of Health Stroke Scale and Barthel Index scores were 2.8 and 92.6, respectively. Four adverse events occurred (4 [17%] of 23 patients). Three patients made full recoveries with appropriate medical management. One patient developed right-sided hemiplegia that did not completely resolve on follow-up. The long-term morbidity rate was thus 4% (1 of 23 patients). There were no deaths. The four adverse events are detailed in *Table 3*.

### Neurological deficit after embolization

A 29-year-old man presented with new-onset seizure and an AVM (Spetzler-Martin Grade 4) located in the left frontal lobe, high over the convexity, and just anterior to the central sulcus. Branches of the left anterior cerebral artery and middle cerebral artery fed the lesion. The feeding arteries from the middle cerebral artery were tested with Amytal (Eli Lilly & Co., Indianapolis, IN). This testing resulted in reversible right-upper-extremity weakness, and therefore no embolization was performed in that location. The anterior cerebral artery arterial feeder, a branch of the pericallosal artery, was tested with Amytal with no resultant neurological deficits. We therefore proceeded with embolization of this vessel. During embolization, embolic material was deposited in a branch of the vessel proximal to the microcatheter tip. No reflux had been noted during the injection, and only after embolic material had accumulated in the adjacent vessel was reflux noted to have occurred with inadvertent occlusion of a more proximal branch. The patient developed right-lower-extremity weakness with motor strength of 2/5 immediately after the procedure. The patient could move his leg only with gravity eliminated. A computed tomographic scan showed no evidence of bleeding, and an MRI study showed no new lesion. After the procedure, with aggressive hypertensive, hypervolumic therapy, this patient showed rapid improvement in motor strength. He underwent intense physical rehabilitation and at the time of discharge had 4/5 motor strength in his right lower extremity. He had stereotactic radiosurgery 1 month after embolization. On follow-up 18 months after radiosurgery, his neurological examination was normal. He has since returned to work and resumed his previous level of activity.

### Transient vertical diplopia after embolization

A 42-year-old woman presented with a history of headaches and a right lateral occipital AVM. During embolization of a posterior cerebral artery feeder, a moderate amount of reflux around the microcatheter tip was allowed. Reflux made withdrawal of the catheter difficult, and a moderate amount of tension needed to be applied to withdraw the microcatheter. No other technical difficulties arose during the procedure. Upon awakening from anesthesia, the patient complained of double vision. An MRI study was obtained, but it revealed no new lesions. An ophthalmological evaluation revealed that she had vertical diplopia with weakness of the left inferior oblique mus-

TABLE 3. Patient Demographics and Adverse Events after Embolization<sup>a</sup>

| Patient | Age (yr)/Sex | AVM Location             | Spetzler-Martin Grade | Adverse Events                       |
|---------|--------------|--------------------------|-----------------------|--------------------------------------|
| 1       | 42/F         | Right temporal/occipital | III                   | Transient vertical diplopia          |
| 2       | 31/M         | Right frontal/parietal   | IV                    | None                                 |
| 3       | 38/M         | Left temporal            | II                    | None                                 |
| 4       | 29/M         | Left frontal             | III                   | Right-lower-extremity paresis        |
| 5       | 35/F         | Left temporal            | II                    | None                                 |
| 6       | 23/F         | Right parietal/occipital | IV                    | None                                 |
| 7       | 62/M         | Left temporal            | IV                    | None                                 |
| 8       | 63/F         | Right frontal/parietal   | I                     | None                                 |
| 9       | 42/F         | Right parietal           | III                   | None                                 |
| 10      | 43/F         | Right temporal/occipital | II                    | None                                 |
| 11      | 65/F         | Right frontal/parietal   | III                   | None                                 |
| 12      | 47/M         | Cerebellum               | III                   | None                                 |
| 13      | 19/M         | Left basal ganglion      | IV                    | None                                 |
| 14      | 46/M         | Right parietal/occipital | III                   | None                                 |
| 15      | 23/F         | Left temporal            | II                    | None                                 |
| 16      | 51/F         | Left temporal/occipital  | III                   | None                                 |
| 17      | 30/F         | Cerebellum               | III                   | None                                 |
| 18      | 71/F         | Left temporal/occipital  | III                   | None                                 |
| 19      | 40/M         | Left parietal            | IV                    | None                                 |
| 20      | 20/F         | Right temporal           | II                    | None                                 |
| 21      | 47/F         | Left temporal/parietal   | III                   | Transient neurological deterioration |
| 22      | 31/F         | Right parietal           | I                     | None                                 |
| 23      | 38/F         | Left basal ganglion      | III                   | Right hemiplegia                     |

<sup>a</sup> AVM, arteriovenous malformation.

cle. No other evidence of IIIrd cranial nerve palsy was found. The etiology was unclear. One possible explanation was that during forced withdrawal of the catheter, there was straightening of the posterior cerebral arteries and subsequent stretching of the IIIrd cranial nerve. The patient was offered no specific treatment at that time. At follow-up 1 week after discharge, the patient's diplopia had resolved. She subsequently underwent a second embolization procedure followed by complete surgical resection of the AVM.

#### *Transient neurological deterioration after embolization*

A 47-year-old woman presented with right hemianopia and was found to have a left posterior temporoparietal AVM. She underwent a two-stage embolization of the AVM. Twenty-four hours after the second procedure, she was found to be somnolent. An emergent computed tomographic scan of the

brain was obtained but revealed no acute hemorrhage. Edema was noted in the occipital and temporal lobes surrounding the AVM, however. The patient's edema was thought to be vasogenic edema related to delayed thrombosis of a draining vein of the AVM. Because the draining veins were open at the end of the procedure, the thrombosis was presumed to have developed because of reduction in flow through the enlarged draining veins. Stagnant flow resulted in thrombosis of one or several of the veins. The patient was prescribed dexamethasone and transferred to the intensive care unit for observation. The next day, she showed significant improvement in mental status and was transferred to the floor. She was continued on tapering doses of dexamethasone and was discharged to home in good condition 4 days after the second embolization procedure. One month later, she underwent stereotactic radiosurgery of the AVM without complication.

### Right hemiplegia after embolization

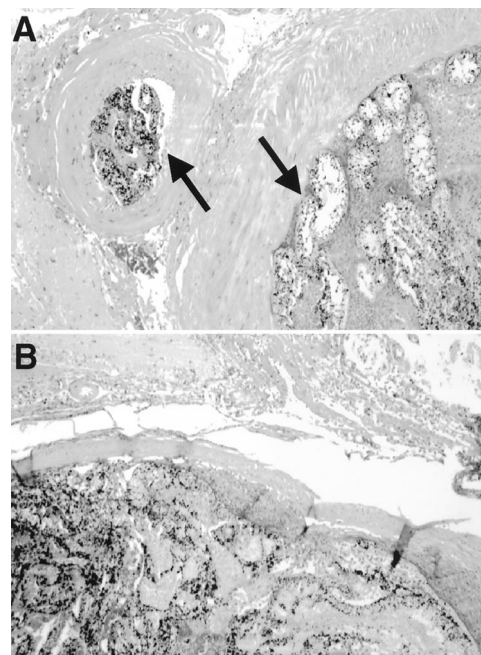
A 38-year-old woman with left basal ganglia AVM (Spetzler-Martin Grade 3) presented with acute hemorrhage that had resulted in right-sided hemiparesis, hemianesthesia, and right homonymous hemianopia. The cause of the hemorrhage was an aneurysm off the left anterior choroidal artery, which was a feeder to the AVM. The plan was to occlude this feeder and the aneurysm and follow this procedure with radiosurgery. Angiograms were obtained, on which the anterior choroidal artery was observed to divide shortly after its origin from the left internal carotid artery into two branches. One of these branches followed the expected course of the vessel, and the other branch supplied the AVM and had an associated aneurysm. An Amytal test was performed in the branch supplying the AVM, and the patient exhibited no deficits. This branch was thought to be safe to occlude, and we proceeded with embolization. This vessel was small, and the catheter was wedged into the artery. Onyx was injected; however, some of the liquid embolic agent refluxed into the other branch of the anterior choroidal artery. A follow-up angiogram showed occlusion of both branches of the anterior choroidal artery. The patient awoke from anesthesia with right-upper-extremity flaccid paralysis and 1/5 strength in the right lower extremity. An MRI scan obtained after embolization showed infarct in the anterior choroidal artery territory. The patient underwent intense physical rehabilitation and had stereotactic radiosurgery 2 months later. At follow-up 8 months after embolization, the patient demonstrated significant improvement in the right-upper-extremity paralysis, with 3/5 motor strength. She was also able to walk with the aid of a walker.

### Histopathology

Eleven patients underwent surgical resection of their AVMs. Histopathological examination of nine patients was performed. Surgery on the remaining two patients was performed at an outside institution, and their tumor specimens were not available for review. The lumina of the embolized vessels were filled with the embolization material, which on microscopic examination appeared as hyaline, eosinophilic material admixed with granular black pigment (tantalum powder) (Fig. 1). Although in some cases the embolized vessels were completely filled with the embolic material, it was not uncommon to observe the embolic material filling a small portion of the vessel lumen, with the remainder of the lumen filled with thrombus (i.e., the appearance was that of a mural thrombus). Blood vessels ranging in size from 80  $\mu$ m to 1 mm in diameter were filled with the embolic material.

One patient who had undergone surgery on the same day as the embolization procedure showed no evidence of an associated inflammatory infiltrate (Fig. 1). Nidus vessels were occluded with the embolic material, with no angioneurosis observed.

Four specimens were resected 1 day after embolization. A mild acute inflammatory reaction with no angioneurosis was noted in two of these patients, with polymorphonuclear leukocytes in the vessel walls sometimes extending into the vascular



**FIGURE 1.** Photomicrographs of an AVM that was resected after embolization on the same day the embolization was induced. **A**, vessels of various sizes were occluded with the embolic material (arrows). **B**, the lumen of the vessel is filled with embolic material admixed with the black pigment tantalum. No evidence of inflammatory infiltrate was observed in this patient.

adventitia. The remaining two patients showed evidence of angioneurosis characterized by the loss and fragmentation of nuclei of cells in vessel walls (especially smooth muscle cells), eosinophilia, and polymorphonuclear infiltration of the entire thickness of the vessel wall (Fig. 2). No evidence of hemorrhage into the adjacent parenchyma was observed in these patients. Vessel wall integrity was maintained in all embolized vessels, and no evidence of perivascular extravasation of embolic material was observed. No evidence of angioneurosis was found in the remaining patients examined.

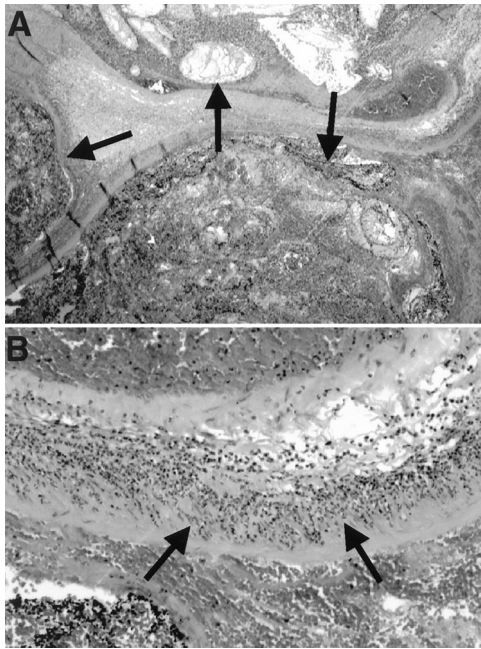
One patient who had undergone surgery 4 days after embolization showed no evidence of acute inflammation or angioneurosis. A mild mononuclear infiltrate (including lymphocytes and histiocytes) was observed in the vessel walls in this patient.

Patients whose AVMs were resected 12 to 14 days after embolization had mild mononuclear infiltration in the vessel walls. Multinucleated giant cells intraluminally surrounding the embolic material were commonly noted in these specimens (Fig. 3). No definite histopathological evidence of thrombosis and recanalization was found in any of the specimens examined.

### ILLUSTRATIVE CASES

#### Patient 1

A 23-year-old woman with a history of seizures caused by a left temporal AVM, Spetzler-Martin Grade 2 (Fig. 4) was admitted for embolization and surgical resection. An angiogram revealed that the



**FIGURE 2.** Photomicrographs of an AVM resected 1 day after embolization. Extensive angioneclerosis of the vessel walls is noted in this specimen. Low-power view (A) shows lumina of three blood vessels filled with Onyx (arrows). A dense inflammatory infiltrate (arrows) is visible in a largely necrotic vessel wall (B).

AVM was fed predominantly by temporal branches of the left middle cerebral artery (Fig. 4B). The nidus was plexiform, with no evidence of large arteriovenous fistulae. Superselective catheterization (Fig. 4C) of feeding arterial vessels was performed using a DMSO-compatible 1.8-French Flow Rider microcatheter (Micro Therapeutics, Inc.). Catheterization was followed by embolization with 6.0% Onyx. After injecting 0.3 ml Onyx, an angiogram was performed, without removing the microcatheter, to assess the AVM nidus. The injection was then continued with the same microcatheter, and excellent penetration of the nidus was achieved (Fig. 4D). After the procedure, the patient's AVM volume was reduced by 97% (Fig. 4E). The main remaining feeding arterial vessel was the anterior choroidal artery (Fig. 4E), which could not be embolized. The patient subsequently underwent surgical resection of the AVM. A postoperative angiogram showed no residual AVM (Fig. 4F).

### Patient 2

A 47-year-old man had a posterior fossa AVM (Spetzler-Martin Grade 3), with the nidus involving predominantly the superior cerebellar vermis (Fig. 5). An angiogram revealed that the AVM was fed mostly by branches of both superior cerebellar arteries (Fig. 5B). Selective catheterization of arterial feeders was performed, followed by embolization with 6.0% and 6.5% Onyx. The injections lasted for 4 to 5 minutes. Good nidus penetration was achieved (Fig. 5C). The embolization was performed in two sessions, and after embolization 85% reduction in AVM volume was noted (Fig. 5D). No technical or clinical complications occurred. The patient subsequently had stereotactic radiosurgery at another institution.

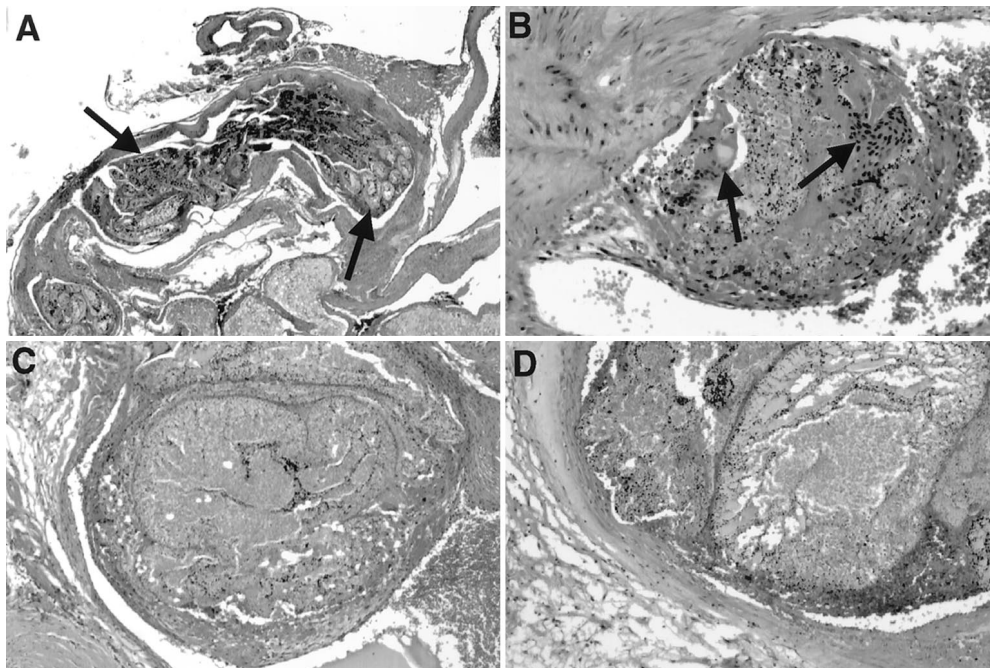
### DISCUSSION

The most commonly used embolic agents for treatment of AVMs are PVA and NBCA. PVA requires the use of a guidewire-directed catheter system. The microcatheter used must have a luminal diameter that is large enough to accept particles of various sizes. The appropriate particle size is estimated by high-resolution angiographic evaluation of the AVM angioarchitecture. Recanalization can be achieved with PVA, although whether the result is true recanalization or development of arterial collaterals because of proximal occlusion, particularly with larger-sized particles, is not clear (6, 15, 30, 50). The process of nidus occlusion is slower when embolization is performed with particulates as compared with the use of liquid embolic agents. During embolization with particulates, low-pressure shunts are occluded first with an increase in nidus pressure over time. The added time during which the nidus withstands increased pressure before it is completely obliterated can theoretically increase the immediate risk of hemorrhage (1, 17, 19, 20, 47).

Embolization with NBCA uses lightweight, flow-directed catheters, which are less traumatic for the patient. The embolic agent is injected into the AVM nidus to form an acrylic cast. Although revascularization has also been demonstrated to occur when acrylic agents are used, NBCA is one of the more permanent embolic agents (7, 12, 13, 32, 48). The use of NBCA in inducing embolization requires considerable experience, however. Much of the technique involves subjective evaluation of the superselective angiogram and evaluation of the AVM angioarchitecture. To control placement of the acrylic in the nidus, Ethiodol (Savage Laboratories, Melville, NY) is mixed in various proportions with NBCA to delay its polymerization time. Accurate polymerization time is necessary to ensure delivery of the agent into the nidus and avoid migration of the agent too distally into the vein or proximal occlusion of an arterial feeder without nidus penetration. The amount of Ethiodol to be mixed with acrylic is estimated by evaluating transit time through the nidus by angiography. For radiopacity, tantalum or tungsten is added to the mixture. Because acrylics are adhesive, the neurointerventionalist needs to be aware of the risk of gluing the catheter to the vessel. To avoid this complication, rapid withdrawal of the catheter is necessary at termination of the injection and before any reflux has occurred. This property of acrylics also somewhat limits controlled delivery of the agent. Prolonged injections are not possible, and only a limited amount of nidus can usually be occluded with a single injection.

In contrast to NBCA, Onyx is a nonadhesive liquid embolic agent. As mentioned above, it is supplied in ready-to-use vials, and therefore no mixing of its various components is required before injection. The nonadhesive property of Onyx eliminates the risk of gluing the catheter to the vessel and allows the surgeon far greater latitude in varying the rate of injection and the amount of the agent delivered during a single injection.

Taki and colleagues (16a, 42, 43, 49) first described the use of EVOH for cerebral AVMs. They treated three patients with



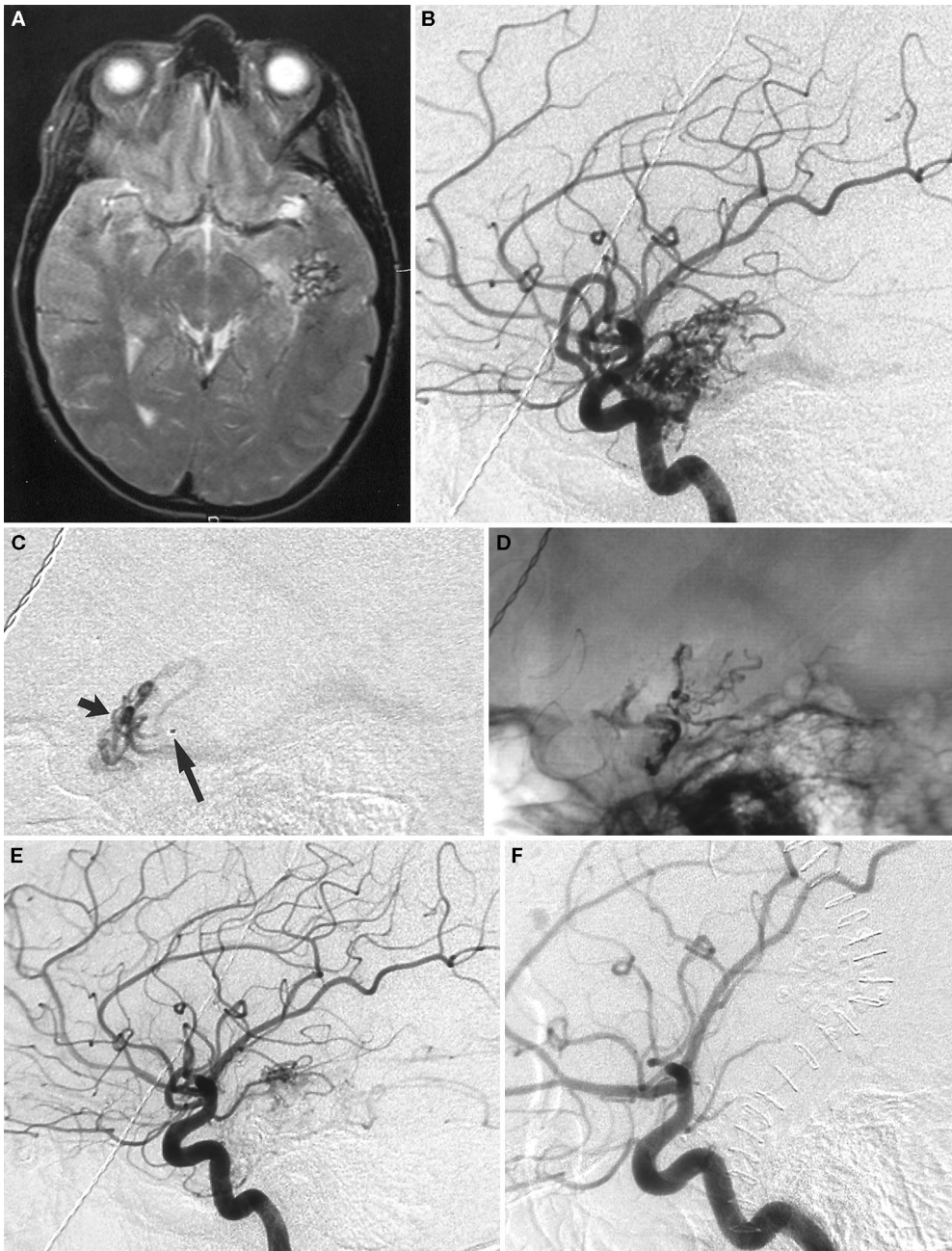
**FIGURE 3.** Photomicrographs of an AVM resected 14 days after embolization. *A*, lumina of blood vessels of various sizes (arrows) are filled with embolic material, which is identifiable because of the black particulate tantalum admixed with Onyx. *B*, multinucleated foreign body giant cells are seen surrounding the intraluminal material (arrows). *C* and *D*, occlusive thrombi containing Onyx are seen; note the negligible injury to the adjacent vessel walls.

AVMs with EVOH, with 95% of the nidus occluded in two patients and 75% of the nidus occluded in the third patient (42). In 1991, three additional patients treated with EVOH were reported, with 95% occlusion of the AVM in one patient, and complete surgical removal after embolization in the other two (43). Chaloupka et al. (5) reported radiographic and histopathological findings in swine rete mirabile after injections of DMSO and EVOH. These authors made no mention of the injection rate of DMSO; they mentioned only that "slow" injection was performed. Injections of 0.8 ml or more DMSO resulted in severe progressive vasospasm of the infused blood vessel. None of the swine that had been infused with 0.8 ml or more DMSO survived. Necropsy of these swine revealed extensive infarction of the cerebral hemisphere and upper brainstem ipsilateral to the side of injection, because of the severe vasospasm. In four swine that received 0.5 ml DMSO, subarachnoid hemorrhage developed 7 to 14 days after infusion. On necropsy of these four animals, gross inspection of the cerebral arteries revealed microaneurysms caused by angioneurosis. Sampei et al. (34) reported that infusion of DMSO for 5 seconds resulted in severe vasospasm and often in cerebral infarction in rats. Concern about the angiototoxicity of the organic solvent halted further development and widespread use of this agent. Murayama et al. (24) performed additional studies in swine rete mirabile to evaluate DMSO's angiototoxicity. They reported that contact time with the arterial wall and volume of DMSO were the two most important determinants of this agent's angiototoxicity. It was determined that injection of 0.3 ml DMSO for 40 seconds did not result in significant vasospasm or in angioneurosis. Chaloupka et al. (4) reexamined the angiototoxicity of DMSO in the swine rete mirabile and found that slow injections (30, 60, and 90 s) of small volumes of DMSO (0.5 or 0.8 ml) did not result in

significant vasospasm or angioneurosis. Murayama et al. (24) reported favorable experience in the use of Onyx in animal studies and described use of the agent in the first 15 patients treated (23). Other embolic agents using DMSO as the solvent have also been described, with no adverse events caused by the solvent reported (44).

Our preliminary clinical experience with Onyx has been encouraging. Embolization achieved an average 63% reduction in AVM volume. In 17 (74%) of 23 patients, 50% or greater reduction in AVM volume was achieved, which is comparable with the results of other series reported in the literature. Viñuela et al. (46) reported their experience in embolization of 101 AVMs. In 80% of their patients, a 50% or greater reduction in AVM volume was achieved. Gobin et al. (16) reported their experience in combined radiosurgery and embolization of 125 AVMs. An average 67% reduction in AVM volume was achieved in their series. Eleven patients in our series underwent surgical resection of their AVMs, with complete removal of the lesions being achieved in all cases. Other published series have reported complete surgical removal of AVMs after embolization in 58 to 100% of cases (7, 13, 14, 18, 46, 47).

No adverse cardiovascular effects were noted during injection of the embolic agent. No gluing of the catheter to the vessel occurred. Four adverse events (4 of 23, 17%) occurred in our series, as outlined in detail above. None of our patients died. The first adverse event is of particular interest and was directly related to the embolic agent. Poor visualization of the Onyx led to reflux of the embolic agent, with resultant inadvertent occlusion of a more proximal branch. In developing a new embolic agent, the issue of the radiopacity of the material is of particular importance. Onyx is supplied in prepared vials that already contain premixed tantalum powder. The vials are kept on a shaker (Vortex-Genie; Micro Therapeutics, Inc.) for

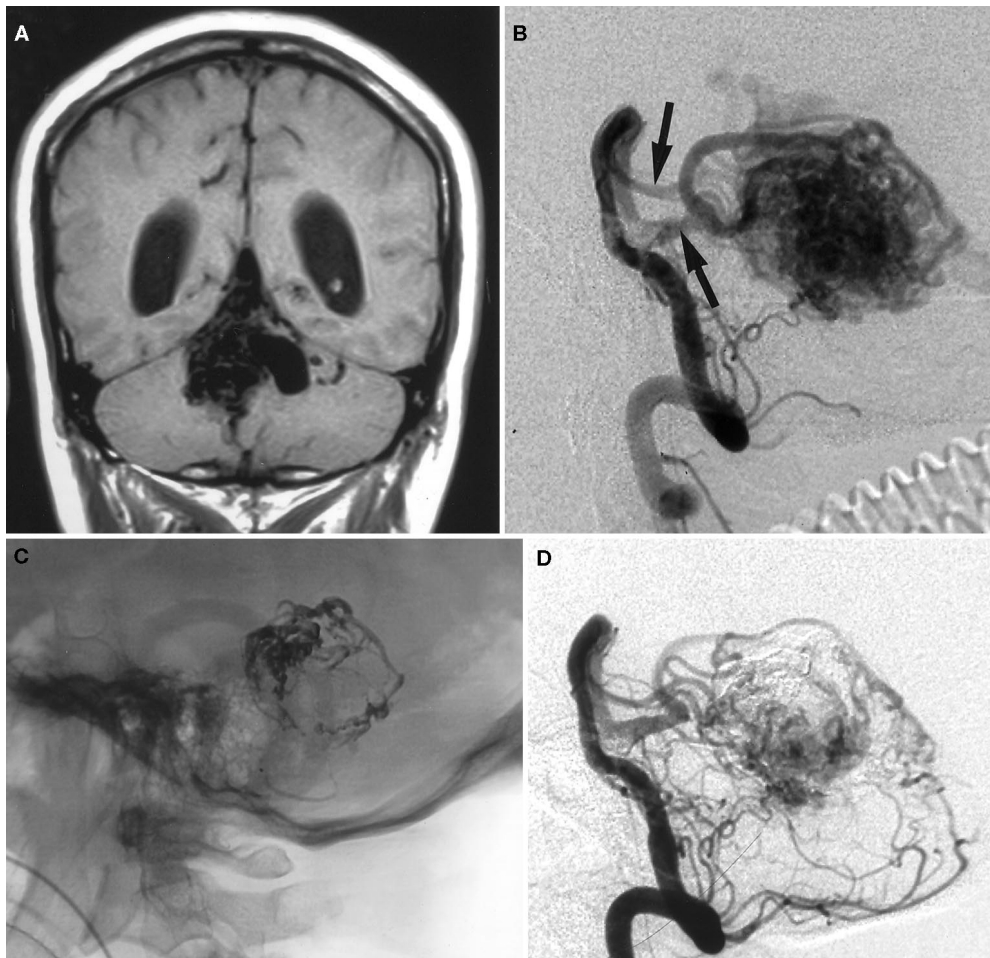


**FIGURE 4.** *A*, MRI scan of the brain (T2W) shows the AVM in the left temporal lobe. *B*, angiogram showing the plexiform AVM filled by temporal branches of the left middle cerebral artery. *C*, angiogram shows a lateral view of the tip of the microcatheter (*long arrow*) in a temporal branch of the left middle cerebral artery. Angiogram fills part of the plexiform nidus (*short arrow*) of the AVM. Onyx was injected through the microcatheter, and then, without removing the microcatheter, an angiogram was obtained to evaluate the AVM, after which additional Onyx was injected into the AVM. *D*, angiogram shows that a significant amount of Onyx is deposited in the AVM. Note the cast of Onyx after a single injection. *E*, angiogram shows that after embolization is induced, the AVM is significantly reduced in size. *F*, postoperative angiogram shows complete resection of the lesion.

at least 20 minutes until the physician is ready for injection. An improvement in the design of the shaker was made after this adverse event in our first patient to improve mixing of the tantalum and the visibility of the liquid embolic agent. Of particular importance is that the vials must be kept on the shaker until the exact time when injection is to be performed. If the vials are taken off the shaker prematurely, the tantalum may settle in the bottle. In the 21 patients treated after redesign of the shaker, visibility was excellent and no further complications related of this cause occurred.

The second adverse event that occurred was due to excessive reflux that was allowed to occur around the catheter tip. Although Onyx is nonadhesive, we do not recommend allowing much reflux around the catheter tip during injection, because it may make withdrawal of the catheter difficult and may lead to complications.

The third adverse event was not directly related to the embolic agent but was presumed to be due to delayed thrombosis of a draining vein. This phenomenon has previously been described (11). Reduction in flow through the AVM



**FIGURE 5.** *A*, MRI scan (T1W) of the brain shows the AVM involving the cerebellar vermis. *B*, angiogram shows a lateral view of left vertebral artery injection highlighting the bilateral superior cerebellar arteries (arrows) that supply the AVM. *C*, angiogram shows a lateral view of the cranium after embolization and displays the cast of Onyx. *D*, left vertebral artery angiogram after embolization showing significant reduction in the size of the AVM.

results in stagnant flow through enlarged draining veins, which can lead to delayed thrombosis of one or several draining veins. This etiology was presumed in our third adverse event because no migration of embolic agent into the veins was observed during the procedure and the draining veins were open at the end of the embolization. This patient returned to her baseline neurological status with steroid treatment and underwent radiosurgery 1 month after embolization.

The fourth adverse event was due to reflux of Onyx around the catheter with occlusion of a more proximal branch—in this case, the anterior choroidal artery. We speculated that the sudden reflux occurred because of vasospasm of the artery being embolized. This vasospasm may have been related to the DMSO infusion, which emphasizes the importance of slow injection of DMSO to prevent vessel vasospasm, as described above.

Our results thus far are comparable with those of other reported series that used other agents. In 54 patients treated with NBCA, Debrun et al. (7) reported two minor permanent neurological deficits, one patient with an increasing neurological deficit after embolization, and two deaths. They reported gluing of the catheter to the vessel wall in six patients. In another study (47), 4 of the 22 patients who underwent par-

ticle embolization of their AVMs had neurological complications, all of which were ischemic and one of which was major. In the same study, 23 patients underwent acrylic embolization. Four of those patients had ischemic deficits, but no major deficits were reported. Viñuela et al. (46) reported a morbidity rate of 13%, with the most common cause being ischemia or brain infarct due to inadvertent occlusion of normal arteries. One death occurred in this series of 101 patients. Of 125 patients treated with acrylates (16), permanent complications occurred in 12.8%, with minor deficits in 5.6%, moderate deficits in 4.8%, and major deficits in 2.4%. Two deaths occurred in this series, for a 1.6% mortality rate. Other series have reported endovascular complication rates of between 3 and 25% (8, 9, 13, 14, 28, 33). Our results are comparable with those of previous reports and within the range reported previously.

After radiosurgery, our institution's standard practice is to follow patients with MRI studies to document nidus obliteration. Once nidus obliteration is noted on MRI studies, an angiogram is obtained for confirmation. Patients who have had radiosurgery constitute an appropriate population for long-term follow-up of occlusion of Onyx in embolized AVMs. Because we obtain MRI scans for follow-up, however, follow-up

angiography could be performed in only one patient. In this patient, no evidence of recanalization of previously embolized vessels was observed 20 months after radiosurgery. Because of lack of long-term follow-up, no conclusions can be drawn regarding the permanency of occlusion of Onyx. Short-term follow-up results in this patient population are available, however. At the time of radiosurgery, an angiogram was obtained with patients positioned in a stereotactic frame. These angiograms were obtained from 1 to 100 days after embolization. The angiograms were reviewed at the time of radiosurgery, and they did not reveal evidence of recanalization. Histopathological examination of the resected specimens also did not show any evidence of thrombosis and recanalization; these patients had undergone surgery from 1 to 14 days after embolization. Murayama et al. (24) reported no evidence of recanalization in swine in follow-up studies conducted up to 6 months after embolization. Recanalization after embolization with both acrylics and PVA has been described (6, 7, 12, 13, 15, 30, 32, 45, 47, 48, 50).

Histopathological examination of resected AVMs revealed angioneurosis involving many vessels in two patients. These patients had undergone resection 1 day after embolization. Two other patients who had undergone surgery 1 day after embolization did not have evidence of widespread angioneurosis or acute inflammation. The most likely cause of angioneurosis is DMSO. It is well known that DMSO is angiotoxic and that its effect is dependent on the volume of DMSO injected and its contact time with the endothelium (5, 24, 34). Injection of 0.3 ml DMSO for 40 seconds was found to be safe, with no histological evidence of angiotoxicity (24). In the injection of Onyx, as discussed above, initially the catheter dead space is filled with 0.25 ml DMSO, followed by slow injection of Onyx for 40 seconds. Slow injection for 40 seconds is important to prevent angiotoxicity. It is possible that in these patients, the injection of DMSO was more rapid, causing the histological changes observed.

The use of DMSO requires an appropriate, compatible delivery system, because DMSO dissolves the polymers used in the construction of many of the commercially available microcatheters. Microcatheters with which DMSO can be used include the Flow Rider (Micro Therapeutics, Inc.), the Easy Rider (Micro Therapeutics, Inc.), and the Radiofocus GT III (Terumo, Tokyo, Japan).

## CONCLUSION

Our initial clinical experience with Onyx has been favorable. The advantages of Onyx include its nonadhesive nature, which allows for more controlled and longer delivery of the agent without catheter gluing. Because longer injections are possible, more of the AVM nidus can be blocked with one injection. The capacity to perform cerebral angiography during injections is also advantageous, because it allows the physician to monitor the degree of AVM nidus obliteration and check the state of the pertinent draining veins. Onyx is supplied in premixed vials, and no additional preparation

is required before injection. The ability to penetrate the nidus with Onyx was good, with histological evaluation showing vessels as small as 80  $\mu$ m embolized with the liquid embolic agent. The disadvantages of Onyx include its solvent DMSO, which can potentially be angiotoxic with rapid injections. DMSO volume and injection time need to be monitored closely to achieve safe embolization of AVMs. In addition, only catheters that are DMSO-compatible can be used with Onyx. Onyx has been used in treating large, high-flow fistulae of AVMs in four patients. In all, four coils were used to achieve flow control before delivery of the liquid embolic agent. Successful occlusion of the fistulae was achieved in all patients. Further studies of the use of Onyx in high-flow fistulae are currently under way in our laboratory.

## ACKNOWLEDGMENTS

This work was supported in part by National Institutes of Health Grant R01 NS38453.

## DISCLOSURE

FV has stock investments in Micro Therapeutics, Inc.

Received, February 11, 2000.

Accepted, January 3, 2001.

**Reprint requests:** Reza Jahan, M.D., Division of Interventional Neuroradiology, Department of Radiological Sciences, Center for the Health Sciences, University of California at Los Angeles School of Medicine, 10833 LeConte Avenue, Room B2-188, Los Angeles, CA 90095-1721. Email: rjahan@mednet.ucla.edu

## REFERENCES

1. Batjer HH, Devous MD Sr, Meyer YJ, Purdy PD, Samson DS: Cerebrovascular hemodynamics in arteriovenous malformation complicated by normal perfusion pressure breakthrough. *Neurosurgery* 22:503-509, 1988.
2. Beaujeux R, Laurent A, Wassef M, Casasco A, Gobin YP, Aymard A, Rufenacht D, Merland JJ: Trisacryl gelatin microspheres for therapeutic embolization: Part II—Preliminary clinical evaluation in tumors and arteriovenous malformations. *AJNR Am J Neuroradiol* 17:541-548, 1996.
3. Brothers MF, Kaufmann JC, Fox AJ, Deveikis JP: *n*-Butyl 2-cyanoacrylate—substitute for IBCA in interventional neuroradiology: Histopathologic and polymerization time studies. *AJNR Am J Neuroradiol* 10:777-786, 1989.
4. Chaloupka JC, Huddle DC, Alderman J, Fink S, Hammond R, Vinters HV: A reexamination of the angiotoxicity of superselective injection of DMSO in the swine rete embolization model. *AJNR Am J Neuroradiol* 20:401-410, 1999.
5. Chaloupka JC, Viñuela F, Vinters HV, Robert J: Technical feasibility and histopathologic studies of ethylene vinyl copolymer (EVAL) using a swine endovascular embolization model. *AJNR Am J Neuroradiol* 15:1107-1115, 1994.
6. Davidson GS, Terbrugge KG: Histologic long-term follow-up after embolization with polyvinyl alcohol particles. *AJNR Am J Neuroradiol* 16:843-846, 1995.

7. Debrun GM, Aletich V, Ausman JI, Charbel F, Dujovny M: Embolization of nidus of brain arteriovenous malformations with *n*-butyl cyanoacrylate. **Neurosurgery** 40:112–121, 1997.
8. Deruty R, Pelissou-Guyotat I, Amat D, Mottolese C, Bascoulegue Y, Turjman F, Gerard JP: Complications after multidisciplinary treatment of cerebral arteriovenous malformations. **Acta Neurochir (Wien)** 138:119–131, 1996.
9. Deruty R, Pelissou-Guyotat I, Mottolese C, Bascoulegue Y, Amat D: The combined management of cerebral arteriovenous malformations: Experience with 100 cases and review of the literature. **Acta Neurochir (Wien)** 123:101–112, 1993.
10. Deveikis JP, Manz HJ, Luessenhop AJ, Caputy AJ, Kobrine AI, Schellinger D, Patronas N: A clinical and neuropathologic study of silk suture as an embolic agent for brain arteriovenous malformations. **AJNR Am J Neuroradiol** 15:263–271, 1994.
11. Duckwiler GR, Dion JE, Viñuela F, Reichman A: Delayed venous occlusion following embolotherapy of vascular malformations in the brain. **AJNR Am J Neuroradiol** 13:1571–1579, 1992.
12. Fournier D, Terbrugge K, Rodesch G, Lasjaunias P: Revascularization of brain arteriovenous malformations after embolization with bucrylate. **Neuroradiology** 32:497–501, 1990.
13. Fournier D, Terbrugge KG, Willinsky R, Lasjaunias P, Montanera W: Endovascular treatment of intracerebral arteriovenous malformations: Experience in 49 cases. **J Neurosurg** 75:228–233, 1991.
14. Fox AJ, Pelz DM, Lee DH: Arteriovenous malformations of the brain: Recent results of endovascular therapy. **Radiology** 177:51–57, 1990.
15. Germano IM, Davis RL, Wilson CB, Hieshima GB: Histopathological follow-up study of 66 cerebral arteriovenous malformations after therapeutic embolization with polyvinyl alcohol. **J Neurosurg** 76:607–614, 1992.
16. Gobin YP, Laurent A, Merienne L, Schlienger M, Aymard A, Houdart E, Casasco A, Lefkopoulou D, George B, Merland JJ: Treatment of brain arteriovenous malformations by embolization and radiosurgery. **J Neurosurg** 85:19–28, 1996.
- 16a. Goto K, Ogata N, Iwabuchi S, Matsuno H, Taki W, Iwata H: The role of a new embolization technique for the treatment of brain AVM. **Neuroradiology** 33(Suppl):171, 1991 (abstr).
17. Harders A, Bien S, Eggert HR, Laborde G, Merland JJ, Rufenacht D: Hemodynamic changes in arteriovenous malformations induced by superselective embolization: Transcranial Doppler evaluation. **Neurol Res** 10:239–245, 1988.
18. Jafar JJ, Davis AJ, Berenstein A, Choi IS, Kupersmith MJ: The effect of embolization with N-butyl cyanoacrylate prior to surgical resection of cerebral arteriovenous malformations. **J Neurosurg** 78:60–69, 1993.
19. Jungreis CA, Horton JA: Pressure changes in the arterial feeder to a cerebral AVM as a guide to monitoring therapeutic embolization. **AJNR Am J Neuroradiol** 10:1057–1060, 1989.
20. Jungreis CA, Horton JA, Hecht ST: Blood pressure changes in feeders to cerebral arteriovenous malformations during therapeutic embolization. **AJNR Am J Neuroradiol** 10:575–577, 1989.
21. Kerber CW, Wong W: Liquid acrylic adhesive agents in interventional neuroradiology. **Neurosurg Clin N Am** 11:85–99, 2000.
22. Lylyk P, Viñuela F, Vinters HV, Dion J, Bentson J, Duckwiler G, Lin T: Use of a new mixture for embolization of intracranial vascular malformations: Preliminary experimental experience. **Neuroradiology** 32:304–310, 1990.
23. Murayama Y, Viñuela F, Duckwiler G, Gobin YP, Jahan R, Vinters V, Grobelny T, Lefkowitz M: Non-adhesive liquid embolic agent for the treatment of cerebral AVM: Clinical results at UCLA. **Intervent Neuroradiol** 5[Suppl 1]:78, 1999 (abstr).
24. Murayama Y, Viñuela F, Ulhoa A, Akiba Y, Duckwiler GR, Gobin YP, Vinters HV, Greff RJ: Nonadhesive liquid embolic agent for cerebral arteriovenous malformations: Preliminary histopathological studies in swine rete mirabile. **Neurosurgery** 43:1164–1175, 1998.
25. Nakstad PH, Bakke SJ, Hald JK: Embolization of intracranial arteriovenous malformations and fistulas with polyvinyl alcohol particles and platinum fibre coils. **Neuroradiology** 34:348–351, 1992.
26. O'Laoire SA: Microsurgical treatment of arteriovenous malformations in critical areas of the brain. **Br J Neurosurg** 9:347–360, 1995.
27. Pasqualin A, Barone G, Cioffi F, Rosta L, Scienza R, Da Pian R: The relevance of anatomic and hemodynamic factors to a classification of cerebral arteriovenous malformations. **Neurosurgery** 28:370–379, 1991.
28. Pasqualin A, Scienza R, Cioffi F, Barone G, Benati A, Beltramello A, Da Pian R: Treatment of cerebral arteriovenous malformations with a combination of preoperative embolization and surgery. **Neurosurgery** 29:358–368, 1991.
29. Pikus HJ, Beach ML, Harbaugh RE: Microsurgical treatment of arteriovenous malformations: Analysis and comparison with stereotactic radiosurgery. **J Neurosurg** 88:641–646, 1998.
30. Purdy PD, Batjer HH, Risser RC, Samson D: Arteriovenous malformations of the brain: Choosing embolic materials to enhance safety and ease of excision. **J Neurosurg** 77:217–222, 1992.
31. Purdy PD, Samson D, Batjer HH, Risser RC: Preoperative embolization of cerebral arteriovenous malformations with polyvinyl alcohol particles: Experience in 51 adults. **AJNR Am J Neuroradiol** 11:501–510, 1990.
32. Rao VR, Mandalam KR, Gupta AK, Kumar S, Joseph S: Dissolution of isobutyl 2-cyanoacrylate on long-term follow-up. **AJNR Am J Neuroradiol** 10:135–141, 1989.
33. Rosenblatt S, Lewis AL, Tew JM: Combined interventional and surgical treatment of arteriovenous malformations. **Neuroimaging Clin N Am** 8:469–482, 1998.
34. Sampei K, Hashimoto N, Kazekawa K, Tsukahara T, Iwata H, Takaichi S: Histological changes in brain tissue and vasculature after intracarotid infusion of organic solvents in rats. **Neuroradiology** 38:291–294, 1996.
35. Sasaki T, Kurita H, Saito I, Kawamoto S, Nemoto S, Terahara A, Kirino T, Takakura K: Arteriovenous malformations in the basal ganglia and thalamus: Management and results in 101 cases. **J Neurosurg** 88:285–292, 1998.
36. Schmutz F, McAuliffe W, Anderson DM, Elliott JP, Eskridge JM, Winn HR: Embolization of cerebral arteriovenous malformations with silk: Histopathologic changes and hemorrhagic complications. **AJNR Am J Neuroradiol** 18:1233–1237, 1997.
37. Schumacher M, Horton JA: Treatment of cerebral arteriovenous malformations with PVA: Results and analysis of complications. **Neuroradiology** 33:101–105, 1991.
38. Schweitzer JS, Chang BS, Madsen P, Viñuela F, Martin NA, Marroquin CE, Vinters HV: The pathology of arteriovenous malformations of the brain treated by embolotherapy: Part II—Results of embolization with multiple agents. **Neuroradiology** 35:468–474, 1993.
39. Smith MD, Russell EJ, Levy R, Crowell RM: Transcatheter obliteration of a cerebellar arteriovenous fistula with platinum coils. **AJNR Am J Neuroradiol** 11:1199–1202, 1990.

40. Spetzler RF, Martin NA: A proposed grading system for arteriovenous malformations. *J Neurosurg* 65:476-483, 1986.
41. Deleted in proof.
42. Taki W, Yonekawa Y, Iwata H, Uno A, Yamashita K, Amemiya H: A new liquid material for embolization of arteriovenous malformations. *AJNR Am J Neuroradiol* 11:163-168, 1990.
43. Terada T, Nakamura Y, Nakai K, Tsuura M, Nishiguchi T, Hayashi S, Kido T, Taki W, Iwata H, Komai N: Embolization of arteriovenous malformations with peripheral aneurysms using ethylene vinyl alcohol copolymer: Report of three cases. *J Neurosurg* 75:655-660, 1991.
44. Tokunaga K, Kinugasa K, Kawada S, Nakashima H, Tamiya T, Hirotsune N, Mandai S, Ohmoto T: Embolization of cerebral arteriovenous malformations with cellulose acetate polymer: A clinical, radiological, and histological study. *Neurosurgery* 44:981-990, 1999.
45. Vinters HV, Lundie MJ, Kaufmann JC: Long-term pathological follow-up of cerebral arteriovenous malformations treated by embolization with bucrylate. *N Engl J Med* 314:477-483, 1986.
46. Viñuela F, Dion JE, Duckwiler GR, Martin NA, Lylyk P, Fox A, Pelz D, Drake CG, Girvin JJ, Debrun G: Combined endovascular embolization and surgery in the management of cerebral arteriovenous malformations: Experience in 101 cases. *J Neurosurg* 75:856-864, 1991.
47. Wallace RC, Flom RA, Khayata MH, Dean BL, McKenzie J, Rand JC, Obuchowski NA, Zepp RC, Zabramski JM, Spetzler RF: The safety and effectiveness of brain arteriovenous malformation embolization using acrylic and particles: The experience of a single institution. *Neurosurgery* 37:606-618, 1995.
48. Wikholm G: Occlusion of cerebral arteriovenous malformations with N-butyl cyano-acrylate is permanent. *AJNR Am J Neuroradiol* 16:479-482, 1995.
49. Yamashita K, Taki W, Iwata H, Nakahara I, Nishi S, Sadato A, Matsumoto K, Kikuchi H: Characteristics of ethylene vinyl alcohol copolymer (EVAL) mixtures. *AJNR Am J Neuroradiol* 15:1103-1105, 1994.
50. Zollikofer C, Castaneda-Zuniga WR, Galliani C, Rysavy JA, Formanek A, Amplatz K: Therapeutic blockade of arteries using compressed Ivalon. *Radiology* 136:635-640, 1980.

## COMMENTS

The authors present their initial experience using a new liquid embolic material, Onyx (Onyx Liquid Embolic System; Micro Therapeutics, Inc., Irvine, CA), to treat 23 patients with intracranial cerebral arteriovenous malformations (AVMs) by intravascular embolization techniques. They report treating 129 arterial feeders with an average 63% reduction in AVM volume, with the only morbidity being two transient neurologic events and one permanent stroke (4%) and no mortality. Eleven patients underwent surgical resection, and 12 underwent radiosurgery.

Dr. Waro Taki developed the original formulation for Onyx in Kyoto, Japan, in the early 1990s. It was used quite extensively in Japan to treat cerebral AVMs and for tumor embolization, and some early work was also done in evaluating its use in treatment of cerebral aneurysms. More recently, Onyx has been used in Europe, and it is currently being investigated as an embolic material in the United States for treatment of both cerebral AVMs and large and giant intracranial aneurysms considered to be inoperable or to put the patient at high risk for treatment with conventional endovascular coiling techniques.

The advantage of using Onyx is that it is a liquid embolic material that is opaque, easily injected through a microcatheter, and nonadhesive. This advantage makes it preferable to *n*-butylcyanoacrylate (NBCA; Cordis Neurovascular Inc., Miami, FL), which polymerizes rapidly and may potentially glue the microcatheter in place. NBCA has recently received Food and Drug Administration approval in the treatment of cerebral AVMs. In addition, because injections are slower and more controlled with Onyx, it may be easier to control delivery of the embolic agent to the AVM nidus.

The disadvantages of Onyx are that it uses dimethyl sulfoxide (DMSO) as a solvent. If given in too high a volume or concentration, DMSO is potentially toxic to blood vessels and may lead to acute vessel damage, necrosis, or vasospasm; therefore, only small amounts over certain time periods can be injected into cerebral blood vessels directly. In addition, the long-term follow-up times (>12-24 mo) for patients who have been treated with Onyx have not been studied adequately. Therefore, late recanalization of previously occluded arterial feeders, AVM nidus, or aneurysm occlusion might occur in patients treated with Onyx before radiosurgery or in patients with aneurysms who are treated with Onyx. Nevertheless, it is important to the field of interventional neuroradiology that different types of embolization materials continue to be evaluated and developed. As continued progress is made in the fields of endovascular neurosurgery and interventional neuroradiology, better materials and methods will be used appropriately to improve patient care.

**Randall T. Higashida**  
Interventional Neuroradiologist  
San Francisco, California

Jahan et al. describe their experience in embolizing 129 pedicles in 23 patients with AVMs using ethylene-vinyl alcohol copolymer (EVOH), DMSO, and tantalum. Called Onyx, the embolic agent has three concentrations, containing 6, 6.5, and 8% EVOH, respectively, with the remainder of the solution being composed of DMSO. Complications occurred in 4 of 23 patients: 1 patient experienced a major stroke, and 3 others had minor strokes. Overall, the authors report a 63% reduction in AVM volume. Eleven patients had craniotomies for operative excision of their AVMs, and 12 underwent radiosurgery. Follow-up in terms of postprocedural and late angiography as well as clinical outcome was limited and will hopefully be addressed in future studies.

The potential drawbacks of the DMSO and EVOH combination are several, and they are well discussed by the authors. DMSO can initiate profound vasospasm when infused too rapidly (1). This problem can result in angioneurosis and/or reflux of the embolic agent into adjacent vascular beds, with resultant occlusion of normal vessels. Tantalum powder is added to the agent on a weight-per-volume basis to achieve adequate opacification. However, failure to constantly mix the EVOH-DMSO-tantalum preparation results in an unequal suspension of tantalum with variable opacification, which can result in embolization with a poorly opacified agent. The authors note that one of their complications was likely secondary to poor visualization of the embolic agent. Further-

more, the need to perform embolization with the patient under general anesthesia, owing to the discomfort that Onyx infusion causes, adds an additional anesthesia-related risk and for many practitioners may obviate meaningful barbiturate challenge testing.

However, the combination of DMSO and EVOH yields an embolic agent with potential advantages over traditional agents such as NBCA and ethiodized oil (ethiodol). Cyanoacrylates rapidly polymerize upon contact with ionic solutions (i.e., blood). Their successful use involves tailoring the ratio of cyanoacrylate-to-vehicle (ethiodol) to match polymerization to the flow characteristics of a given lesion. For example, a high-flow lesion would be treated with a higher ratio of glue-to-vehicle (50:50) versus a low- or slow-flow lesion, which would necessitate a lower glue-to-vehicle ratio (i.e., 20:80). Successful use of these agents is dependent on the skill and experience of the surgeon. Even in the most skilled hands, catheters occasionally are glued to the AVM pedicle. The lack of adhesion of Onyx to the microcatheter allows for lengthy, controlled infusion of the embolic agent and affords the surgeon the ability to obtain serial angiograms. This ability is a significant advantage over traditional agents such as NBCA.

Control of the degree of penetration of Onyx is achieved by varying its concentration. The viscosity of the Onyx is the critical determinant of penetration into the nidus. The authors used three different concentrations of Onyx, with the highest concentration (8%) yielding a viscosity nearly double the 6% concentration that was used to achieve maximum penetration of the nidus. The ultimate test of any new device or agent is its technical ease of use, efficacy, and economy in terms of cost and time. Onyx may play a significant role as a future embolic agent. The authors have used it successfully in their patients, in whom they have documented a low complication rate.

**Richard D. Fessler**  
*Detroit, Michigan*  
**L. Nelson Hopkins**  
*Buffalo, New York*

- 
1. Chaloupka JC, Viñuela F, Vinters HV, Robert J: Technical feasibility and histopathologic studies of ethylene vinyl copolymer (EVAL) using a swine endovascular embolization model. *AJNR Am J Neuroradiol* 15:1107-1115, 1994.

In this review, the authors report the use of a little-known embolic agent, Onyx, that they used to treat AVMs in 23 patients. Onyx is EVOH dissolved in the organic solvent DMSO. It is combined with tantalum powder, which provides radiopacity. The use of Onyx in treating AVMs was first reported about 10 years ago, but the agent has not yet gained widespread use (2). Several aspects of this embolic agent make it particularly attractive. Chief among these is the prospect of an embolic material that can be delivered as a slow, controlled infusion without significant risk of having the delivery catheter become entrapped. The authors report an overall favorable initial experience with this embolic agent.

We expect that this report will generate considerable controversy. The use of the organic solvent DMSO is bound to raise

concern (and it should). The authors cite previous data demonstrating that an injection of 0.8 ml of DMSO in an animal model led to vasospasm and infarction and that injections of 0.5 ml resulted in delayed subarachnoid hemorrhage (1). Nonetheless, they believe that the similar doses used in their study (0.25 ml DMSO to fill catheter dead space plus 94 to 96% DMSO in the embolic agent itself) are safe if the infusion is sufficiently slow. If so, the therapeutic window is at best relatively narrow. The finding of angioneurosis in two of their patients should also be noted. Two of their complications resulted from reflux of the agent into nontarget vessels. A better understanding of how reflux might be prevented is important. Some early users of Onyx abandoned it because of concerns about the safety of DMSO. They also noted some instances of recanalization and other instances in which the embolic agent passed through the nidus to enter the venous outflow (T Terada, personal communication, 2000).

Other aspects of the manuscript warrant comment. At our institution, it would be unusual to embolize a Spetzler-Martin Grade 1 AVM. Typically, embolization adds little benefit to surgical resection for these small AVMs, but the embolization procedure does increase morbidity (4% in this series). At our institution, it also would be unusual not to obtain postoperative angiograms after AVM resection, as was the case for three patients in this series. Overall, fewer than half of the patients reported here underwent follow-up angiography, and none underwent long-term follow-up angiography. We also wonder whether using an experimental embolic agent with an unknown long-term risk should initially be used in patients whose definitive therapy is to be radiosurgery. Did the embolization actually reduce the radiosurgery treatment volumes by amounts similar to the authors' estimate of the reduction in nidus size?

None of these comments detract from the overall interest and merit of the article. The long-term viability of embolization as a treatment modality for AVMs is contingent on the development of improved embolic agents. The data presented here suggest that Onyx deserves further evaluation.

**Felipe C. Albuquerque**  
**Cameron G. McDougall**  
*Phoenix, Arizona*

- 
1. Chaloupka JC, Viñuela F, Vinters HV, Robert J: Technical feasibility and histopathologic studies of ethylene vinyl copolymer (EVAL) using a swine endovascular embolization model. *AJNR Am J Neuroradiol* 15:1107-1115, 1994.
  2. Taki W, Yonekawa Y, Iwata H, Uno A, Yamashita K, Amemiya H: A new liquid material for embolization of arteriovenous malformations. *AJNR Am J Neuroradiol* 11:163-168, 1990.


Jahan et al. describe their experience in 23 patients with a new liquid embolic agent containing EVOH, DMSO, and tantalum powder for radiographic visualization. This material has attractive features in that the material is a nonadhesive liquid embolic material with low viscosity and can be delivered in a more controlled fashion than, for example, NBCA and other liquid acrylic agents. The flow and controlled delivery can often pre-

vent premature transit through the lesion with occlusion of the venous outflow tracts, and therefore its more controlled delivery is intuitively attractive. Although it is nonadhesive in nature, when the material encompasses the microcatheter to any significant degree, removal of the delivery catheter can be impeded, to which the authors allude in one of their illustrative cases. In addition, the early experience with radiographic visualization seems to have been solved by dispersion of the tantalum powder before delivery in the microcatheter.

Quite impressive is the 63% reduction in AVM volume in the 23 patients who were embolized. That figure becomes even more significant when one considers that the average AVM volume before embolization was 14.5 cm<sup>3</sup>. Of note, however, is that 4 of 23 patients experienced adverse events, 2 because of ischemia from inadvertent occlusion of an arterial feeding pedicle and 2

others who had transient neurologic deficits that resolved within 1 week of the procedure, thus producing a permanent morbidity rate of 4%. It should be noted that a group that is extremely experienced in AVM embolization achieved this result; therefore, the risk of using this procedure with this material cannot be underestimated and deserves great respect. With the use of any new device or treatment there is a learning curve; however, I believe that this material has a bright future in the armamentarium of the endovascular surgeon for the treatment of AVMs in the brain and spine as well as in other organ systems. The authors provide careful documentation and honest analysis of their experience.

**Robert H. Rosenwasser**  
Philadelphia, Pennsylvania



*Compartment C, Car 293* (1938), by Edward Hopper. Oil on canvas. Courtesy, IBM Corporation, Armonk, New York.