

LETTERS TO THE EDITOR

Posterior alexia after right occipitotemporal infarction

Posterior or pure alexia is an uncommon acquired reading disturbance in which the loss of the ability to read is not associated with other language deficits.¹ It has been reported almost without exception after left (dominant) hemispheric lesions involving visual temporo-occipital pathways and splenium of the corpus callosum, and is considered to be a strong lateralising feature. The explanations of this deficit are on the basis of: (a) a disconnection syndrome—that is, the lesion prevents visual information from reaching the language area, or (b) the presence of a lateralised visual language association area residing in the dominant posterior inferior temporal lobe. We describe a patient with an atypical interhemispheric organisation who developed pure alexia and features of apperceptive agnosia after a right occipitotemporal infarction.

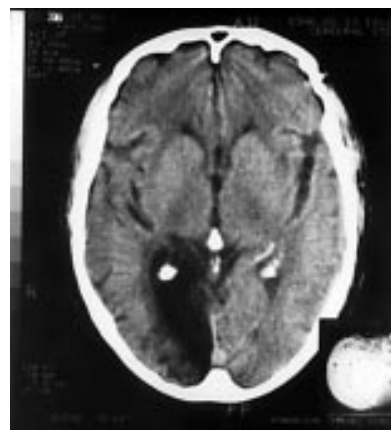
The patient is a 71 year old man, with a college degree education. He writes, uses a fork, spoon, or knife with the right hand, but prefers to use his left hand or leg for every other activity. He has no antecedents of sinistrality in first degree relatives. At the age of 68 he had a myocardial infarction complicated with an interventricular communication and heart failure. He underwent cardiac surgery and recovered. Immediately after surgery his examination showed a left visual hemianopia and he complained of inability to read. However, no neurological assessment was required at that time and no further studies were conducted.

Three years later he was referred to the neurology clinic because of a syncopal episode and further attention was then paid to his cognitive complaints. He referred that during the first year after his surgery letters were just unmeaning lines for him and he had

some confusion with numbers. Later, he learnt gradually to discriminate numbers and to recognise many letters but was still unable to put them together into syllables or meaningful words.

He was given a cognitive examination (quantified data are summarised in table 1). He was cooperative and fully oriented. On a line bisection task he scanned from left to right and upside down bisecting all lines. He had no visuospatial disorientation according to his performance in tests of the visual object and space perception battery.² Visuospatial perception and visuoconstructive tasks disclosed features consistent with apperceptive agnosia. He was able to recognise and copy simple shapes and figures (circle, cube...) but was impaired in recognising schematic drawings (for example, from the Boston naming test or cookie theft scene) or when he tried to copy more complex figures such as a house or Rey's figure. The main deficit pertained to piecing together separate visual stimuli, especially line drawings, into a whole percept. Recognition of real objects and pictures of famous people was appropriate. Colour matching was normal but he committed errors when asked to name a colour on confrontation or to point to a certain colour. Because he reported to have always had some difficulty with colour discrimination it was not certain the interpretation of this deficit was achromatopsia.

Spontaneous speech, comprehension, and repetition were normal. Confrontation naming with the Boston naming test was in the lower range disclosing very mild word finding problems (in addition to several failures clearly due to perceptual difficulties). Handwriting was meaningful and syntactically correct both spontaneously and to dictation. He was perfectly able to copy single letters and words. When trying to read, the patient was able to recognise many letters but he committed frequent errors such as between M and V, R and A, or H and R. He was unable to read syllables or simple words. On the contrary, he recognised with ease three syllable words spelled aloud by the examiner. He was able to read and to recognise numbers. Calculation was normal, with isolated errors. He had no problems distinguishing between right and left sides.



Brain CT shows an infarction in the territory of the right posterior cerebral artery involving occipital visual cortex and periventricular white matter extending to the forceps major of the corpus callosum.

Brain CT showed an old infarction in the territory of the right posterior cerebral artery involving the occipital visual cortex and periventricular white matter extending to the forceps major of the corpus callosum (figure). No lesions were found in the left hemisphere.

The development of posterior alexia and apperceptive agnosia after a right occipitotemporal infarction is exceptional—only one case has been reported, in a left handed person, by Gloning *et al*,³ and discloses a rather atypical interhemispheric organisation in this patient. Firstly, he had a right hemispheric dominance for language, which is uncommon even in left handed patients. The neuropsychological profile of his reading disorder showed the typical features of a posterior alexia due to dominant hemispheric damage. His alexia could not be explained on the basis of neglect, visuospatial disorientation, simultagnosia, or a global visual agnosia. Neither could it be due to his difficulties with complex visual perception, as he was perfectly able to copy words that afterwards he was unable to read. It is noteworthy that he was not able to recover any capability to read relying on his intact left temporo-occipital cortex.

The second remarkable deficit was consistent with the descriptions of Lissauer (1889) and of Bauer and Rubens (1985) of apperceptive agnosia.⁴ He had clear difficulties in perceiving the overall configuration of complex line figures or schematic drawings, which impaired both their copy and their recognition. This deficit could not be attributed to primary visual deficit, deficit in visual scanning, visuospatial disorientation, or just to constructional apraxia. Apperceptive agnosia is classically related to right temporo-occipital lesions whereas associative agnosia occurs after similar left lesions. All previously reported cases of posterior alexia, when accompanied by agnosic features, have been of the associative type consistent with left damage. On the contrary, this patient encompassed a striking combination of agnosic features—that is, a selective associative agnosia for words plus features of apperceptive agnosia for other complex visual stimuli. This combination of deficits suggests that reverse hemispheric dominance for language was not accompanied by reverse dominance for other functions.

Finally, the clinicoanatomical relation in this case mirrors the posterior alexia after left

Table 1 Cognitive assessment of the patient

	Results (correct/total)	Interpretation
Spatial attention/orientation:		
Line cancellation task	30/30	No neglect
VOSP†		Appropriate spatial analysis
Shape detection screening test	20/20	
Dot counting	10/10	
Number location	8/10	
Position discrimination	17/20	
Visuoconstructive abilities:		
Copy of simple drawings	2/3*	
Copy of complex Rey figure	21/36 (centile 1)*	
Visual recognition		Apperceptive agnosia *
Simple shapes	5/5	
Schematic drawings	10/15*	
Real objects	5/5	
Faces (photographs)	5/5	No prosopagnosia
Colour matching	5/5	Achromatopsia?
Colour discrimination	6/10	
Language		
Boston naming test	22‡/30	No aphasia
Writing sentences	3/3	Mild naming deficit
Reading words	0/10	No agraphia
Recognition of spelling aloud words	6/6	Posterior alexia

†Visual object and space perception battery; ‡Plus three items after phonemic clues (includes just the errors due to naming impairment).

hemispheric lesions,⁵ suggesting a similar linguistic organisation when the right hemisphere is dominant. In this patient damage to the posterior transcallosal fibres on their way to the left dominant angular gyrus and/or to the dominant occipitotemporal gyrus was also the crucial anatomical substrate in producing the syndrome of pure alexia.

ESTRELLA GÓMEZ-TORTOSA
ANTONIO DEL BARRIO

Department of Neurology, Fundación Jiménez Díaz,
Auda Reyes Católicos 2, Madrid 28040, Spain

Correspondence to: Dr E Gómez-Tortosa
egomez@meditex.es

- 1 Benson DF. Alexia. In: JAM Fredericks, ed. *Handbook of clinical neurology: clinical neuropsychology*. Vol 1. Amsterdam: Elsevier, 1985:433-55.
- 2 Warrington EK, James M. *The visual object and space perception battery*. Bury St Edmunds: Thames Valley Test Company, 1991.
- 3 Gloning I, Gloning K, Seittelberger F, et al. Ein Fall von reiner Wortblindheit mit Obduktionsbefund. *Wiener Zeitung Nervenheilkd* 1955;12: 194-215.
- 4 Bauer RM, Rubens AB. Agnosia. In: Heilman KM, Valenstein E, eds. *Clinical neuropsychology*. New York: Oxford University Press, 1985:187-241.
- 5 Binder JR, Mohr JP. The topography of callosal reading pathways. A case control analysis. *Brain* 1992;115:1807-26.

De novo partial duplication of 17p associated with Charcot-Marie-Tooth disease type 1A

Charcot-Marie-Tooth disease type 1A (CMT1A) is the most frequent form of CMT (also known as hereditary motor and sensory neuropathy, HMSN). The inheritance is autosomal dominant and is usually associated with a duplication at chromosome 17p11.2. This region contains the gene of the peripheral myelin protein 22 (PMP22) and an increased concentration of PMP22 seems to be responsible for neurological phenotype in patients with 17p11.2 duplication.¹ Therefore, a gene dosage effect is the most likely pathogenetic mechanism for CMT1A.

Partial trisomy 17p is an unusual chromosomal disorder rarely reported in Europe, the clinical features of which have not been definitely established.²⁻⁶ Growth retardation, craniofacial anomalies, and developmental delay seem to constitute a characteristic phenotype associated with this condition.⁶ Moreover, the identification of patients with 17p trisomy with a uniform demyelinating neuropathy similar to that seen in patients with CMT1A, has provided further in vivo evidence supporting the gene dosage hypothesis.⁷⁻⁹ In this report, we describe an additional case of a child with de novo partial duplication of 17p associated with CMT1A.

A 7 year old boy was born at 41 weeks of gestation by spontaneous vaginal delivery after artificial amniorrhexis. There was prenatal history of oligohydramnios. His parents were healthy and non-consanguineous and the family history for neurological or genetic diseases was negative. At the time of birth, the apgar score was 7 because he had meconium

aspiration syndrome. Physical examination showed low weight (2.755 kg, percentile 3), normal length (49.5 cm, percentile 25) and microcephaly (33 cm, percentile 3). Facial dysmorphic characters included hypertelorism, downslanted palpebral fissures, micrognathia, plane philtrum, and prominent ears. At the age of 3 months, there was a continued growth failure (weight 4.100 kg, percentile 3; length 56.5 cm, percentile 3) and a right microphthalmia and divergent strabismus were noted. At 8 months of age, there was a marked global developmental delay. At that time, cerebral echography, brain auditory evoked potentials, and MRI were within normal limits. Subsequently, the patient was sent to a centre for mentally retarded children where he has been taking intensive schooling including psychomotor and speech therapies.

In June 1999, the patient was referred to our hospital for electrophysiological evaluation to test the possibility of impairment of the peripheral nervous system. At that time, the patient had no weakness, gait disturbances, or sensory complaints but the diagnosis of partial duplication of 17p was the reason for testing. Neurological examination showed facial dysmorphic characters (as mentioned above), remarkable hyperactivity, pronounced expressive speech delay, generalised hyporeflexia, pes cavus, and incipient tibioperoneal atrophy. Gower's sign was negative. Enlarged nerves were not found. There was no sensory deficit, but detailed testing could not be performed. Electrophysiological studies were done with a MEDELEC Shappire 4 electromyographer. The EMG showed a mixed pattern and polyphasic motor unit potentials. No fibrillation potentials or positive sharp waves were found. Motor nerve conduction velocities were obtained on the patient and his mother. The patient's motor conduction velocities were uniformly slowed in the limbs and F waves were markedly delayed (table 1).

Sensory nerve conduction measurements were not done because of the child's anxiety. These findings were consistent with the presence of a demyelinating neuropathy in keeping with the diagnosis of CMT1. By contrast, his mother's median and ulnar motor nerve conduction velocities were normal (53.7 m/s and 70 m/s, respectively).

Chromosome analysis of the patient showed the presence of extra chromosomal material in 17p. Fluorescence in situ hybridisation confirmed the diagnosis of partial duplication of the short arm of chromosome 17 and demonstrated that extra material was located in the region beyond band 17p13.3. The mother's and father's karyotypes were normal. Therefore, these findings were compatible with a de novo interstitial duplication of 17p. Duplication analysis was done using microsatellite markers (D17S921 and DS17S955) from within the region of chromosome 17p11.2, known to be duplicated in CMT1A and containing the PMP22 gene. Gene dosage experiments with these microsatellite markers demonstrated that the patient

was a carrier of a chromosome 17 with 17p11.2 duplication, which is often associated with the CMT1A phenotype. His parents were heterozygous for these markers but signals of equal intensity were found for both alleles.

Most of the clinical features described here are similar to those previously detailed in several children with de novo partial duplications of 17p.²⁻⁶ All of them had low birth-weight, growth retardation, developmental delay, and craniofacial dysmorphic characters such as hypertelorism, downslanted palpebral fissures, smooth philtrum, and abnormal ears. In addition, our patient had divergent strabismus, microphthalmia, pronounced hyperactivity, and remarkable speech delay. To date, only a few cases of this rare chromosomal condition have been published and clinical data are scarce. However, our finding supports the hypothesis that partial trisomy 17p has a typical phenotype.^{5,6} Recently, some authors have also shown abnormal nerve conduction velocities in patients with this disorder.⁷⁻⁹ Therefore, we carried out an electrophysiological study to examine the status of the peripheral nerves, detecting the existence of a demyelinating neuropathy in keeping with the diagnosis of CMT1. It is important to emphasise that clinical manifestations such as weakness, gait disturbances, and sensory deficits were absent in the child. This fact strongly supports the need for electrophysiological evaluation in all patients with trisomy 17p even when the anomalies denoting the existence of peripheral nervous system impairment are absent.

Lupski *et al*⁷ studied a patient with 17p partial trisomy with decreased nerve conduction velocities whose molecular analysis showed the CMT1A duplication. On the basis of their findings, the authors hypothesised that the CMT1A phenotype resulted from a gene dosage effect. Later Chance *et al*⁸ ratified the association of trisomy 17p and CMT1A and provided further evidence supporting a gene dosage mechanism. Since then, only a few cases have been published.⁹ One of these studies examined the presence of PMP22 gene duplication in four patients with partial trisomy.⁸ Two of these patients showed slowing of conduction velocities and exhibited PMP22 gene duplication. By contrast, in two patients with normal conduction velocities the PMP22 gene was not duplicated. This investigation demonstrated that the presence of demyelinating neuropathy is directly associated with PMP22 gene duplication and corroborated the gene dosage model.

In summary, we describe another case of a patient with 17p trisomy whose electrophysiological evaluation showed the existence of a demyelinating neuropathy type CMT1. Our finding contributes support to the idea that trisomy 17p is responsible for a typical phenotype and that nerve conduction studies should be included in the routine examinations in all patients with this chromosomal disorder. In addition, our patient adds more in vivo evidence supporting a gene dosage effect in CMT1A.

We are grateful to Dr Orera for the initial cytogenetic evaluation and Dr O Combarros for his kind contribution to the bibliographic review.

J L FERNÁNDEZ-TORRE
Servicio de Neurofisiología Clínica, Hospital de
Cabueñes, Cabueñes s/n, 33394 Gijón, Spain

B OTERO
Servicio de Neuropediatría

Table 1 Results of electrophysiological studies

Nerve	Motor conduction values				
	Amp ^d (mV)	Amp ^e (mV)	DML (ms)	CV (m/s)	FL (ms)
Median	3.4	2.1	8.8	14.1	ND
Peroneal	3.6	2.8	10.5	16.0	77.9
Tibial	2.9	2.5	8.3	14.1	83.9