

5. Barnett HJ, Gunton RW, Eliasziw M, et al. Causes and severity of ischemic stroke in patients with internal carotid artery stenosis. *JAMA* 2000;283:1429–1436.

Vascular Compression as a Cause of Superior Oblique Myokymia Disclosed by Thin-Slice Magnetic Resonance Imaging

Masato Hashimoto, MD, PhD,
Kenji Ohtsuka, MD, and William F. Hoyt, MD

PURPOSE: To describe a case of superior oblique myokymia in which thin-slice magnetic resonance imaging (MRI) appeared to show vascular compression of the trochlear nerve.

METHODS: A 50-year-old woman presented with episodic monocular oscillopsia. Neuro-ophthalmologic examinations showed intermittent intorsional microtremor of her right eye, diagnosed as right superior oblique myokymia. Thin-slice (1.6 mm) MRI, using spoiled gradient recalled acquisition in the steady state, was employed to examine the trochlear nerve in its course through the ambient cistern.

RESULTS: Imaging disclosed a branch of the posterior cerebral artery immediately adjacent to the right trochlear nerve.

CONCLUSION: These magnetic resonance findings suggest that a cause of superior oblique myokymia may be vascular compression of the trunk of the trochlear nerve. (*Am J Ophthalmol* 2001;131:676–677. © 2001 by Elsevier Science Inc. All rights reserved.)

SUPERIOR OBLIQUE MYOKYMIA IS AN ACQUIRED ANOMALY of superior oblique muscle innervation causing episodic torsional oscillation of an eye. The term *superior oblique myokymia* was coined by Hoyt and Keane in 1970.¹ Since then, there have been many clinical reports of this entity.^{2,3} Although neuroimaging studies have revealed a couple of posterior fossa tumors and a dural arteriole venous fistula associated with superior oblique myokymia, none has pinpointed a possible mechanism of an anomalous trochlear discharge. In the present report, we describe a patient with superior oblique myokymia caused by vascular compression of the trochlear nerve as disclosed by thin-slice magnetic resonance imaging (MRI) of the brain stem.

Accepted for publication Oct 30, 2000.

From the Department of Ophthalmology (M.H., K.O.), Sapporo Medical University, School of Medicine, Sapporo, Hokkaido, Japan, and the Neuro-ophthalmology Unit, Department of Ophthalmology, School of Medicine, University of California, San Francisco, California (W.F.H.).

Reprint requests to Masato Hashimoto, MD, PhD, Department of Ophthalmology, Sapporo Medical University, School of Medicine, S-1, W-16, Chuo-ku, Sapporo 060, Japan; fax: 81-11-613-6575.

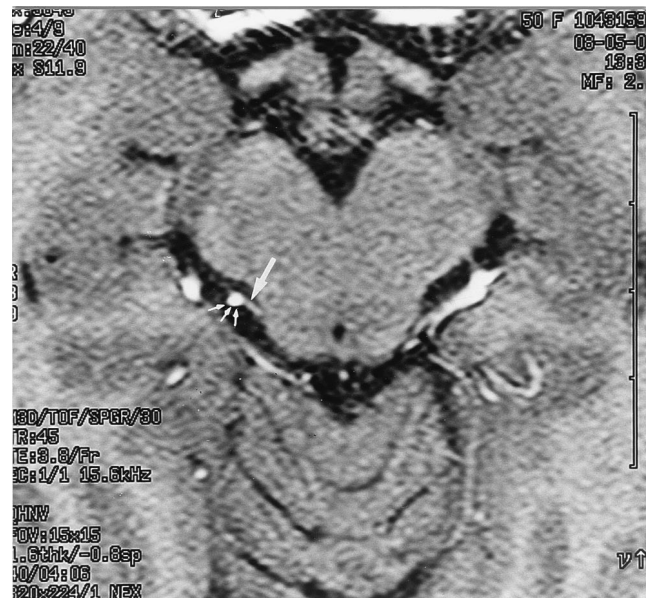

FIGURE 1. Thin-slice (1.6 mm thick) magnetic resonance imaging of the brain stem with the spoiled gradient recalled acquisition in the steady state showing that the right trochlear nerve (large arrow) is compressed by a branch of the right posterior cerebral artery (small arrows), probably the medial posterior choroidal artery, in the ambient cistern.

A 50-year-old woman who had a 13-year history of systemic hypertension complained for 3 years of a “fluttering” sensation in her right eye lasting for seconds at a time. Visual acuity, pupillary responses, and ophthalmoscopic examinations were normal. Ocular motility was full. Slit-lamp examination showed intermittent intorsional microtremor of her right eye. The microtremor was brought on by asking the patient to first look in the direction of action of superior oblique muscle and then to return the eye to the primary position. These clinical findings were consistent with a diagnosis of right superior oblique myokymia. Conventional MRI (10 mm thick, 1.5T) of her brain showed no abnormalities. To evaluate the brain stem in more detail, we used thin-slice (1.6 mm thick) MRI with the technique of spoiled gradient recalled acquisition in the steady state. This allows high-resolution T1 images and detection of arteries crossing the plane of sections as foci of high-signal intensity. The thin-slice magnetic resonance method disclosed a branch of the right posterior cerebral artery, probably the medial posterior choroidal artery, “compressing” the right trochlear nerve in the ambient cistern (Figure 1).

These neuroimaging studies suggest that compression of the trochlear nerve by a branch of the posterior cerebral artery caused the superior oblique myokymia in our patient. In previous studies, we found that thin-slice (1–2 mm thick) MRI with the spoiled gradient recalled acquisition in the steady state can show vascular compressive oculomotor and abducens nerve palsies.⁴ Neurovascular

compression of the trochlear nerve may produce spontaneous discharges in trochlear axons in the same way that it does in the facial nerve in patients with hemifacial spasms.⁵ Neuroimaging of such a lesion in a case of superior oblique myokymia has not been reported previously because it is nearly impossible to see the trochlear nerve in conventional MRI.

REFERENCES

1. Hoyt WF, Keane JR. Superior oblique myokymia: report and discussion on five cases of benign intermittent uniocular microtremor. *Arch Ophthalmol* 1970;84:461–467.
2. Leigh RJ, Tomsak RL, Seidman SH, Dell'Osso LF. Superior oblique myokymia. Quantitative characteristics of the eye movements in three patients. *Arch Ophthalmol* 1991;109:1710–1713.
3. Geis TC, Newman NJ, Dawson RC. Superior oblique myokymia associated with a dural arteriovenous fistula. *J Neuro-Ophthalmol* 1994;112:1063–1067.
4. Hashimoto M, Ohtsuka K, Akiba H, Harada K. Vascular compression of the oculomotor nerve disclosed by thin-slice magnetic resonance imaging. *Am J Ophthalmol* 1998;125:881–882.
5. Jannetta PJ. Observations on the etiology of trigeminal neuralgia, hemifacial spasms, acoustic nerve dysfunction and glossopharyngeal neuralgia: definitive microsurgical treatment and results in 117 patients. *Neurochirurgica* 1977;145–154.

Rosai–Dorfman Disease Presenting as Bilateral Lacrimal Gland Enlargement

Matthew Lee-Wing, MD, FRCSC,
Allan Oryschak, MD, FRCPC,
Gurcharan Attariwala, MD, FRCSC, and
Michael Ashenhurst, MD, FRCSC

PURPOSE: To report a patient with bilateral lacrimal gland enlargement as the initial manifestation of Rosai–Dorfman disease.

METHODS: Case report.

RESULTS: A 14-year-old female presented with left lacrimal gland enlargement followed by right lacrimal gland enlargement 11 weeks later. Bilateral lacrimal gland biopsies were performed, and histopathologic examination revealed the diagnosis of Rosai–Dorfman disease.

CONCLUSION: Patients with Rosai–Dorfman disease may present with bilateral lacrimal gland swelling in the absence of lymphadenopathy. Rosai–Dorfman disease should be considered in the differential diagnosis of bilateral lacrimal gland enlargement. (*Am J Ophthalmol* 2001;131:677–678. © 2001 by Elsevier Science Inc. All rights reserved.)

Accepted for publication Oct 17, 2000.

From the Departments of Ophthalmology (M.L.-W., G.A., M.A.) and Pathology (A.O.), University of Calgary, Calgary, Alberta, Canada, and the Department of Ophthalmology, University of Ottawa, Ottawa, Ontario, Canada (M.L.-W.).

Inquiries to A. Oryschak, MD, Calgary Laboratory Services, Rockyview Hospital, 7007 - 14th St SW, Calgary, Alberta, Canada T2V 1P9; fax: (403) 541-3333; e-mail: allan.oryschak@CLS.ab.ca

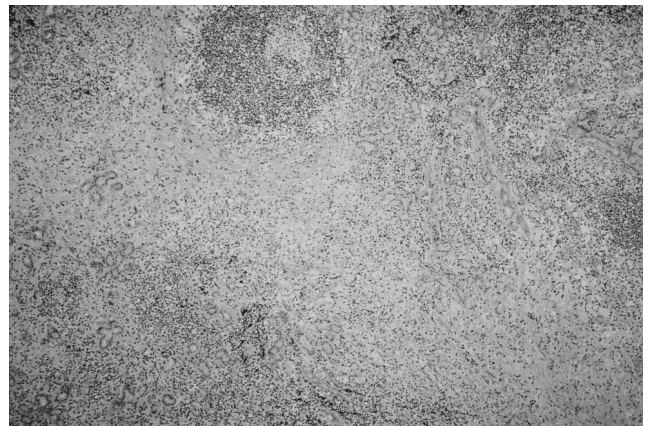


FIGURE 1. The normal lacrimal gland microarchitecture is effaced with a mixed inflammatory infiltrate, including lymphocytes, histiocytes, and plasma cells (hematoxylin and eosin, original magnification $\times 13.2$).

mol 2001;131:677–678. © 2001 by Elsevier Science Inc. All rights reserved.)

ROSAI–DORFMAN DISEASE IS A BENIGN, IDIOPATHIC DISORDER that typically affects children and young adults, producing massive bilateral cervical lymphadenopathy, fever, leukocytosis, an increased erythrocyte sedimentation rate, and hypergammaglobulinemia.^{1,2} Ophthalmologic manifestations most frequently occur in the orbit and are seen in 11% of patients with Rosai–Dorfman disease.³ In some patients, the ophthalmologic findings constitute the initial or principal feature of the disease.³ We report a patient with bilateral lacrimal gland enlargement as the initial presentation of Rosai–Dorfman disease.

A 14-year-old East Indian female presented with a swollen left orbit of several months' duration. She denied fever, diplopia, or orbital pain. Her medical history was unremarkable. On examination, a firm mass was palpable in the superotemporal left orbit. The remainder of the ocular examination was normal, and no lymphadenopathy was found. A computed tomographic (CT) scan of the orbits demonstrated an enlarged left lacrimal gland. Systemic investigations for immunologic abnormalities, the white blood cell count, and an erythrocyte sedimentation rate were normal. At operation, a multilobulated lesion involving the lacrimal gland was excised and examined histopathologically.

Eleven weeks after surgery, the patient developed a swollen right orbit. The examination revealed a firm mass in the right lacrimal gland region. The remainder of the ocular and systemic examinations was again normal with no lymphadenopathy. An excisional biopsy of the right lacrimal gland lesion was performed. The postoperative course of the patient was uneventful. However, 9 months later, she developed fever with massive bilateral swelling of the salivary glands and cervical lymphadenopathy. A