

CLINICAL NOTE

Cerebral Venous Thrombosis in Young Adults: 2 Case Reports

Ann Francine Dzialo, MD, Randie M. Black-Schaffer, MD

ABSTRACT. Dzialo AF, Black-Schaffer RM. Cerebral venous thrombosis in young adults: 2 case reports. *Arch Phys Med Rehabil* 2001;82:683-8.

Cerebral venous thrombosis (CVT) is a disease with multiple known etiologies that present with a remarkably wide spectrum of clinical signs and symptoms. We present a case of a 34-year-old man with a history of meningeal symptoms for 1 week after receiving a lumbar injection for lower back pain. He subsequently developed dense right hemiplegia and global aphasia. Head magnetic resonance imaging revealed superior sagittal sinus thrombosis. The patient was started on intravenous heparin but deteriorated neurologically. Urokinase infusion directly into the superior sagittal sinus was performed, with striking functional and neurologic improvement. Lupus anticoagulant was positive. We also present the case of a 24-year-old pregnant woman who developed an acute onset of meningeal symptoms and resultant left hemiparesis. Head magnetic resonance angiography revealed thrombosis of right transverse and sigmoid sinuses. Protein S deficiency was found. She was started on intravenous heparin, then enoxaparin, with improvement in symptoms. These cases demonstrate that CVT can be a cause of stroke in young patients with hypercoagulability disorders, and a heightened awareness of CVT will promote optimal medical care and functional outcomes. Excellent functional recovery is likely with early recognition and treatment of the underlying etiology, as well as successful lysis of the clot.

Key Words: Case report; Cranial sinuses; Heparin; Rehabilitation; Venous thrombosis.

© 2001 by the American Congress of Rehabilitation Medicine and the American Academy of Physical Medicine and Rehabilitation

CEREBRAL VENOUS THROMBOSIS (CVT) is an uncommon disease marked by clotting of blood in cerebral venous or dural sinuses, and, in rare cases, cortical veins. The first detailed description of CVT appeared in 1825 in France. Ribes¹ described a 45-year-old man with a systemic malignancy who died after a 6-month history of severe headache, epilepsy, and delirium. On postmortem examination, he was found to have suffered thrombosis of the superior sagittal sinus (SSS), left lateral sinus, and of a cortical vein in the parietal region.² Until recently, CVT was largely an autopsy diagnosis. However, with the advent of magnetic resonance imaging and angiography (MRI, MRA), it is now reliably diagnosed during life.

From the Department of Physical Medicine and Rehabilitation, Tufts University School of Medicine, Boston, MA (Dzialo); and Harvard Medical School, Boston, MA (Black-Schaffer).

Accepted in revised form May 4, 2000.

No commercial party having a direct financial interest in the results of the research supporting this article has or will confer a benefit upon the author(s) or upon any organization with which the author(s) is/are associated.

Reprint requests to Ann Francine Dzialo, MD, Dept of Physical Medicine and Rehabilitation, 750 Washington St, New England Medical Center, Box 387, Boston, MA 02111.

0003-9993/01/8205-6052\$35.00/0

doi:10.1053/apmr.2001.19244

The true incidence of CVT is unknown. A rate of 3 to 4 cases per year in a general hospital was found by Bousser et al² and 8 cases per year at a university hospital by Einhaupl and Masuhr.³ It is a fascinating disease because of its rarity, multiple causes, and wide spectrum of clinical signs and symptoms. Currently, there is no consensus on specific treatment, especially in the use of antithrombotic agents. Fortunately, the long-term prognosis of patients with CVT from all causes is good^{3,4} with better outcomes found in cases occurring during pregnancy and the puerperium.⁵

CASE REPORTS

Case 1

The first patient was a 34-year-old, left-handed man with a history of viral meningitis in 1987, and chronic low back pain secondary to a motor vehicle crash in 1998. Thirty minutes after receiving a lumbar epidural steroid injection for chronic low back pain, he developed severe, persistent, occipital headache, and neck pain with stiffness. The patient stayed in bed because his pain was relieved by resting in the supine position and with narcotic analgesics. At the end of a week, he developed fever, chills, nausea, and nonprojectile vomiting. These symptoms persisted for 3 days, with progressive worsening of his headache and neck stiffness to the point where they were unrelieved by position and analgesics. A blood patch was planned for presumed cerebrospinal fluid (CSF) leakage.

The next day he presented to the emergency room where a lumbar puncture was performed, and he was admitted. Lumbar CSF, blood, urine, and sputum cultures were negative for infectious meningitis. The blood patch was not performed. A lumbar MRI was recommended, but the patient refused. On arrival to the medical floor, he suffered a grand mal seizure. An emergent head MRI revealed complete SSS thrombosis (fig 1).

A head computed tomography (CT) showed an evolving left frontal hemorrhagic infarct (fig 2). The patient also had a lumbar MRI that showed no lumbar paraspinal or epidural abscess. He was given a loading dose of phenytoin and started on mannitol and heparin. The following day he developed global aphasia, right hemiplegia, papilledema, and bilateral positive Babinski signs. A cerebral angiogram was performed that showed absent filling of the SSS (fig 3).

At this point, because of the patient's progressive clinical deterioration, urokinase was infused directly into the SSS via the right femoral vessels to disrupt the extensive clot mechanically and chemically. A total of 4 million units of urokinase was given as a continuous infusion, in addition to systemic heparin for 4 days. The patient was then started on warfarin, and heparin was discontinued when the international normalized ratio (INR) was therapeutic. A follow-up cerebral angiogram and head CT revealed successful lysis of the clot within the SSS (fig 4). Mannitol was then tapered. Phenytoin was stopped after the patient developed a rash and chemical pancreatitis, and carbamazepine was started for seizure control.

One day after urokinase infusion, the patient was alert, able to follow commands, and the right hemiplegia and bilateral positive Babinski signs resolved. He complained of left groin pain. An abdominal and pelvic CT was performed. This re-

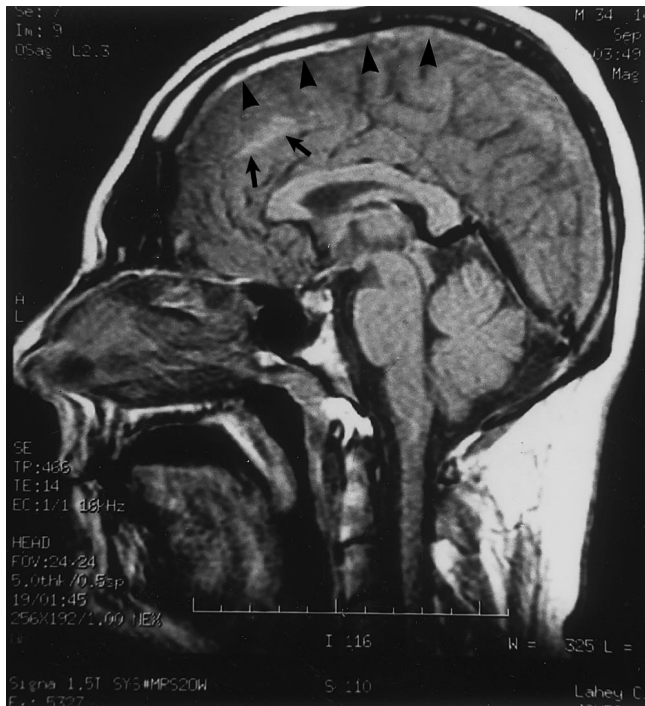

Fig 1. Sagittal midline MRI T1-weighted image showing absent flow void in the expected location of the SSS (arrowheads); signal characteristics represent hemorrhages in various stages of decay. Also shown is a right frontal hemorrhagic infarction (arrows).

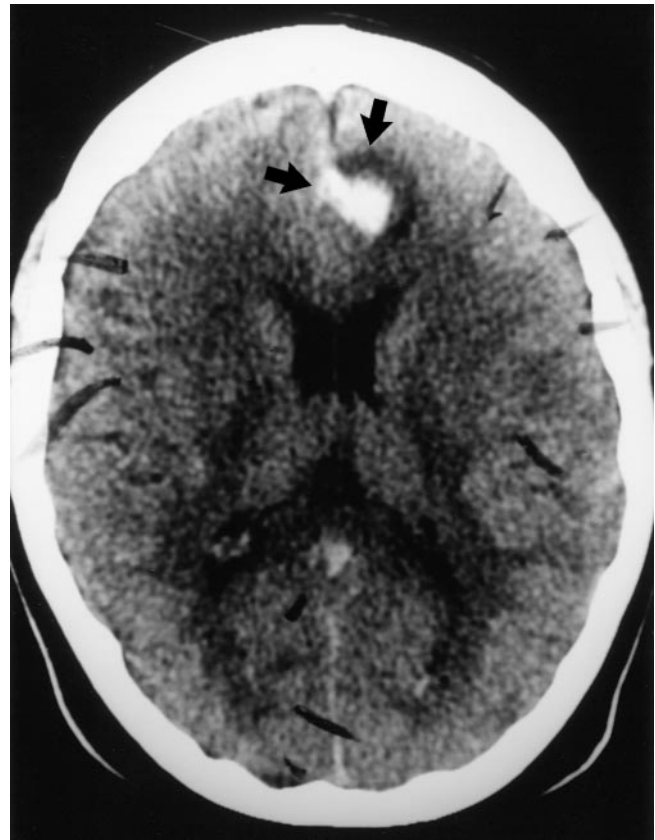


Fig 2. Unenhanced CT scan of the brain shows an approximately 2-cm area of hyperdensity surrounded by hypodensity in the inferior left frontal lobe (arrows). This represents an area of hemorrhage and surrounding ring of edema.

vealed a stable hematoma of the left iliopsoas and suspected right psoas hematoma.

The patient had no further episodes of headache, seizures, or stiff neck. His cognitive function returned to its premonitory level. Neurologically, he had numbness of the left lower extremity believed secondary to left iliopsoas hematoma, with minor weakness of hip flexion. He was changed from warfarin to enoxaparin for long-term anticoagulation the day before discharge. On further investigation for coagulopathy, he was found to be positive for the lupus anticoagulant. He was transferred to a rehabilitation hospital for comprehensive rehabilitation.

On admission to rehabilitation, motor strength was 4+/5 in the hip flexors and extensors bilaterally, with hip extension limited to -10° on both sides by pain from the bilateral iliopsoas hematoma. The left leg and hip numbness persisted, but with no sensory loss shown on examination. He was able to ambulate 20 feet by using a rolling walker and required minimum assistance with transfers and activities of daily living (ADLs). His cognitive and communication skills were assessed to be at his baseline level.

His functional status improved greatly during his 6-day inpatient rehabilitation stay, and he met the goals of independence in ambulation and ADLs. By the time of discharge, the patient was ambulating 1200 feet independently with no assistive device, and able to walk up and down 18 stairs independently. His FIM™ instrument score improved 30 points over the 6 days, for a FIM efficiency score of 5.0 points gained per day of rehabilitation. Left leg numbness persisted. He was discharged on enoxaparin. The patient, however, did not take enoxaparin because of the cost. Two days later, he developed right leg pain. This progressed over the ensuing 48 hours to right then left upper quadrant abdominal pain with deep inspiration, fever, and night sweats.

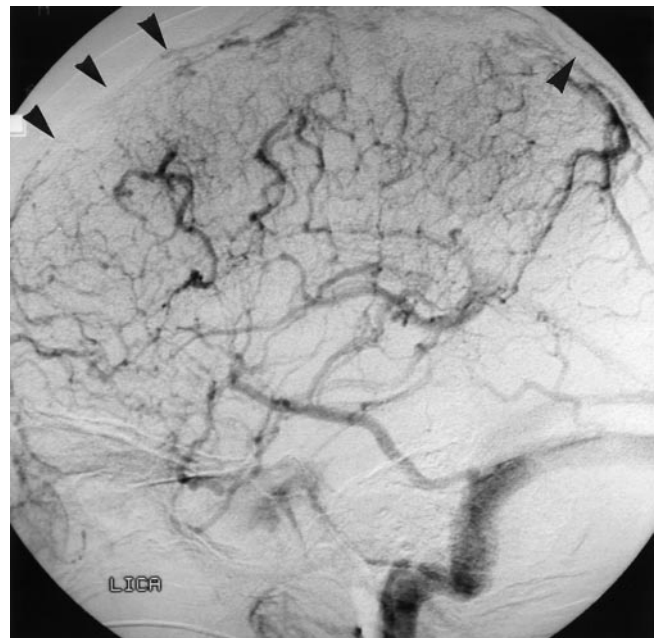

Fig 3. Lateral view of left internal carotid artery angiogram shows absent filling of the SSS (arrowheads).

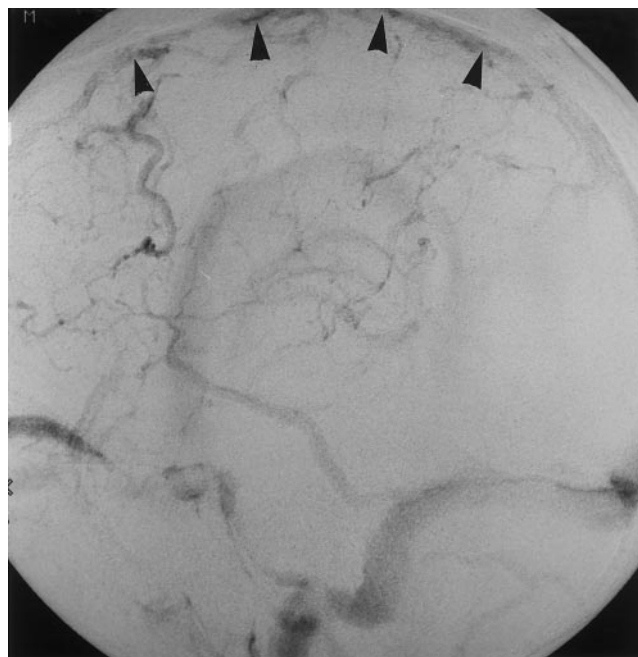


Fig 4. Lateral view of right internal carotid artery angiogram shows filling of the SSS (arrowheads). This image was obtained after rokinase treatment.

On the fourth day postrehabilitation discharge, he was readmitted to an acute hospital. He was clinically diagnosed with right leg deep venous thrombosis. CT of the chest revealed bilateral pulmonary emboli (PE); these were also seen on ventilation and perfusion lung scan. He was started on systemic heparin and an inferior vena cava filter was inserted infrarenally. Anticoagulation was changed from heparin to warfarin when the INR was between 2 and 3. The patient was advised to continue warfarin indefinitely. At 9-month follow-up, he had residual left leg numbness but had returned to his previous construction job, modified to allow driving trucks but no heavy equipment lifting because of his left leg numbness.

Case 2

A 24-year-old woman who was 12 weeks pregnant, with a medical history remarkable for migraine headaches, developed acute onset of bilateral numbness below her knees. This lasted 30 minutes and was accompanied by bilateral frontal headache, nausea, and vomiting. Nine days later she again had the abrupt onset of the same symptoms and, in addition, dizziness and inability to follow simple commands. She took acetaminophen on the advice of her physician and lay down. Symptoms improved over several hours.

Five days later, she had a tonic-clonic seizure, witnessed by her husband. When she regained consciousness, her left arm and leg were weak. She was taken to the hospital and had 2 more grand mal seizures in the emergency ward. She was given a loading dose of phenytoin and phenobarbital. A lumbar puncture was negative for signs of infection or hemorrhage. A head CT revealed blood in the subarachnoid space with a hypodense area in the right hemisphere and increased frontotemporal edema. An angiogram was negative. A head MRI showed a frontotemporal area of increased signal and edema. Systemic dexamethasone (Decadron) and mannitol were started. A head MRA was positive for thrombosis in the right

transverse and sigmoid sinus, with poor signal in the straight sinus. Systemic heparin was initiated and coagulopathy workup was performed. On examination, she had 0/5 strength on her left upper and lower extremity with sensation intact. She was lethargic, but arousable and oriented times 3.

This patient was found to have a protein S deficiency and was treated with intravenous heparin, after which she showed dramatic clinical improvement. By the time of discharge from acute hospital, her motor strength improved to 4/5 on left upper and lower extremity. Anticoagulation was changed to enoxaparin before transfer to the rehabilitation hospital.

On admission, she was able to ambulate 50 feet without a device, with transfers and ADLs requiring minimum assistance. Motor strength remained 4/5 on the left upper and lower extremities and deep tendon reflexes showed hyperreflexia, also on the left side. Sensory function was intact to pinprick, light touch, proprioception, and stereognosis on examination. Cognitive function was evaluated to be at her baseline level. The patient had continued headaches, consistent with her history of migraines. She had no further seizures and remained medically stable.

By the time of discharge home after 27 days of inpatient rehabilitation, the patient met the goals of walking independently farther than 500 feet without a device and independence in ADLs. Her FIM score improved 46 points, for a FIM efficiency score of 1.7 points gained per day of rehabilitation. Neurologically, she showed mild residual left upper extremity weakness. She continued on enoxaparin upon discharge for the duration of her pregnancy and postpartum with no further thrombotic events. Six weeks postpartum, protein S level was re-measured and had normalized. She continued on enoxaparin. At 10 month follow-up, she had no neurologic or functional deficits. Anticoagulation was changed from enoxaparin to warfarin because of her preference for oral anticoagulation and continued for 6 more months on the advice of her hematologist.

DISCUSSION

CVT is most likely to occur in adults younger than 45 years old.^{6,7} Prognosis for recovery of function is favorable with early therapeutic intervention. Most patients recover fully.^{2,8,9} Retrospective studies of CVT treatment and outcome are summarized in table 1.

CVT affects all ages. There is an increased incidence in young women (perhaps reflective of oral contraceptive use and pregnancy) and in the aged of both sexes; the women to men ratio is 1.3:1.^{2,9-12} There are numerous causes of CVT. The infectious etiologies include septic cranial trauma, meningitis, intracranial infection, cerebritis, septicemia, otitis, tonsillitis, and sinusitis. These may be of bacterial, fungal, viral, and parasitic origin.^{9,13} Of the noninfective causes, malignancies (eg, meningioma, carcinoid, leukemia, lymphoma), red cell and platelet disorders (eg, polycythemia, sickle cell disease, thrombocytopenia), inflammatory disease (eg, Behçet's disease), and connective tissue diseases (eg, systemic lupus) are the most frequent.^{9,13} Additional causes of CVT include pregnancy, the puerperium, oral contraceptives, coagulopathies (as in the 2 cases reported in this article), head injury, and severe dehydration.^{9,13}

The clinical presentation varies with the location and extent of the sinuses involved. The most common signs of CVT are headache, papilledema, focal motor or sensory deficits, and seizures.^{2,3,5,9,13-18} Several patterns of clinical presentation have been defined and are presented in table 2.^{2,13,14}

The clinical presentation may have acute, subacute, or chronic phases depending on the site and extent of thrombosis of dural sinuses and cortical veins. Thrombosis tends to occur

Table 1: Retrospective Studies of CVT

Study	No. of Patients	Complete Recovery %	Study Outcome	
			Complications	Treated With Heparin % Outcome in Heparin-Treated Patients
Ameri and Bousser ⁹	110	77	17% with optic atrophy or hemiparesis	75 No worsening
Preter et al ⁴	77	86	14% with optic trophy, seizures, focal hemispheric deficits, or neuropsychiatric disturbances	80 Minimal sequelae
Bousser et al ²	38	71	18% with hemiparesis, dysphagia, blindness caused by optic atrophy, or brainstem signs	61 No worsening
Partziguian et al ⁷	9	89	11% with severe left hemiparesis and bradyphasia	44 Unclear

more frequently in dural sinuses than cerebral veins, and in most cases affects more than 1 sinus.¹⁴

In the article by Bousser et al,² onset was subacute in patients with an isolated sinus occlusion, as in SSS thrombosis. These patients presented more frequently with headache and papilledema mimicking isolated intracranial hypertension than with focal signs. In contrast, onset of symptoms was acute in those who developed isolated thrombosis of cerebral veins. These patients presented mainly with focal deficits, seizures, or both. In the 2 cases presented here, the headache and papilledema appeared to be caused by thrombosis of dural sinuses.

Thrombosis of dural sinuses can cause intracranial hypertension by impairing absorption of CSF. This impairment occurs when the absorption of CSF, via the arachnoid granulations protruding into the sinus, becomes obstructed by nearby thrombus within the sinus itself. If the sinus thrombus extends backward into the tributary cerebral and cortical veins, these may occlude and increase cerebral venous pressure. This may further result in hemorrhagic cortical infarction and subdural, subarachnoid, or intracerebral hemorrhage.¹³ The classic anatomic presentation of CVT is bilateral, superior hemisphere hemorrhagic infarctions, caused by thrombosis of the SSS with extension into its tributary cortical veins.¹³ The seizure activity and focal deficits in the 2 cases reported were most likely caused by the retrograde extension of the dural sinus thrombus into the cortical veins with left frontal infarction occurring in the first case, and subarachnoid hemorrhage in the second case.

The first case reported shows the classic evolution of SSS thrombosis. The patient developed an initial subacute phase lasting 14 days, then progressed to an acute phase, with rapid

development of grand mal seizure and hemiparesis. The stroke symptoms occurred despite intravenous heparinization, and prompted direct endovascular thrombolysis of the SSS with urokinase. This treatment resulted in striking functional and neurologic improvement. Lupus anticoagulant positivity was elucidated as the cause of the SSS thrombosis and life-long anticoagulation was initiated.

The young woman in the second case presented in the hypercoagulable condition of pregnancy. Her symptoms progressed over a week from meningeal signs and left-sided weakness to dense left hemiplegia, confusion, and seizures. She was found to have 3 venous sinuses affected with evidence of nonhemorrhagic right hemisphere infarct, and blood in the subarachnoid space. The patient was treated successfully with systemic heparinization and had near complete resolution of left hemiparesis and improved cognition. She had protein S deficiency, which is common in pregnancy and the puerperium.⁷ She recovered to independent levels in all areas of mobility with rehabilitation.

These cases show the importance of recognizing stroke symptoms as potential indicators of CVT in young adults. Because the clinical presentation, onset, and severity of CVT vary, the diagnosis can be missed. Early intervention can halt the progression of CVT, as seen in the first case with direct infusion of urokinase into the SSS, especially in patients refractory to heparinization. MRI is considered the gold standard for diagnosis of CVT, being superior to angiography because of the direct visualization of the thrombosed dural sinuses.¹⁹ Unfortunately, urokinase has become unavailable in the United States since the first case occurred. The US Food and Drug Administration halted manufacture of urokinase in November,

Table 2: Clinical Patterns of CVT

Localization of Thrombus	Clinical Features	Onset	% of Cases
Superior sagittal, transverse, or straight sinus	Intracranial hypertension Diffuse headache Vomiting Papilledema Abducens-nerve palsy	Days to months or years	30%–40%
Cortical veins or arteries	Focal deficits Motor Sensory Seizures	Minutes to days, especially in arterial clots, or weeks to months	50%–60%
Cavernous sinus thrombosis	Chemosis Proptosis Abducens nerve palsy Painful ophthalmoplegia	Days to weeks	10%–20%

1998 because of an instance of reovirus contamination. Tissue plasminogen activator is now used in place of urokinase.

Individualized treatment will depend on the underlying cause, and may include supportive measures, antithrombotics, and thrombolytics, in that order.

The first published use of heparin for treatment of puerperal SSS was in 1942 by Stansfield.²⁰ Treatment with heparin since then has remained controversial for 2 reasons. First, the course of CVT varies; it may lead to benign intracranial hypertension and require no intervention. Second, there is a risk of further bleeding into an already hemorrhagic infarct.^{2,9,13,16,21-23} Heparin shows no thrombolytic activity, but is thought to prevent the progression and extension of thrombus into adjacent veins. It is usually initiated as soon as the diagnosis of CVT is established. The first randomized blinded study of weight-adjusted heparin versus placebo (10 patients in each group) for treatment of venous sinus thrombosis (VST) was terminated after 3 months because 8 of 10 heparin-treated patients, and only 1 of 10 in the placebo group, had complete neurologic recovery.²⁴ In Einhaupl's further retrospective study,²⁴ 14 of 27 patients who had VST and intracranial hemorrhage and were treated with systemic heparin recovered completely. Although controversy persists, most studies agree that heparin is the drug of choice and mainstay of treatment for CVT, even in patients with hemorrhagic infarct.^{2,3,6,9,13,14,17,19,20,24} Most studies have found complete or nearly complete recovery in more than 70% of cases of CVT treated with systemic heparinization.^{3,9,11,15,17}

Systemic heparin is usually continued until the patient shows clinical improvement or stabilization, and then changed to warfarin or enoxaparin, as in the earlier-mentioned cases. At present, there are no controlled studies addressing the optimum duration of anticoagulant treatment or studies comparing the effectiveness of warfarin versus enoxaparin after heparinization. Most studies agree with a 3-month course of anticoagulation, with a longer duration in the presence of a coagulopathy.^{3,9,14,15} PE can be a fatal complication if CVT is not diagnosed and treated early. In a literature review of 203 patients with intracranial venous thrombosis from 1942 to 1990, Diaz et al²⁵ found 23 cases (11.3%) associated with PE. These had a mortality rate of 95.6%; the only patient who survived was on anticoagulation treatment. Of interest, 2 of the patients who died were on anticoagulation.²⁵

Treatment using recombinant tissue plasminogen activator or urokinase intravenously or directly inserted into the thrombosed sinus is more controversial. These treatments were found in some studies to be dangerous because of greater hemorrhagic risk,¹⁶ especially with pretreatment evidence of an infarct,²⁶ but in other studies to be helpful by dissolving the existing thrombus and correlating with good clinical recovery.^{18,27-29} In cases of progressive neurologic dysfunction with extensive dural sinus thrombosis despite adequate systemic heparin, as in case 1, most advocate local thrombolysis because this can result in clot lysis and improve an otherwise poor prognosis.

The cost to the patient of long-term anticoagulation can be a factor in the clinical outcome of CVT, as it was in case 1 in which DVT and bilateral PE developed shortly after enoxaparin was stopped. Studies are needed to compare the effectiveness and cost of warfarin and low molecular weight heparinoids as long-term treatments. Until then, warfarin remains the first-line of treatment for CVT.¹⁹

Rehabilitation treatment of CVT addresses the specific functional, neurologic, and cognitive deficits identified in the patient with the standard physical, occupational, and speech therapy techniques. Neuropsychologic, driving, and vocational rehabilitation assessment are important adjuncts for the high-

level patient who hopes to return to work and community activities.

CONCLUSION

CVT is an unusual cause of stroke symptoms in young adults and should be considered in the differential diagnosis of new onset of headache, focal neurologic deficits, and seizures. Investigations into the cause should include coagulopathy studies. The detection of a coagulation disorder would dictate specific long-term clinical management strategies to prevent future thrombotic episodes. Further clinical studies are warranted to compare the effectiveness of different anticoagulant treatments for long-term management.

A heightened awareness of CVT in young adults and its various modes of presentation will promote optimal medical care and functional outcomes. Rehabilitation clinicians need to be aware of the clinical patterns of neurologic deficits that occur in CVT so that they can promptly identify and effectively treat these problems with appropriate rehabilitation methodologies. Excellent functional recovery from CVT in young adults is likely with early recognition and treatment of the underlying cause, successful lysis of the clot, and prompt rehabilitation treatment of residual functional and neurologic deficits.

Acknowledgments: The authors thank In Sup Choi, MD, and Joshua A. Hirsch, MD, for providing the figures and legends.

References

- Ribes MF. Des recherches faites sur la phlébite. *Rev Med Française Etrangère J Clin l'Hotel-Dieu Charité Paris* 1825;3:5.
- Bousser MG, Chiras J, Bories J, Castaigne P. Cerebral venous thrombosis: a review of 38 cases. *Stroke* 1985;16:199-213.
- Einhaupl KM, Masuhr F. Cerebral venous and sinus thrombosis: an update. *Eur J Neurol* 1994;1:109-26.
- Preter M, Tzourio C, Ameri A, Bousser MG. Long-term prognosis in cerebral venous thrombosis: follow-up of 77 patients. *Stroke* 1996;27:243-6.
- Cantu C, Barinagarrementeria F. Cerebral venous thrombosis associated with pregnancy and puerperium: review of 67 cases. *Stroke* 1993;24:1880-4.
- Leno C, Berciano J, Combarros O, Polo JM, Pascual J, Quintana F, et al. A prospective study of stroke in young adults in Cantabria, Spain. *Stroke* 1993;24:792-5.
- Partziguian T, Camerlingo M, Casto L, Censori B, Gazzaniga GC, Belloni G, et al. Cerebral venous thrombosis in young adults: experience in a stroke unit 1988-1994. *Ital J Neurol Sci* 1996;17:419-22.
- Bousser MG, Ross RR. Cerebral venous thrombosis. Vol I. London: WB Saunders; 1997.
- Ameri A, Bousser MG. Cerebral venous thrombosis. *Neurol Clin* 1992;10:87-111.
- Estanol B, Rodriguez A, Conte G, Aleman JM, Loyo M, Pizzuto J. Intracranial venous thrombosis in young women. *Stroke* 1979;10:680-4.
- Kalbag RM, Woolf AL. Cerebral venous thrombosis. Vol I. London: Oxford Univ Pr; 1967.
- Towbin A. The syndrome of latent cerebral venous thrombosis: its frequency and relation to age and congestive heart failure. *Stroke* 1973;4:419-30.
- Bousser MG, Barnett HJM. Cerebral venous thrombosis. In: Barnett HJM, Mohr JP, Stein BM, Yatsu FM, editors. *Stroke: pathophysiology, diagnosis, and management*. 2nd ed. New York: Churchill Livingstone; 1992. p. 517-37.
- Bousser MG. Cerebral venous thrombosis. In: Welch KMA, Caplan LR, Reis DJ, Siesjo BK, Weir B, editors. *Primer on cerebrovascular diseases*. San Diego: Academic Pr; 1997. p. 385-9.
- Daif A, Awada A, Al-Rajeh S, Abduljabbar M, Rahan ARA, Obeid T, et al. Cerebral venous thrombosis in adults: a study of 40 cases from Saudi Arabia. *Stroke* 1995;27:1193-5.
- Gettelfinger DM, Kokmen E. Superior sagittal sinus thrombosis. *Arch Neurol* 1977;34:2-6.

17. Brucker AB, Vollert-Rogenhofer H, Wagner M, Stieglbauer K, Felber S, Trenkler J, et al. Heparin treatment in acute cerebral sinus venous thrombosis: a retrospective clinical and MR analysis of 42 cases. *Cerebrovasc Dis* 1998;8:331-7.
18. Horowitz M, Purdy P, Unwin H, Carstens G III, Greenlee R, Hise J, et al. Treatment of dural sinus thrombosis using selective catheterization and urokinase. *Ann Neurol* 1995;38:58-67.
19. Bousser MG. Cerebral venous thrombosis: nothing, heparin or local thrombolysis? [editorial]. *Stroke* 1999;30:481-3.
20. Stansfield FR. Puerperal cerebral venous thrombosis treated with heparin. *Br Med J* 1942;1:436-8.
21. Easton JD. Treatment of cerebral venous thrombosis. *Cerebrovasc Dis* 1993;3:329-33.
22. Barnett HJM, Hyland HH. Noninfective intracranial venous thrombosis. *Brain* 1953;76:36-49.
23. Buchanan DS, Brazinsky JH. Dural sinus and cerebral venous thrombosis: incidence in young women receiving oral contraceptives. *Arch Neurol* 1970;22:440-4.
24. Einhaupl KM, Villringer A, Meister W, Mehraein S, Garner C, Pellkofer M, et al. Heparin treatment in sinus venous thrombosis. *Lancet* 1991;338:597-600.
25. Diaz JM, Schiffman JS, Urban ES, Maccario M. Superior sagittal sinus thrombosis and pulmonary embolism: a syndrome rediscovered. *Acta Neurol Scand* 1992;86:390-6.
26. Frey JL, Juro GJ, McDougall CG, Dean BL, Jahnke HK. Cerebral venous thrombosis: combined intrathrombus rtPA and intravenous heparin. *Stroke* 1999;30:489-94.
27. Di Rocco C, Iannelli A, Leone G, Moschini M, Valori VM. Heparin-urokinase treatment in aseptic dural sinus thrombosis. *Arch Neurol* 1981;38:431-5.
28. Vines RS, Davis DO. Clinical-radiological correlation in cerebral venous occlusive disease. *Radiology* 1971;98:9-22.
29. Scott JA, Pascuzzi RM, Hall PV, Becker GJ. Treatment of dural sinus thrombosis with local urokinase infusion. *J Neurosurg* 1988;68:284-7.