

## CASE REPORT

# Absent Relative Afferent Pupillary Defect in an Asymptomatic Case of Lateral Chiasmal Syndrome from Cerebral Aneurysm

EULOGIO BESADA, OD, MSc, FAAO and JEROME P. FISHER, MD, FACS

*Nova Southeastern University College of Optometry, North Miami Beach, Florida*

**ABSTRACT:** *Introduction.* This report documents a case of an asymptomatic 34-year-old female who had right eye subtle temporal optic nerve pallor with absent clinically detectable relative afferent pupillary defect. *Case Report.* This presentation was secondary to a fusiform paraclinoid aneurysm resulting in lateral chiasmal syndrome. Visual fields demonstrated a nasal depression OD. Neuroimaging studies revealed the presence of a fusiform paraclinoid aneurysm compressing the right optic nerve and optic chiasm. The lesion was treated surgically without additional visual loss nor systemic and neurological complications. *Conclusions.* A clinically detectable relative afferent pupillary defect may be absent in unilateral optic nerve pallor and/or visual field loss and does not preclude the need to attempt to identify an underlying etiology. Neuroradiological examination of orbital and cranial structures is an imperative protocol in the appropriate management of this potential life- and vision-threatening condition. (*Optom Vis Sci* 2001;78:195-205)

**Key Words:** aneurysms, Chiasmal syndrome, relative afferent pupillary defect, pupillary reflexes, optic nerve relative hypoplasia, visual field loss

The anatomical position of the optic chiasm makes it vulnerable to insults originating from diverse proximal processes. Pituitary adenomas, supracellar meningiomas, craniopharyngiomas, and aneurysms are among the varied intrinsic disease entities that may exert their damaging influence on the chiasm.<sup>1-4</sup> Ocular symptoms and signs exhibited by patients with these maladies may demonstrate a broad range of severity over the course of their disease. The constellation of signs and symptoms associated with these chiasmal lesions have been characterized as chiasmal syndrome (Table 1). Signs that may accompany chiasmal syndrome include optic disc atrophy, papilledema, oculomotor disturbances, and exophthalmus.<sup>1-4</sup> Lateral chiasmal syndrome may be described as a variety of the chiasmal syndrome.<sup>5</sup> In lateral chiasmal syndrome, signs and symptoms are a consequence of a space-occupying lesion causing compression on the lateral aspect of the chiasm. For example, upward and medial enlargement of supraclinoid aneurysms may give rise to this clinical entity. The ipsilateral eye is principally affected with loss of vision. Nasal hemianopsia and central scotoma may occur with varying degrees of severity. Crossing fibers corresponding to the lower retina of the contralateral eye may become involved, causing a superior temporal field loss.

A relative afferent pupillary defect (RAPD) is indicative of a

conduction deficit of the light stimuli relative to the contralateral eye through the afferent pupillary pathway. In unilateral or asymmetric optic nerve disease a RAPD should be expected in the affected eye.<sup>6,7</sup> Utilizing neutral-density filters, the RAPD depth has been quantified.<sup>6</sup> Levin et al<sup>8</sup> quantified and correlated optic nerve damage with pupillary responses in three patients with intracranial mass lesions. They estimated that a twofold to threefold difference in the number of axons may be sufficient to produce a RAPD. However, the specific amount of unilateral or asymmetric axonal loss needed to have a clinically detectable RAPD has not been quantified.

The RAPD has been correlated with the depth and magnitude of visual field loss. Thompson et al.<sup>9</sup> described a linear relationship between the amount of unilateral visual field loss determined by Goldmann perimetry and the magnitude of the RAPD. Nonetheless, absence of a RAPD has been documented in cases of severe monocular temporal visual field loss resulting from lesions of the pregeniculate visual pathway. These lesions include ischemic optic neuropathy, craniopharyngioma, pituitary adenoma, unilateral postpapilledema optic atrophy, and traumatic optic neuropathy.<sup>10,11</sup> We document a case of subtle unilateral optic atrophy and visual field loss secondary to a paraclinoid fusiform aneurysm in a patient without a clinically detectable RAPD. This case report

emphasizes the need for further diagnostic testing in cases of optic nerve atrophy (pallor) and discusses how a clinically detectable RAPD may be absent in unilateral or asymmetric cases, possibly confounding a diagnosis. Theories that may explain the absence of a RAPD in this case are further discussed.

## CASE REPORT

A 34-year-old Hispanic female presented for a routine eye examination. The patient reported unremarkable physical health and no use of medications. The patient indicated no neurological symptoms, trauma, serious episodes of systemic hypotension, or deep vein thrombosis. She did mention a history of migraine headaches. Family history was positive for an aortic arch aneurysm in her brother who was treated surgically at age 32 but did not reveal the congenital vs. acquired nature of the condition.

Best corrected visual acuity was OD 20/20 and OS 20/20. Preliminary tests (cover test, confrontation visual fields, ductions, and versions) were unremarkable OU. Pupils were 3 mm round, with 3+ response to light direct and consensual, and without a clinically detectable RAPD. The swinging flashlight test was used to test and interpret the afferent pupillary response as described in the literature.<sup>6</sup> This test was performed in a darkened room, with a moderately rapid swing and equal pause times (about 3 s) between the eyes. The criterion for diagnosing and grading a RAPD used the following general guidelines: (1) presence of asymmetry between the light reaction in each eye; (2) the eye with weaker reaction is considered to have an RAPD if it demonstrates a weaker initial constriction with a greater redilation (grade I); an initial stall with a greater redilation (grade II); an initial immediate dilation (grade III); with prolonged pause time in the good eye (about 6 s) an immediate dilation followed by a secondary constriction (grade IV); and an immediate dilation with no secondary constriction (grade V). Slitlamp examination revealed normal anatomy with a deep and quiet anterior chamber OD and OS. Goldman applanation tonometry readings were 13 mm Hg OD and OS. Dilated fundus examination demonstrated normal retinal anatomy OD and OS with optic nerve cup/disc ratios of 0.45/0.45 OD and 0.3/0.3 OS. Optic nerve hypoplasia OS was evident relative to the right eye in addition to being slightly tilted. Distinct and sharp disc margins were noted OU. Mild temporal optic disc pallor was observed in the right eye. Due to relative hypoplasia, the scleral crescent was more visible in the left eye, but otherwise healthy rim coloration was evident OS (Fig. 1). Humphrey 30-2 visual field demonstrated a moderate nasal depression, generalized constriction, and reduced central reference level in the right eye consistent with temporal optic nerve atrophy. The left eye visual field demonstrated mild generalized constriction (Fig. 2). Neuroophthalmological consultation was obtained, which confirmed the above findings. Contrast magnetic resonance imaging studies followed by magnetic resonance angiogram were ordered, and results demonstrated the presence of a 2.5-cm right paraclinoid fusiform aneurysm that elevated and compressed the right optic nerve and the optic chiasm (Fig. 3). Visual evoked potential (VEP) demonstrated approximately symmetrical amplitudes and latencies OD and OS. The patient was referred for neurosurgery, and the aneurysm was treated surgically by carotid trapping. She made a full recovery without additional loss of visual function or acuity. Follow-up

examination 1 year after the surgery revealed moderate temporal optic nerve pallor OD, unchanged optic nerve appearance from the initial visit OS (Fig. 4), 20/20 corrected visual acuity OD and OS, right eye visual field demonstrating a mild nasal depression with generalized constriction, and an essentially normal visual field OS (Fig. 5). No clinical detectable RAPD was observed after recovery from surgery.

## DISCUSSION

Aneurysms in proximity to the chiasm are among the lesions that may provoke morbidity of the visual system and potential mortality. These vascular lesions may arise from the intracranial segment of the internal carotid, anterior communicating arteries, or the middle or anterior cerebral arteries. If large enough, aneurysms situated near the chiasm may simulate suprasellar neoplasms.<sup>1-4</sup> Morphologically, aneurysms may be subdivided into saccular and fusiform types. Saccular, or berry, aneurysms are histologically characterized by defects in the elastic and muscular coat at the origin (aneurysm neck) site of the affected artery. Degenerative changes of the arterial wall, elastic tissue defects, and hypertension have all been associated with the pathogenesis of saccular aneurysms. Fusiform aneurysms are characterized by arterial elongation and tortuous dilation. Arteriosclerosis has been linked to the formation of fusiform aneurysms, which have also been described as arteriosclerotic aneurysms. The pathological insult caused by fusiform aneurysms is frequently derived from pressure exerted on adjacent vital structures rather than actual rupture resulting in subarachnoid hemorrhage.<sup>3</sup>

Aneurysms have also been categorized as either congenital or acquired. The term congenital aneurysm may actually be incorrect because it is a weakness of the arterial wall that is present at birth rather than the aneurysm itself.<sup>12</sup> Arterial aneurysm resulting from a congenital abnormality may be classified into primary and secondary aneurysm (Table 2). Primary arterial aneurysms may manifest in congenital abnormalities of connective tissue (e.g., Marfan's, Ehlers-Danlos, "marfanoid hypermobility" syndromes, and pseudoxanthoma elasticum) and as an isolated defect in the arterial wall structure (fibrodysplasia). Secondary arterial aneurysms develop as a consequence of hemodynamic turbulences arising from proximal congenitally determined vessel stenosis. A morphologically intact arterial wall is thus altered similarly to arteriosclerotic degeneration. Acquired aneurysms may result secondary to arteriosclerosis and contributing factors such as hypertension, cigarette smoking, and heavy alcohol consumption.<sup>13-16</sup> Predisposing genetic factors or genetic susceptibility, however, have been described to possibly contribute to the pathogenesis of most aortic aneurysms.<sup>14-16</sup> It is interesting to note that in this case, the patient was young, healthy, and without evidence of arteriosclerosis; yet the aneurysm encountered was classified as fusiform. The history of an aortic arch aneurysm in a sibling does support a congenital origin of structural arterial disorder typified by saccular rather than an acquired one characterized by fusiform aneurysms. Malformations of the aortic arch and central arteries have been described to originate from abnormal or incomplete obliteration of embryological vessels.<sup>12</sup>

Intracranial aneurysms may manifest signs and symptoms that include headaches; seizures; epilepsy; depression of consciousness; sixth nerve palsy; retinal, conjunctival, vitreal, and orbital hemor-

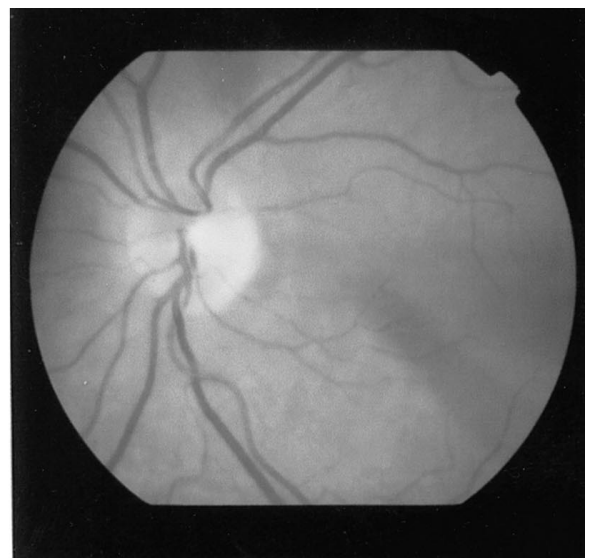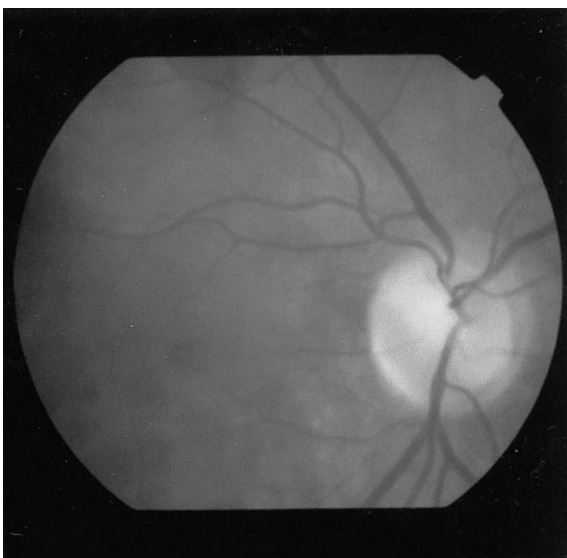**TABLE 1.**  
Signs and symptoms of chiasmal syndrome.

Symptoms	Signs
Vision loss	Optic atrophy
Visual field loss	Papilledema
Headaches (brow or periorbital)	See-saw nystagmus
Diplopia	Oculo-motor paresis
Depth perception loss	Exophthalmos
Cerebrospinal fluid rhinorrhea	Endocrine dysfunction

rhages; focal neurological signs; and chiasmal syndrome—associated signs and symptoms.<sup>3, 17</sup> Diagnosis is based on the presentation of characteristic signs and symptoms accompanying symptomatic intracranial aneurysms and/or utilization of modern neuroimaging procedures (e.g., magnetic resonance imaging and magnetic resonance angiogram).<sup>17</sup> Supraclinoid aneurysms tend to enlarge upwards and medially with resulting compression of the lateral aspect of the chiasm and optic nerve. This scenario may precipitate a lateral chiasmal syndrome. In lateral chiasmal syndrome, signs and symptoms of chiasmal syndrome results from lateral compression at the optic chiasm by a space-occupying lesion. Table 1 lists and summarizes some of the signs and symptoms associated with chiasmal syndrome. Ipsilateral vision loss may present with nasal visual field loss and central scotoma. With increasing size, this insult may further compress the crossing fibers of the contralateral eye, which correspond to the lower retina. Compression of these fibers may result in the loss of the superior temporal visual field. If compression is allowed to continue, the final outcome may be an ipsilateral eye with no light perception and contralateral absolute temporal hemianopsia. Periods of unilateral retro-orbital pain with slowly deteriorating visual fields over many years appears to be the characteristic of these aneurysms.<sup>5</sup> The patient in this case presentation did not report symptoms, although right eye nasal visual field loss was present. The compres-

sion at the chiasm exhibited an additional upward vector manifested by elevation of the optic nerve. The paraclinoid aneurysm thus behaved as a space-occupying lesion causing a lateral chiasmal syndrome. Right eye subtle temporal optic nerve pallor and visual field loss were signs resulting from this insult.

Current management options for unruptured intracranial aneurysms include medical therapy, endovascular coil embolization, surgical clipping, trapping, and proximal ligation.<sup>13, 17, 18</sup> Controversy presently exists on whether observation (with or without medical treatment) or surgical intervention of small unruptured intracranial aneurysm may be more appropriate. This dilemma arises from a combination of factors. Current data estimates the rate of aneurysm rupture in patients with previously unruptured intracranial aneurysms smaller than 1 cm in diameter to be < 0.05% per year. By contrast, the procedure-related complication rate of endovascular coiling has been reported to be 8%, and the morbidity rate after surgical clipping is 10%.<sup>13</sup> Surgical morbidity also has been reported to increase with aneurysm size.<sup>17</sup> Solomon et al.<sup>17</sup> recommended surgery for asymptomatic unruptured intracranial aneurysms >5 mm in size in otherwise healthy individuals <70 years old. They added that surgery might be considered even for small aneurysms with a coexisting history of a subarachnoid hemorrhage from a previous aneurysm, for symptomatic lesions, or those aneurysms manifesting signs such as those secondary to nerve or brainstem compression. In surgical clipping, a clip is placed over the aneurysm neck to isolate the lesion from the circulation.<sup>17, 18</sup> Aneurysms involving the entire vessel circumference and/or lack of a neck area are best treated by trapping. Proximal ligation may be a viable option if the aneurysm has major arterial branches or has emanating critical perforators. In trapping and proximal ligation, it is imperative that the patient's collateral circulation can tolerate occlusion of major vessels.<sup>17</sup> Endovascular coiling embolization involves the deposition of platinum coils through an endovascular microcatheter to cause thrombosis and circulatory isolation of the aneurysm. Although endovascular coiling has been reported to be



**FIGURE 1.**

A: Fundus photography optic nerve OD. Note mild temporal pallor. B: Optic nerve OS with visible scleral crescent, but otherwise healthy rim tissue color. Note slightly tilted nerve OS and hypoplasia relative to the right eye.



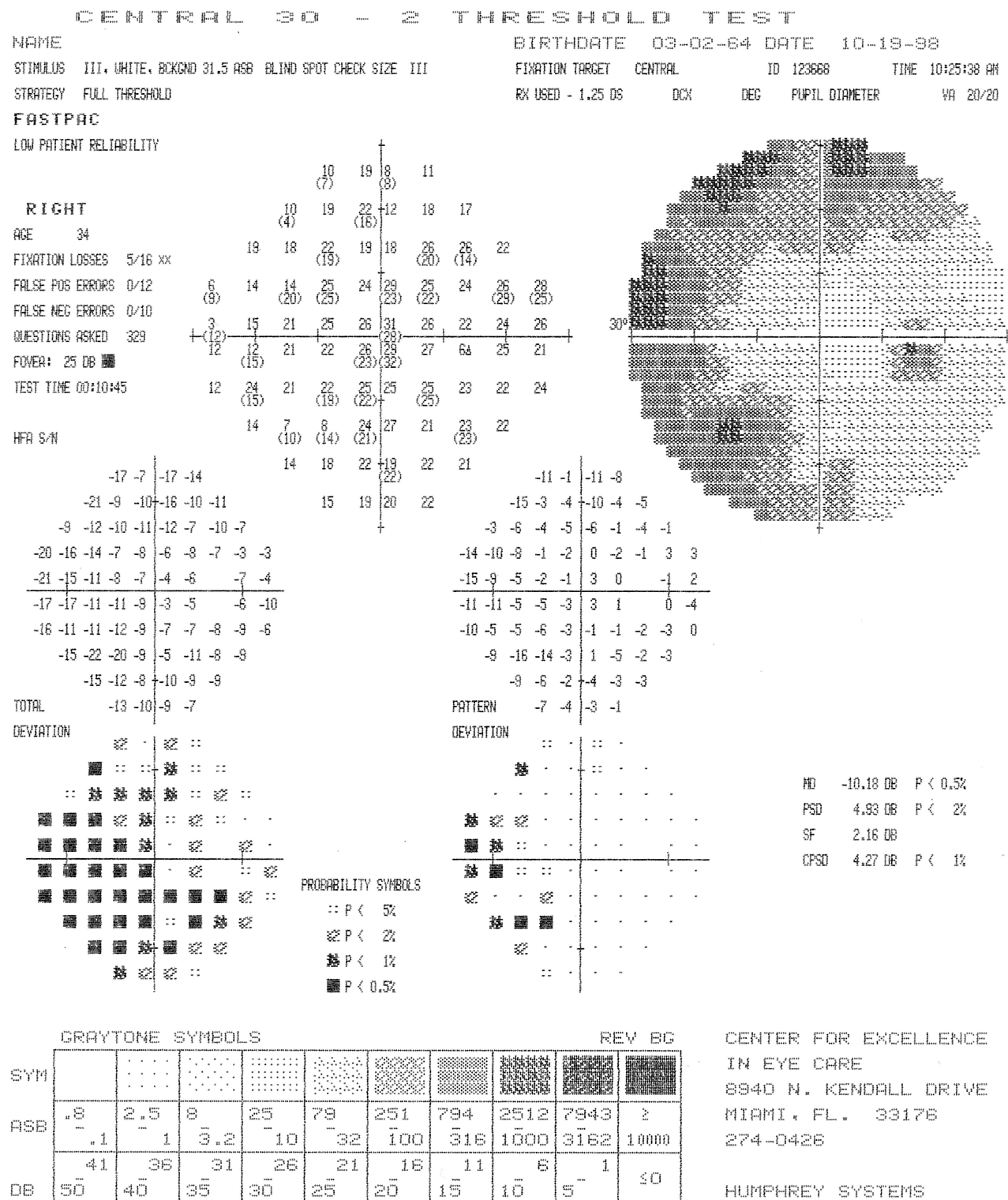


FIGURE 2a.

A: Humphrey 30-2 visual field OD showing moderate nasal depression, moderate generalized constriction, and reduced central reference level. B: Normal visual field OS with mild generalized constriction.

safer than surgical clipping, this technique is best reserved for aneurysms situated at the posterior circulation such as at the basilar tip. Endovascular coiling may also be an alternative mode of intervention for patients of advanced age, patients with surgical contraindications, or patients with a previous unsuccessful intracranial procedure.<sup>17, 18</sup>

The absence of a clinically detectable RAPD is noteworthy in this case. Table 3 summarizes theories that may explain the absence of a RAPD. For the purpose of this manuscript, the term "clinically detectable" is used in reference to the routine clinical testing conditions (swinging flashlight test) that are used to evaluate pupillary responses without adjunct use of neutral-density filters. Chiasmal

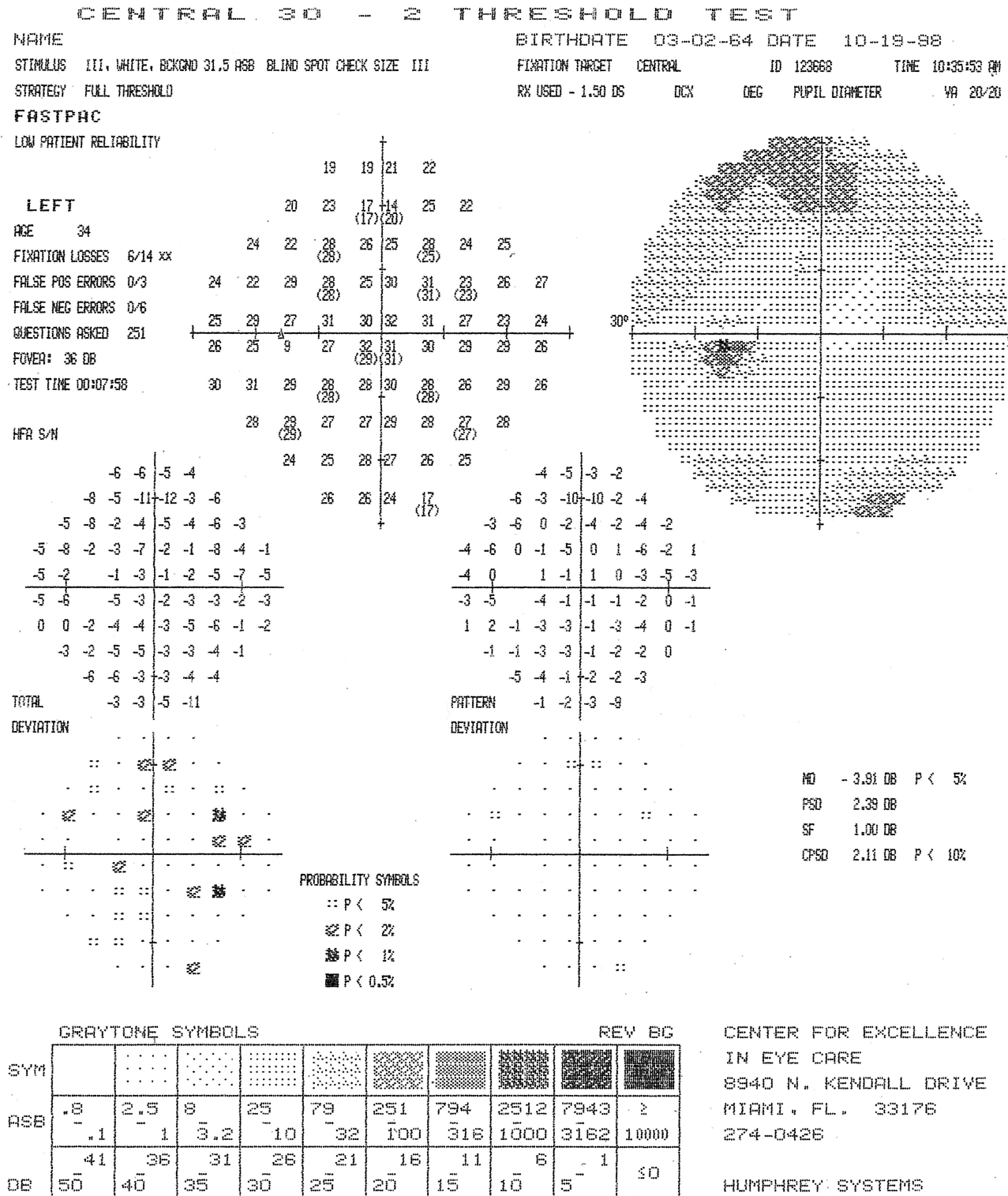
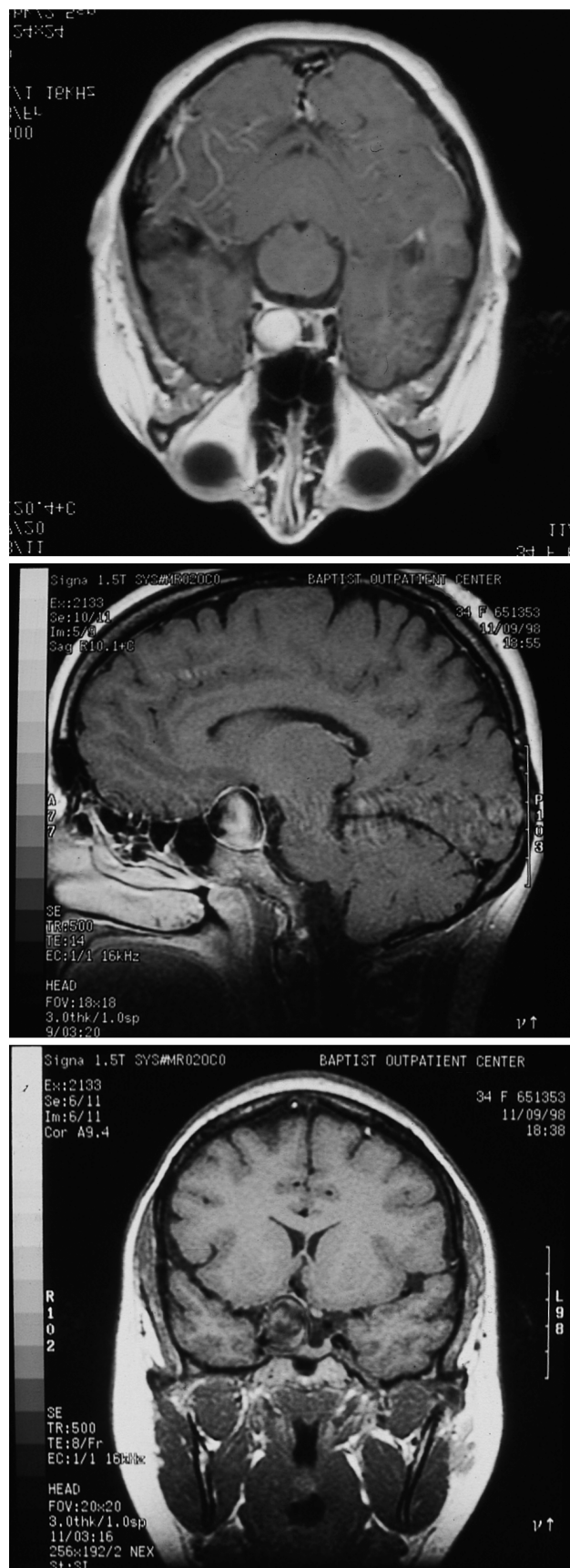

FIGURE 2b.

lesions affecting both optic nerves may not give rise to a RAPD.<sup>19</sup> It can generally be expected, however, that asymmetric optic nerve damage be accompanied by the presence of a RAPD.<sup>6,7,10</sup> Using neutral-density filters, the depth of the RAPD has been quantified.<sup>6</sup> The RAPD depth corresponds to the degree of asymmetric optic nerve loss. The actual asymmetric axonal loss that correlates to a RAPD is unknown. In this case, unilateral temporal optic

nerve pallor and asymmetric visual field loss were consistent with an asymmetric insult to the optic nerve. Nonetheless, a clinically detectable RAPD could not be elicited in the patient. Observational error can not be absolutely discarded, but is a less likely explanation. Three examiners, including a neuro-ophthalmologist, on separate visits followed the appropriate protocol (as described in the methods section) for diagnosing and grading a RAPD.<sup>6</sup> Each



**FIGURE 3.**

Magnetic resonance imaging (transverse, sagittal, and coronal views) series demonstrating the presence of a paraclinoid aneurysm elevating and compressing the right optic nerve and optic chiasm.

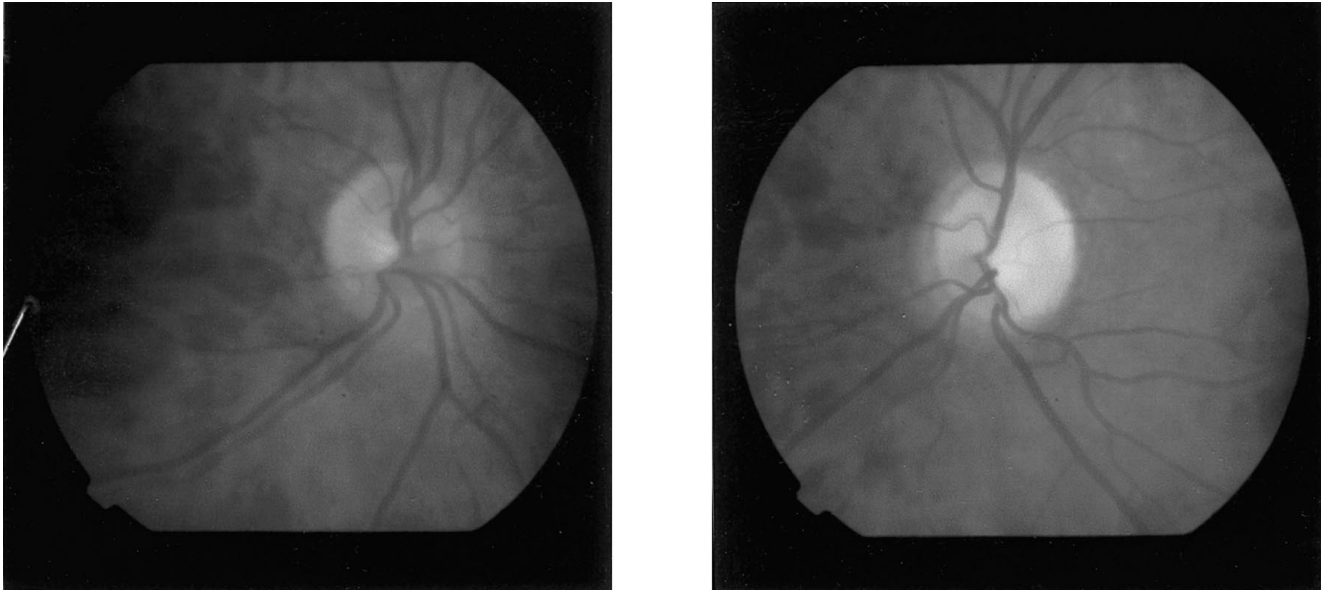
examiner concurred that a clinically detectable RAPD was not present. It may be argued that more sensitive methods such as pupillometry would have detected a RAPD. However, pupillometry would likely have yielded a RAPD of low magnitude that might be practically undetectable in routine clinical testing. Crossed polarized or neutral-density filters may also be used to quantify more subtle relative afferent pupillary defects.<sup>20</sup> However, a RAPD of  $<0.3$  log units has been found in normal subjects and considered benign in individuals with no significant history or clinical manifestations.<sup>21</sup> The VEP result provides limited support to the clinical absence of a RAPD. The degree of RAPD has been reported to correlate with a reduction of VEP amplitude but not with a delay in the VEP latency.<sup>22</sup> The VEP latency, in patients having tumors extending into the suprasellar region and “normal” visual acuity, has also been reported not to be significantly different from that of “normal” subjects.<sup>23</sup> The remaining fact in this case is that although a low magnitude RAPD may have been detected with more sensitive methods such as pupillometry or using neutral-density filters, a clinically detectable RAPD was not apparent, confounding the diagnosis.

Another explanation, which may reconcile the absence of a RAPD in this patient, is that insufficient unilateral (or asymmetric) optic nerve damage was actually present. The presence of unilateral optic nerve pallor may lead the clinician to expect a RAPD. At the anterior portion of the optic nerve, macular fibers have been documented to occupy the temporal sector.<sup>24, 25</sup> This area represents at least one-third of the cross-sectional area of the optic nerve.<sup>24</sup> Therefore, the observation of temporal optic nerve pallor in the right eye also inclines the examiner to expect a RAPD. However, the precise degree of asymmetric optic nerve pallor or axonal loss necessary to produce a RAPD is not known. Levin et al.<sup>8</sup> quantified and correlated optic nerve damage with abnormalities in optic disc color and pupillary response in three patients with intracranial mass lesions. They found that one of the optic nerves studied appeared clinically normal although it had lost 30% of the normal number of axons, whereas temporal pallor was present in optic nerves with 68% and 70% axonal loss. In one of the studied nerves, a 30% loss of axons was associated with relatively normal visual acuity. Based on optic nerve observations from two patients that had a RAPD, they estimated that a twofold to threefold difference in the amount of fibers between the two eyes might be sufficient to manifest a RAPD. Because subtle atrophy and 20/20 visual acuity were present in this patient, axonal loss may have been less than a twofold difference between the two eyes. It is possible that the right eye optic atrophy represented a significant loss of axons in relation to the opposite eye to manifest a difference in appearance, yet not profound enough to promote a RAPD.

Relative optic nerve hypoplasia, which was observed in the subject, may also help explain the absence of a RAPD. A RAPD may be present in the more hypoplastic optic nerve in patients with relative optic nerve hypoplasia.<sup>26</sup> Because the right eye optic nerve was the largest but had mild temporal optic atrophy, a relative conduction deficit may not have been significantly present to manifest a clinically detectable RAPD.

The visual field analysis does not necessarily contradict the apparent absence of a RAPD. Visual field loss correlates with the depth of the RAPD. The asymmetry of visual field loss correlates with the magnitude of the RAPD.<sup>9, 10, 27</sup> The presence of a RAPD





**FIGURE 4.**

A: Fundus photography optic nerve OD (postsurgical). Note moderate temporal pallor appearance OD. B: Optic nerve OS with unchanged appearance compared with initial visit (underexposed) views).

indicates that a threshold level of asymmetric optic nerve damage is evident and quantifiable with automated perimetry. Brown et al.<sup>7</sup> documented a RAPD in glaucoma patients with a visual field sensitivity difference of 13% or greater between the two eyes. Brown and White<sup>28</sup> reported a case of chiasmal syndrome secondary to an ophthalmic artery aneurysm. Their patient manifested sudden, progressive decreased visual acuity (OD 20/40 and OS 20/100), asymmetric visual field loss (few scattered inferior defects OD and left temporal hemianopsia OS), intact optic nerves, and mild RAPD OS. The calculated percentage visual field loss difference (based on percentage missing points from full-field 120-point screening visual field) was 18.4%. The case described here revealed right eye nasal depression. Although fixation losses were present, the visual field loss corresponded with the right eye temporal optic atrophy and compression of the paraclyoid aneurysm at the chiasm. Equations similar to Brown and associates were used to determine percentage sensitivity difference between the visual fields (OD and OS). The total sensitivity for each visual field was derived by adding the decibel values at all tested points. A percent sensitivity score was obtained by dividing the total visual field sensitivity of each eye by that of the age-matched visual field. To quantify visual field asymmetry, the lower score was subtracted from the higher score. In this case, a difference of about 20% (19.95%) was calculated. A visual field asymmetry was apparent, and the sensitivity difference was above the lower limit reported by Brown et al. to be associated with the presence of a RAPD. The interocular mean deviation difference has been documented to significantly predict the presence of a RAPD.<sup>29</sup> The mean deviation difference in the presurgical visual fields was 6.26 dB. Lagreze and Kardon<sup>30</sup> found a significant correlation between a RAPD and the mean deviation in the affected eye with unilateral optic nerve diseases. Extrapolating the mean deviation difference in this case to their data, a RAPD close to 0.5 log units (approximately corresponding to a grade I RAPD) should have been present. Although, according

to the above studies, a RAPD should have been expected in this case, it does not absolutely indicate that it will be present. Absence of a RAPD has been reported in cases with severe monocular temporal visual field loss secondary to lesions of the pregeniculate visual pathway.<sup>10</sup> It is also possible that for chiasmal lesions of the type represented by this case, a higher threshold difference may be required to elicit a RAPD. The insult location at the chiasm may also affect the eventual manifestation of a RAPD.

An additional explanation for the absence of a RAPD may be related to the anatomy of the afferent visual system. In humans, 47% of retinal ganglion cell axons remain uncrossed, whereas 53% cross at the optic chiasm.<sup>10</sup> In addition, the afferent axons that conduct pupillary information travel by a separate pathway from those conveying visual signals preceding the lateral geniculate nucleus and continue their route through the brachium of the superior colliculus to reach the pretectal region (Fig. 6). A contralateral RAPD may result from unilateral lesions in this area without accompanying visual acuity, color vision, or visual field loss in the eye of the affected side.<sup>32–35</sup> Anterior to the chiasm, it is thought that pupillary and visual fibers travel through the same pathway. Evidence supporting this concept is based on observation of the association of visual field loss with pupillary abnormalities and coexisting presence of a RAPD with lesions affecting the central vision.<sup>10, 36</sup> However, there are several circumstances that provide evidence to contradict this theory. There are documented cases of patients manifesting a RAPD with optic neuritis who recovered central visual acuity to 20/20 but retained abnormal contrast sensitivity functions.<sup>10, 37–39</sup> It has also been theorized that in optic neuritis, the P retinal ganglion cells may be selectively damaged.<sup>40</sup> Some reports have documented a RAPD in patients without visual field defects, whereas others have described absence of a RAPD in certain lesions involving the central vision (e.g., macular disease).<sup>10, 41</sup> Observation of monocular temporal visual field

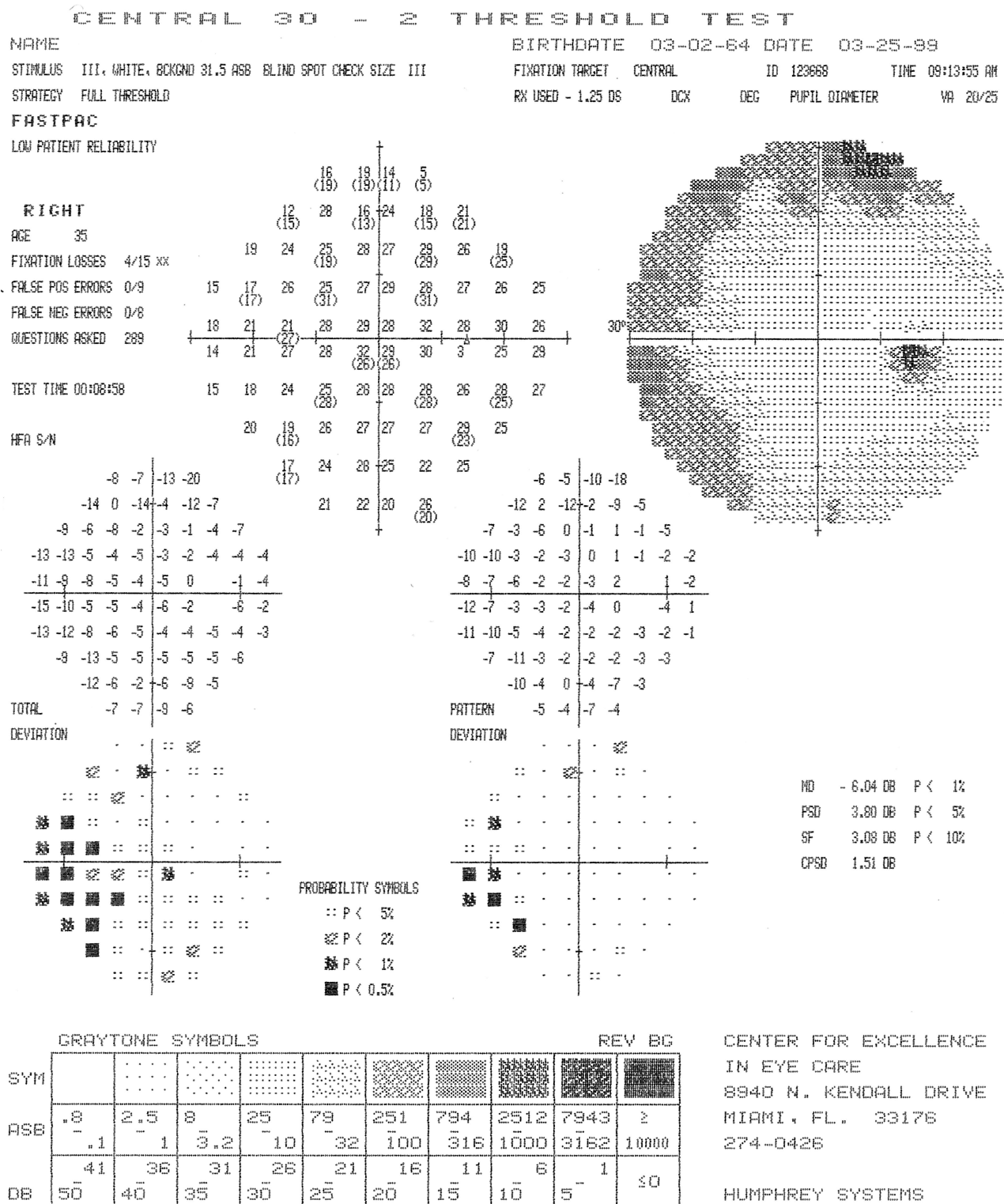


FIGURE 5a.

A: Postsurgical visual field showing nasal depression OD and mild generalized constriction. B: Postsurgical normal visual field OS.

loss without RAPD in five patients lead Kosmorsky et al.<sup>10</sup> to suggest that the visual and pupillary pathway may be functionally separate or even anatomically variable anterior to the chiasm and posterior to the optic nerve head. The diagnosis of these cases included posterior ischemic optic neuropathy (left eye), craniopharyngioma, pituitary adenoma, right eye post-

papilledema optic atrophy, and traumatic optic neuropathy (right eye). Although mostly speculative, this theory of separate pathways between the visual and pupillary fibers commencing at the posterior optic nerve may provide an additional rationale to this case presentation.

Another interesting hypothesis can be derived and extrapolated



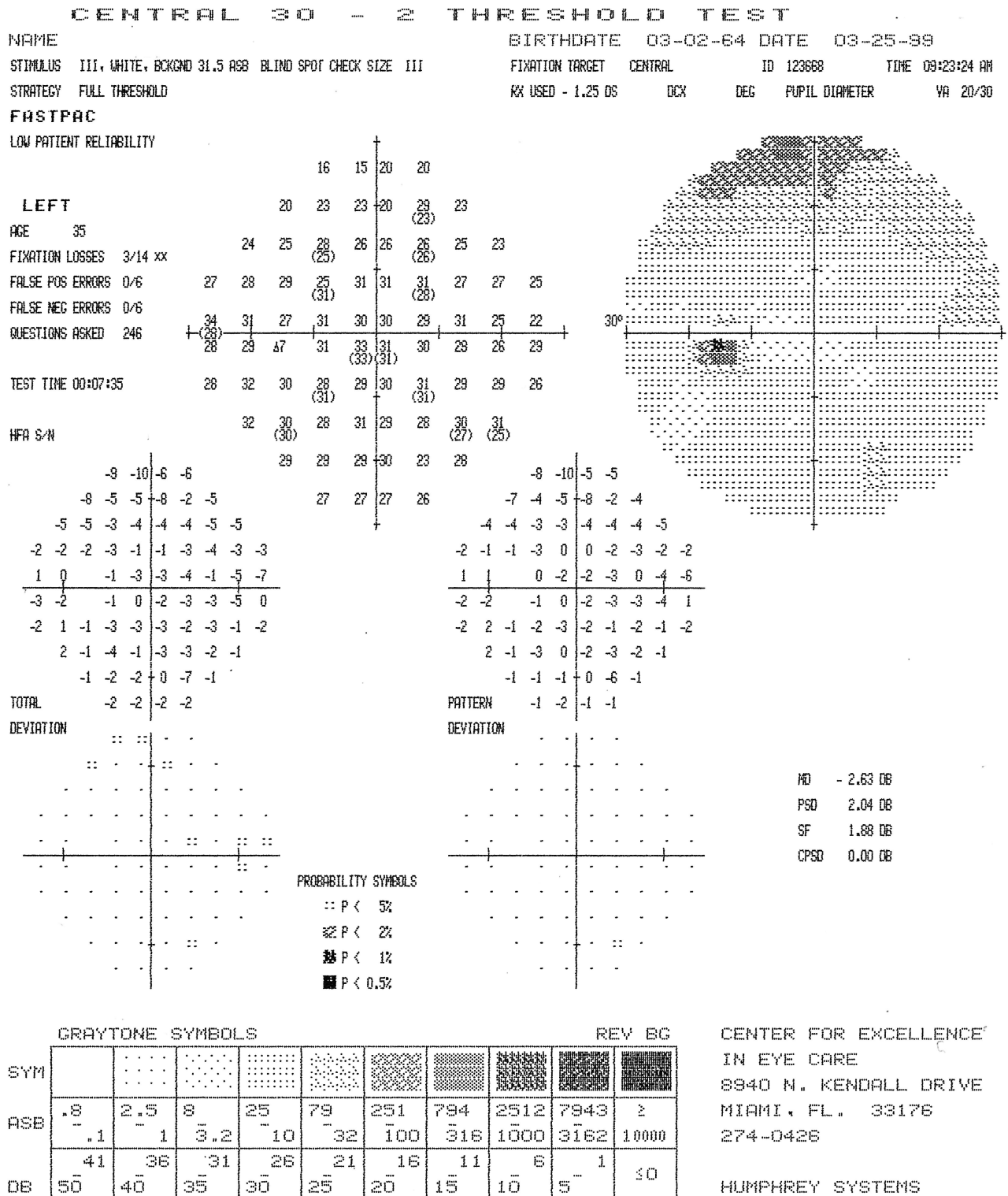


FIGURE 5b.

from histologic data obtained from the macaque monkey.<sup>30</sup> The pupillomotor ganglion cell dendritic field diameters are larger than those projecting to the lateral geniculate nucleus. Pupillomotor ganglion cells outside a retinal area with damaged ganglion cells might still be stimulated by bipolar cells at the affected site due to the longer dendrites of the pupillomotor ganglion cells. Thus, theoretically, visual field loss and/or optic nerve atrophy may be present without an accompanying RAPD.

## CONCLUSION

This case demonstrates the importance of following a protocol of visual field assessment and neuroimaging analysis in newly diagnosed cases of presumed optic atrophy. In asymmetric or unilateral optic atrophy, a clinically detectable RAPD may not be apparent. An absent or nonapparent clinically detectable RAPD may confound the decision to obtain these additional tests yet does not

**TABLE 2.**

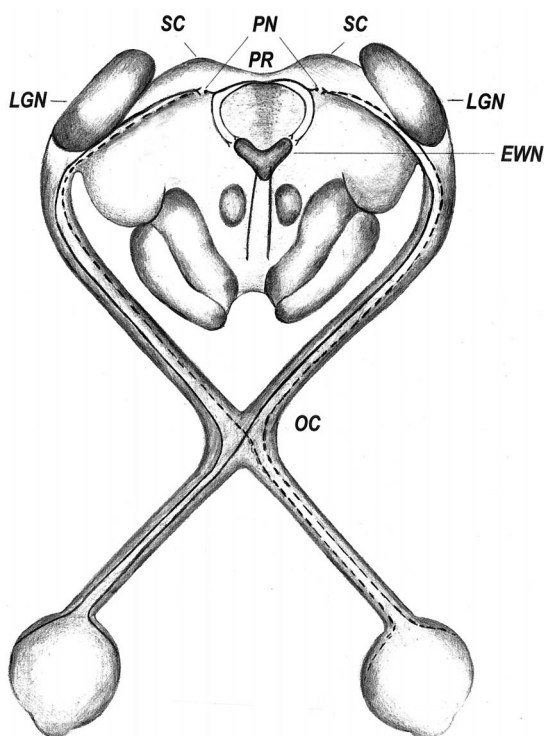
Classification of congenital aneurysms.

Primary arterial aneurysms
Congenital connective tissue abnormalities
Marfan's syndrome
Ehlers-Danlos syndrome
Marfanoid hypermobility syndrome
Pseudoxanthoma elasticum
Fibrodysplasia
Secondary arterial aneurysms
Cervical rib syndrome
Renal artery stenosis (e.g. renal artery fibrodysplasia and neurofibromatosis)
Aberrant subclavian artery

**TABLE 3.**

Hypothesis for the absence of a RAPD.

Examiner error
Insufficient asymmetric optic nerve damage
Relative hypoplasia of the contralateral "unaffected" eye
Separation of pupillary and visual axons posterior to the optic nerve
Larger pupillomotor vs. visual axon dendritic field diameter in the primate retina

**FIGURE 6.**

Afferent pupillary pathway. In humans 47% of axons remain uncrossed. Afferent pupillary axons provide information to the pretectal nuclei (pn) separately from those conveying visual signals prior to the lateral geniculate nucleus (lgn) and continue traveling through the brachium of the superior colliculus (sc) to reach the pretectal region (pr). A separation of pupillary and visual signals may occur anterior to the chiasm and posterior to the optic nerve head. EWN, Edinger Westphal nucleus. Adapted from Thompson<sup>31</sup>.

preclude its imperative need. Preexisting unilateral optic nerve anomalies may mask the manifestation of a clinically detectable RAPD in the contralateral affected eye. Separate pupillary and visual pathways at the level of the posterior optic nerve may also explain discrepancies between abnormal visual functions and clinically absent RAPD in some optic nerve disease cases.

## ACKNOWLEDGMENT

We thank Noemi Rais for contributing Fig. 6.

Received May 25, 2000; revision received January 15, 2001.

## REFERENCES

1. Trevino R. Chiasmal syndrome. *J Am Optom Assoc* 1995;66:559-75.
2. Glaser JS. Topical diagnosis: the optic chiasm. In: Tasman W, Jaeger EA, eds. *Duane's Clinical Ophthalmology*, Vol. 2. Philadelphia: JB Lippincott, 1993:1-39.
3. Troost TB, Glaser JS. Aneurysms, arteriovenous communication, and related vascular malformations. In: Tasman W, Jaeger EA, eds. *Duane's Clinical Ophthalmology*, Vol. 2. Philadelphia: JB Lippincott, 1993:1-34.
4. van Dalen JT, Verbeeten BJ, Peeters FL. Chiasmal syndrome: ophthalmological and neuro-radiological aspects. *Doc Ophthalmol* 1982;52:259-78.
5. Peiris JB, Ross Russell RW. Giant aneurysms of the carotid system presenting as visual field defect. *J Neurol Neurosurg Psychiatry* 1980;43:1053-64.
6. Bell RA, Waggoner PM, Boyd WM, Akers RE, Yee CE. Clinical grading of relative afferent pupillary defects. *Arch Ophthalmol* 1993;111:938-42.
7. Brown RH, Zilis JD, Lynch MG, Sanborn GE. The afferent pupillary defect in asymmetric glaucoma. *Arch Ophthalmol* 1987;105:1540-3.
8. Levin PS, Newman SA, Quigley HA, Miller NR. A clinicopathologic study of optic neuropathies associated with intracranial mass lesions with quantification of remaining axons. *Am J Ophthalmol* 1983;95:295-306.
9. Thompson HS, Montague P, Cox TA, Corbett JJ. The relationship between visual acuity, pupillary defect, and visual field loss. *Am J Ophthalmol* 1982;93:681-8.
10. Kosmorsky GS, Tomsak RL, Diskin DK. Absence of the relative afferent pupillary defect with monocular temporal visual field loss. *J Clin Neuroophthalmol* 1992;12:181-91.
11. Trobe JD, Tao AH, Schuster JJ. Perichiasmal tumors: diagnostic and prognostic features. *Neurosurgery* 1984;15:391-9.
12. Bartels C, Horsch S. Classification of congenital arterial and venous vascular malformations. *Angiology* 1995;46:191-200.
13. Broderick JP. Coiling, clipping, or medical management of unruptured intracranial aneurysms: time to randomize? *Ann Neurol* 2000;48:5-6.
14. Muluk SC, Gertler JP, Brewster DC, Cambria RP, LaMuraglia GM, Moncure AC, Darling RC, Abbott WM. Presentation and patterns of aortic aneurysms in young patients. *J Vasc Surg* 1994;20:880-6.
15. Reilly JM, Tilson MD. Incidence and etiology of abdominal aortic aneurysms. *Surg Clin North Am* 1989;69:705-11.
16. Dobrin PB. Pathophysiology and pathogenesis of aortic aneurysms: current concepts. *Surg Clin North Am* 1989;69:687-703.
17. Solomon RA, Fink ME, Pile-Spellman J. Surgical management of unruptured intracranial aneurysms. *J Neurosurg* 1994;80:440-6.
18. Johnston SC, Wilson CB, Halbach VV, Higashida RT, Dowd CF,

- McDermott MW, Applebury CB, Farley TL, Gress DR. Endovascular and surgical treatment of unruptured cerebral aneurysms: comparison of risks. *Ann Neurol* 2000;48:11–9.
19. Donin JF. The chiasm: a medicolegal locus minoris resistentiae. *Surv Ophthalmol* 1982;26:334–6.
  20. Rosenberg ML, Oliva A. The use of crossed polarized filters in the measurement of the relative afferent pupillary defect. *Am J Ophthalmol* 1990;110:62–5.
  21. Kawasaki A, Moore P, Kardon RH. Long-term fluctuation of relative afferent pupillary defect in subjects with normal visual function. *Am J Ophthalmol* 1996;122:875–82.
  22. Nagashima Y, Kato M, Watanabe I. Visual evoked potential and relative afferent pupillary defect in patients with unilateral optic neuritis. *Nippon Ganka Gakkai Zasshi* 1991;95:1004–8.
  23. Gutowski NJ, Heron JR, Scase MO. Early impairment of foveal magno- and parvocellular pathways in juxta chiasmal tumours. *Vision Res* 1997;37:1401–8.
  24. Hoyt WF, Luis O. Visual fiber anatomy in the infrageniculate pathway of the primate. *Arch Ophthalmol* 1962;68:124–36.
  25. Potts AM, Hodges D, Shelman CB, Fritz KJ, Levy NS, Mangnall Y. Morphology of the primate optic nerve: 3. Fiber characteristics of the foveal outflow. *Invest Ophthalmol* 1972;11:1004–16.
  26. Sing NM, Anderson SF, Townsend JC. The normal optic nerve head. *Optom Vis Sci* 2000;77:293–301.
  27. Kardon RH, Hauptert CL, Thompson HS. The relationship between static perimetry and the relative afferent pupillary defect. *Am J Ophthalmol* 1993;115:351–6.
  28. Brown MD, White K. Chiasmal syndrome secondary to ophthalmic artery aneurysm. *Southern J Optom* 1996;14:23–5.
  29. Bobak SP, Goodwin JA, Guevara RA, Arya A, Grover S. Predictors of visual acuity and the relative afferent pupillary defect in optic neuropathy. *Doc Ophthalmol* 1998;97:81–95.
  30. Lagreze WD, Kardon RH. Correlation of relative afferent pupillary defect and estimated retinal ganglion cell loss. *Graefes Arch Clin Exp Ophthalmol* 1998;236:401–4.
  31. Thompson HS. The pupil. In: Moses RA, ed. *Adler's Physiology of the Eye Clinical Application*. St Louis: CV Mosby, 1981:326–56.
  32. Girkin CA, Perry JD, Miller NR. A relative afferent pupillary defect without any visual sensory deficit. *Arch Ophthalmol* 1998;116:1544–5.
  33. Forman S, Behrens MM, Odel JG, Spector RT, Hilal S. Relative afferent pupillary defect with normal visual function. *Arch Ophthalmol* 1990;108:1074–5.
  34. Johnson RE, Bell RA. Relative afferent pupillary defect in a lesion of the pretectal afferent pupillary pathway. *Can J Ophthalmol* 1987;22:282–4.
  35. King JT Jr, Galetta SL, Flamm ES. Relative afferent pupillary defect with normal vision in a glial brainstem tumor. *Neurology* 1991;41:945–6.
  36. Firth AY. Pupillary responses in amblyopia. *Br J Ophthalmol* 1990;74:676–80.
  37. Ellis CJ. The afferent pupillary defect in acute optic neuritis. *J Neurol Neurosurg Psychiatry* 1979;42:1008–17.
  38. Cox TA, Thompson HS, Corbett JJ. Relative afferent pupillary defects in optic neuritis. *Am J Ophthalmol* 1981;92:685–90.
  39. Kupersmith MJ, Nelson JJ, Seiple WH, Carr RE, Weiss PA. The 20/20 eye in multiple sclerosis. *Neurology* 1983;33:1015–20.
  40. Wall M. Loss of P retinal ganglion cell function in resolved optic neuritis. *Neurology* 1990;40:649–53.
  41. Johnson LN, Hill RA, Bartholomew MJ. Correlation of afferent pupillary defect with visual field loss on automated perimetry. *Ophthalmology* 1988;95:1649–55.

**Eulogio Besada**

*Nova Southeastern University College of Optometry  
1750 NE 167th Street  
North Miami Beach, Florida 33162  
e-mail: ebesada@hpd.acast.nova.edu*