

◆ CASE REPORT ————— ◆

## Transient Contrast Encephalopathy After Carotid Artery Stenting

George Dangas, MD, PhD<sup>1</sup>; Lee H. Monsein, MD<sup>2</sup>;  
Robert Laurenno, MD<sup>3</sup>; Michael A. Peterson, MD<sup>4</sup>;  
John R. Laird, Jr., MD<sup>4</sup>; Lowell F. Satler, MD<sup>4</sup>;  
Roxana Mehran, MD<sup>1,4</sup>; and Martin B. Leon, MD<sup>1,4</sup>

<sup>1</sup>Cardiovascular Research Foundation, Lenox Hill Heart & Vascular Institute, New York, New York; and Departments of <sup>2</sup>Neuroradiology and <sup>3</sup>Neurology, and <sup>4</sup>Division of Cardiology, Washington Hospital Center, Washington, DC, USA

◆ ————— ◆  
**Purpose:** To report an unusual case of transient contrast encephalopathy arising after carotid artery stenting.

**Case Report:** An 82-year-old right-handed man with a recent history of transient ischemic events was admitted to the hospital for evaluation of carotid artery disease. During cerebral angiography, which identified a 90% right internal carotid artery stenosis, the patient received 25 mL of an ionic, low-osmolar contrast agent (ioxaglate) in each carotid artery. The following day he underwent successful carotid stenting, during which 180 mL of ioxaglate were used. He developed rapidly worsening confusion and left hemiparesis on the table. Noncontrast computed tomography showed marked cortical enhancement and edema of the right cerebral hemisphere in the distribution of the right anterior and middle cerebral arteries. The patient improved rapidly and by day 2 was completely recovered; magnetic resonance imaging documented no cortical edema and normal sulci. One month after the procedure, he was well, with patent carotid arteries.

**Conclusions:** Transient neurotoxicity after carotid interventions must be differentiated from massive cerebral infarction and hyperperfusion syndrome, but the prognosis is excellent. However, subsequent contrast studies in a patient with this complication should be undertaken with extreme caution.

*J Endovasc Ther 2001;8:111-113*

**Key words:** neurotoxicity, ioxaglate, hemiparesis, cortical edema, blood-brain barrier

◆ ————— ◆  
Neurotoxicity from contrast agents is a rare but well-known complication of diagnostic and therapeutic procedures that employ these agents.<sup>1-4</sup> Typically, this distinctive syndrome presents clinically and radiographically with

visual disturbances,<sup>1-3</sup> but other cerebral manifestations may occasionally arise.<sup>4</sup> We describe an unusual case of transient contrast encephalopathy following carotid artery stenting and discuss the clinical features that distinguish this syndrome.

Address for correspondence and reprints: Dr. George Dangas, Cardiovascular Research Foundation, Lenox Hill Heart & Vascular Institute, 55 East 59th Street, 6th Floor, New York, NY 10022 USA. Fax: 1-212-434-6346; E-mail: [gdangas@crf.org](mailto:gdangas@crf.org)

### CASE REPORT

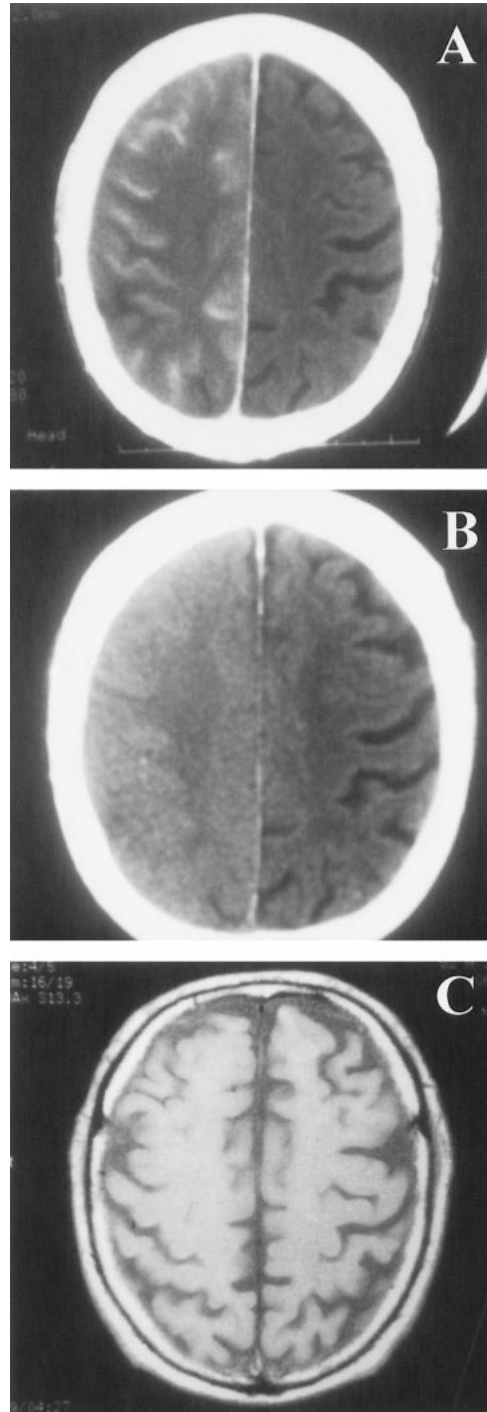
An 82-year-old right-handed man was admitted to the hospital for evaluation of carotid

artery disease. He had experienced amaurosis fugax in the right eye 2 months earlier and, 5 days before evaluation, a 2-hour episode of numbness and weakness of the left arm. His medical history included hypertension, hyperlipidemia, and coronary heart disease. On admission, his neurological examination was normal. Angiography revealed a 90% right internal carotid artery (ICA) stenosis. The patient received 25 mL of an ionic, low-osmolar contrast agent (ioxaglate, Mallinckrodt Medical, St. Louis, MO, USA) during right carotid angiography and 25 mL ioxaglate during left carotid angiography.

The following day, he underwent stenting of the right ICA stenosis. A combination of aspirin and ticlopidine and 5000 units of heparin were administered (the activated clotting time during the procedure was 210 seconds). Two self-expanding stents were placed successfully, and intravascular ultrasound verified appropriate stent apposition, symmetrical expansion, and absence of dissection. A total of 180 mL of ioxaglate was injected in the right carotid artery during the interventional procedure.

While still on the table, the patient developed rapidly worsening confusion. Poststenting cerebral angiography showed no changes, compared with the preprocedural study. Neurological examination documented left hemiparesis and neglect of the left side of the body. Computed tomography (CT) of the brain without contrast (Figure, A) performed 4 hours after the procedure showed marked cortical enhancement and edema of the right cerebral hemisphere in the distribution of the right anterior and middle cerebral arteries.

A repeat CT scan without contrast 12 hours (Figure, B) later showed clearing of the contrast enhancement but persistence of the right cerebral cortical swelling, manifested by effacement of the sulci. The patient developed rapid improvement by the following morning; complete neurological recovery was documented 48 hours after the procedure. At that time, noncontrast magnetic resonance imaging (MRI) (Figure, C) of the brain demonstrated absence of cortical edema and normal-appearing sulci; a small (1-cm), old, right posterior parietal cortical infarct was noted. There was no evidence of renal dysfunction



**Figure** ♦ (A) Noncontrast CT scan 4 hours after the patient developed confusion and left hemiparesis immediately following carotid stenting. There is marked cortical enhancement and edema of the right cerebral hemisphere. (B) Twelve hours after the procedure, the contrast enhancement is clearing on the CT scan, but the right cerebral cortical swelling persists. (C) Two days poststenting, a noncontrast MRI scan demonstrated normal sulci and no cortical edema, consistent with the patient's complete recovery.

throughout the patient's course, and he was discharged 5 days after the carotid procedure. At 1-month follow-up, carotid duplex ultrasonography showed both carotid arteries to be widely patent.

## DISCUSSION

This transient major neurological event affected the entire distribution of the right carotid artery. Cerebral infarction was initially suspected because of the setting of carotid catheterization. However, the intense cortical enhancement and edema occurred too early and the clinical and radiological resolution was too rapid and complete for this large cerebral disorder to have been an infarction. The diagnosis of hyperperfusion syndrome was also a possibility, but it would have involved the carotid distribution exclusively rather than both the ipsilateral carotid and posterior circulations.

The radiological findings were compatible with disruption of and leakage through the blood-brain barrier, as indicated by the cerebral contrast enhancement on the CT scan. Alternatively, a shower of microemboli might have caused global ischemia and transient damage to the capillary bed; however, such fast and complete recovery would not be expected in an octogenarian.

Opening of the blood-brain barrier by hyperosmotic substances has been described elsewhere.<sup>5-7</sup> A high dose of contrast, perhaps in combination with an uncharacterized individual vulnerability,<sup>6,7</sup> may result in acute breakdown of the blood-brain barrier, allowing entrance of contrast material into the

brain and the acute development of a dramatic clinical presentation. The higher osmolality of ioxaglate, compared with blood, may in turn produce fluid extravasation and cerebral edema.

Early after selective cerebral angiography, this form of transient neurotoxicity must be differentiated from massive cerebral infarction and hyperperfusion syndrome. Close follow-up of the clinical picture and the neurological imaging studies (CT scan or MRI) will provide adequate guidance. Since the safety of future cerebral angiography in a patient with this reaction has not been studied extensively, extreme caution should be exercised should the need for repeat angiography arise at a later point in the patient's life.

## REFERENCES

1. Kermode AG, Chakera T, Mastaglia FL. Low osmolar and non-ionic x-ray contrast media and cortical blindness. *Clin Exp Neurol*. 1992;29:272-276.
2. Studdard WE, Davis DO, Young SE. Cortical blindness after cerebral angiography. *J Neurosurg*. 1981;54:240-244.
3. Sticherling C, Berkefeld J, Auch-Schwelk W, et al. Transient bilateral cortical blindness after coronary angiography. *Lancet*. 1998;351:570.
4. Sharp S, Stone J, Beach R. Contrast agent neurotoxicity presenting as subarachnoid hemorrhage. *Neurology*. 1999;52:1503-1505.
5. Bradbury MW. *The concept of a blood-brain barrier*. London: John Wiley & Sons Ltd; 1979.
6. Torvik A, Walday P. Neurotoxicity of water-soluble contrast media. *Acta Radiol*. 1995;399(suppl):221-229.
7. Caille JM, Allard M. Neurotoxicity of hydrosoluble iodine contrast media. *Invest Radiol*. 1988;23(suppl 1):5210-5212.