

Late Occurrence of Diffuse Cerebral Swelling After Intracerebral Hemorrhage in a Patient With the HELLP Syndrome

—Case Report—

Kimiaki HASHIGUCHI, Takanori INAMURA, Kazuo IRITA*, Michie ABE*, Eiichiro NODA*, Shigeaki YANAI**, Shosuke TAKAHASHI*, and Masashi FUKUI

Departments of Neurosurgery, *Anesthesiology and Critical Care Medicine, and **Obstetrics and Gynecology, Graduate School of Medical Sciences, Kyushu University, Fukuoka

Abstract

Hemolysis, elevated liver enzymes, and low platelet count (HELLP) syndrome can occur at any time in the course of pregnancy and is associated with many complications including fatal stroke. A 37-year-old female presented with HELLP syndrome causing an intracerebral hematoma, which was treated by evacuation and mild hypothermia. Unexpected diffuse cerebral swelling occurred on the 15th day of the initially favorable postoperative course. Considerable impairment of consciousness persisted despite conservative therapy. Serial computed tomographic findings indicated delayed cerebral vasospasm as the cause of the swelling. Particularly careful management is required even beyond the first 2 weeks for patients with stroke as a complication of HELLP syndrome.

Key words: cerebral swelling, HELLP syndrome, hypothermia, intracerebral hemorrhage

Introduction

Hemolysis, elevated liver enzymes, and low platelet count (HELLP) syndrome is a complication of pregnancy that sometimes occurs in combination with preeclampsia or eclampsia.^{1,21)} HELLP syndrome manifests as various clinical features such as malaise, jaundice, upper abdominal pain, nausea, vomiting, renal failure, disseminated intravascular coagulation (DIC), pulmonary edema, abruptio placentae, and even rupture of the liver.^{2,7,10,14,17,21)} Stroke involving cerebral vasospasm frequently complicates HELLP syndrome and severe eclampsia.^{3,6,8,12,19)} We report a patient with intracerebral hemorrhage associated with HELLP syndrome in whom hematoma evacuation was unexpectedly followed by late diffuse cerebral swelling.

Case Report

A 37-year-old primigravida had an apparently normal course of pregnancy until amniorrhexis oc-

curred on the 5th day of the 37th week. She was admitted to our hospital. The diagnosis was preeclampsia based on the findings of hypertension (160/100 mmHg) and proteinuria without edema. Cesarean section was performed since fetal distress was evident and sonography disclosed placental abruption of approximately 20%. The newborn child was healthy, but the patient's consciousness was impaired (Glasgow Coma Scale [GCS]: eyes [E] 3, verbal [V] 4, motor [M] 6). Computed tomography (CT) revealed intracerebral hemorrhage in the right frontal lobe (Fig. 1). Two hours later the patient lapsed into a coma (GCS: E1, V1, M4), and CT depicted enlargement and intraventricular extension of the hematoma (Fig. 2). CT after administration of contrast medium demonstrated two small enhanced profiles in the hematoma suggestive of abnormal vessels. Laboratory findings included elevated liver enzyme activities in the serum (aspartate aminotransferase 747 U/l, alanine aminotransferase 472 U/l, and lactate dehydrogenase 2987 U/l), a low platelet count (96000/ μ l), and burr cells in the peripheral blood smear. DIC was excluded by normal plasma concentrations of fibrinogen and fibrin degradation products, as well as normal prothrombin time. The

Received September 26, 2000; Accepted December 11, 2000

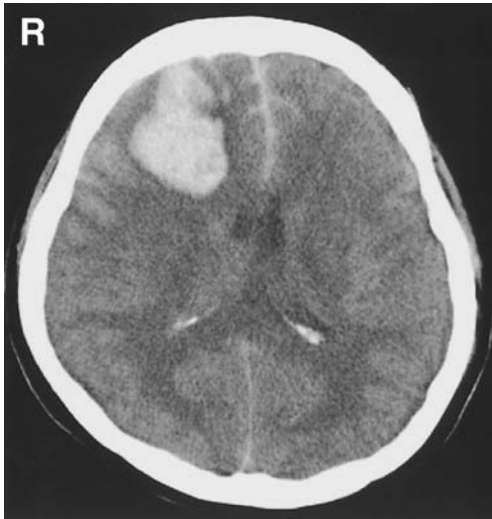

Fig. 1 Computed tomography scan performed immediately after cesarean section showing intracerebral hemorrhage in the right frontal lobe.

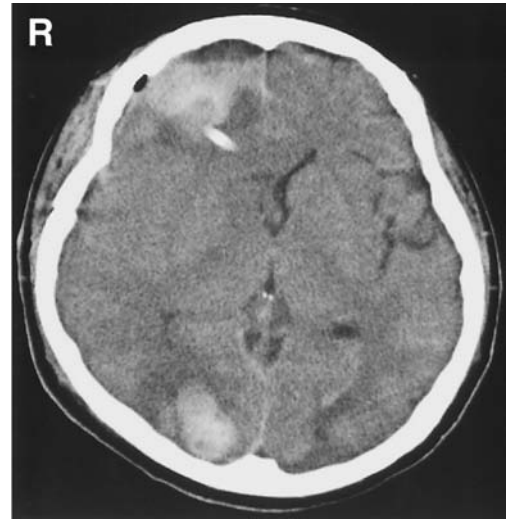


Fig. 3 Computed tomography scan performed 4 days after the start of hypothermia demonstrating cerebral swelling with midline shift, and new intracerebral hemorrhage in the right occipital lobe.

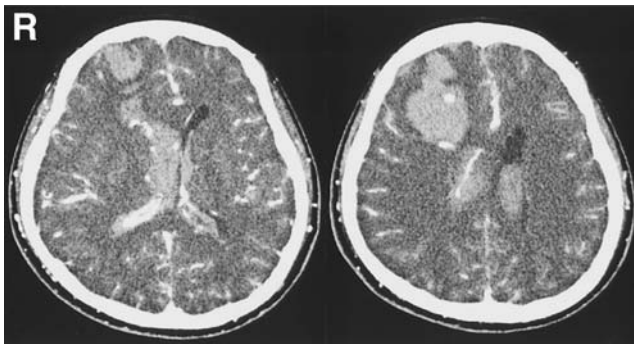


Fig. 2 Computed tomography scans showing the hematoma in the right frontal lobe has enlarged and extended intraventricularly, and two structures were enhanced after administration of contrast medium.

diagnosis was HELLP syndrome.^{2,10)}

Corticosteroid was immediately administered and the hematoma was evacuated with partial frontal lobectomy. The platelet count fell below 50000/ μ l, requiring intraoperative platelet transfusion. Abnormal vessels within the hematoma were identified and resected. Histological examination of these vessels suggested vascular malformation, but no definitive diagnosis could be made. Hemosiderin in the specimen indicated prior occurrence of hemorrhage.

Mild hypothermia (34°C) was induced after surgery because of her impaired consciousness (GCS: E3, V2, M4) and CT evidence of cerebral edema as-

sociated with increased intracranial pressure (over 200 mmH₂O). The increased liver enzyme activities and low platelet count gradually resolved over 7 days, although further platelet transfusion was required. Mild hypothermia was maintained for 5 days and body temperature was gradually increased to 37°C over 4 days. CT performed 4 days after the start of hypothermia revealed small intracerebral hemorrhage in the right occipital lobe (Fig. 3), but the patient's consciousness cleared almost completely (GCS: E4, V4, M6) 12 days after the start of hypothermia, and no focal neurological deficits were present.

On the 15th day after the initial hemorrhage, the patient's blood pressure suddenly rose to 220/110 mmHg and a convulsive seizure followed. She entered a deep coma and developed dilated pupils. Spontaneous respiration was preserved. CT showed diffuse cerebral swelling (Fig. 4 upper row). Laboratory examinations were unremarkable except for increased number of platelets (over 800000/ μ l). Conservative therapy with corticosteroid and infusion of hyperosmotic fluid resolved the diffuse cerebral swelling by the next day (Fig. 4 lower row), but the impairment of consciousness was permanent (GCS: E4, V3, M5).

Discussion

HELLP syndrome can occur, sometimes fatally, at any time during pregnancy or even in the postpartum period. Stroke is the most common

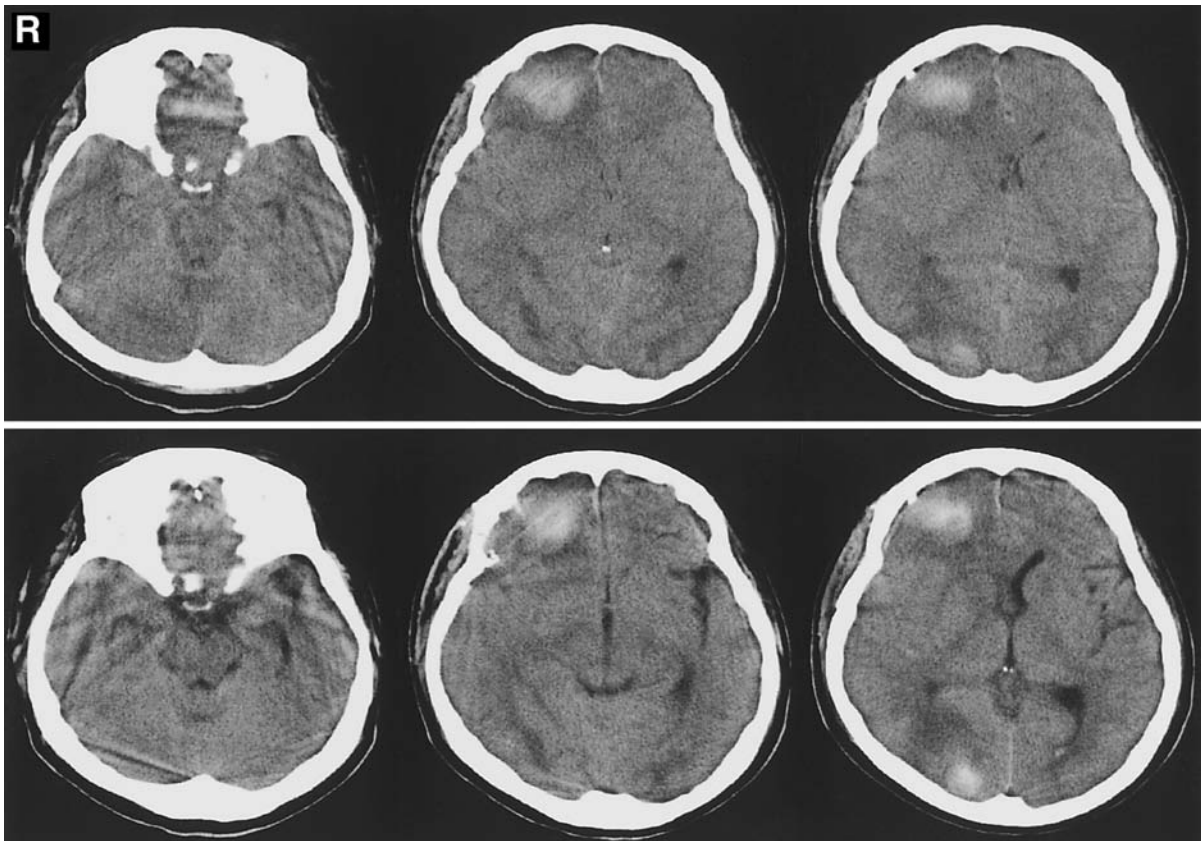


Fig. 4 Computed tomography scans performed immediately following the convulsive seizure that occurred 15 days after the first hemorrhage revealing massive cerebral swelling (upper row) that was no longer apparent the next day (lower row).

cause of death in patients with the HELLP syndrome.^{3,5-7,10,14,17,21} The mechanisms underlying the HELLP syndrome are poorly understood, but arterial spasms induced by abnormal release of vasoactive agents are thought to be involved.^{4,17} However, nontraumatic intracerebral hemorrhage in a young patient is usually associated with vascular anomalies such as arteriovenous malformation or venous malformation, or with neoplasm or embolism.

Multiple factors were thought to be involved in the present case. The major cause of the intracerebral hemorrhage was probably the group of abnormal vessels in the right frontal lobe clearly demonstrated by CT. Furthermore, the hypertension associated with preeclampsia and the bleeding tendency associated with the HELLP syndrome both promoted rupture of these abnormal vessels and resulted in enlargement of the intracerebral hematoma. Hypertension was not medically controllable, and further intracerebral hemorrhage occurred in the right occipital lobe during the hypothermia treatment after

operation.

Termination of pregnancy, usually by cesarean delivery, results in gradual resolution of the symptoms in most patients with HELLP syndrome.^{2,7,17} Some patients with HELLP syndrome associated with DIC require multiple transfusions,^{2,17} and corticosteroid therapy is recommended to reverse thrombocytopenia resulting from the HELLP syndrome.^{11,18,20,25} Our patient received corticosteroid for treating the acute cerebral edema, elevated liver enzyme levels, and thrombocytopenia, all of which resolved 7 days after the cesarean section. Hypothermia was induced to treat the increase in intracranial pressure to over 200 mmH₂O after the evacuation of the intracerebral hematoma.¹⁶ Hypothermia sometimes inhibits the activities of enzymes concerned with platelet aggregation and coagulation, and therefore can cause hemorrhage in patients with tendency to bleeding.^{9,22,23} The intracerebral hemorrhage appearing in the occipital lobe during the hypothermia may have resulted from such inhibition.

Our patient suffered a sudden and unexpected rise in blood pressure followed by convulsive seizure and coma 15 days after the first hemorrhage. Diffuse cerebral swelling was apparent on CT but resolved within 1 day. We suspect that cerebral vasospasm had occurred, but no angiographical evidence was obtained. HELLP syndrome and preeclampsia are frequently associated with cerebral vasospasm, and the severe subarachnoid hemorrhage occurring with the intracerebral hemorrhage at onset could also have induced diffuse cerebral vasospasm.^{6,8,12,15,19,24)} Alternatively, cerebral venous or venous sinus thrombosis or embolism could have occurred because platelet count exceeded 800000/ μ l following her recovery from HELLP syndrome. Deep venous thrombosis has complicated another case of resolving HELLP syndrome.¹³⁾ In our patient, CT with contrast medium performed on the day following diffuse brain swelling did not demonstrate diagnostic findings of venous or sinus embolism such as "delta sign" or abnormally dense cortical veins. Since marked blood pressure elevation occurred 1 hour prior to the convulsive seizure and the subsequent CT showing brain swelling, we suspect that a rapid vasomotor event such as cerebral vasospasm was the cause of the seizure and swelling, although occurrence of transient hypertensive encephalopathy is another possible cause. Symptomatic cerebral vasospasm may occur at up to 11 days after the onset of HELLP syndrome and preeclampsia.^{6,8,19,24)} Hypothermia, which systemically suppresses metabolism, may have delayed the onset of vasomotor dysfunction in our patient.

Thrombocytopenia and cerebral vasospasm contribute to the high incidence of stroke associated with HELLP syndrome. Our case indicates that HELLP syndrome requires particularly careful patient monitoring and management even in the late phase.

Acknowledgment

We thank Ms. Yoshie Hirosawa and Ms. Takako Shiga for their valuable assistance in preparing this manuscript.

References

- 1) Abramovici D, Friedman SA, Mercer BM, Audibert F, Kao L, Sibai BM: Neonatal outcome in severe preeclampsia at 24 to 36 weeks' gestation: does the HELLP (hemolysis, elevated liver enzymes, and low platelet count) syndrome matter? *Am J Obstet Gynecol* 180: 221-225, 1999
- 2) Audibert F, Friedman SA, Frangieh AY, Sibai BM:

- Clinical utility of strict diagnostic criteria for the HELLP (hemolysis, elevated liver enzymes, and low platelets) syndrome. *Am J Obstet Gynecol* 175: 460-464, 1996
- 3) Crosby ET, Preston R: Obstetrical anaesthesia for a parturient with preeclampsia, HELLP syndrome and acute cortical blindness. *Can J Anaesth* 45: 452-459, 1998
- 4) de Belder A, Lees C, Martin J, Moncada S, Campbell S: Treatment of HELLP syndrome with nitric oxide donor. *Lancet* 345: 124-125, 1995
- 5) Dotsch J, Hohmann M, Kuhl PG: Neonatal morbidity and mortality associated with maternal haemolysis elevated liver enzymes and low platelets syndrome. *Eur J Pediatr* 156: 389-391, 1997
- 6) Gliemroth J, Knopp U, Kehler U, Felberbaum R, Nowak G: HELLP syndrome with haemoglobin vasospasm. *J Clin Neurosci* 7: 59-62, 2000
- 7) Isler CM, Rinehart BK, Terrone DA, Martin RW, Magann EF, Martin JN Jr: Maternal mortality associated with HELLP (hemolysis, elevated liver enzymes, and low platelets) syndrome. *Am J Obstet Gynecol* 181: 924-928, 1999
- 8) Ito T, Sakai T, Inagawa S, Utsu M, Bun T: MR angiography of cerebral vasospasm in preeclampsia. *AJNR Am J Neuroradiol* 16: 1344-1346, 1995
- 9) Kirkpatrick AW, Chun R, Brown R, Simons RK: Hypothermia and the trauma patient. *Can J Surg* 42: 333-343, 1999
- 10) Martin JN Jr, Blake PG, Perry KG Jr, McCaul JF, Hess LW, Martin RW: The natural history of HELLP syndrome: patterns of disease progression and regression. *Am J Obstet Gynecol* 164: 1500-1509, 1991
- 11) Martin JN Jr, Perry KG Jr, Blake PG, May WA, Moore A, Robinette L: Better maternal outcomes are achieved with dexamethasone therapy for postpartum HELLP (hemolysis, elevated liver enzymes, and thrombocytopenia) syndrome. *Am J Obstet Gynecol* 177: 1011-1017, 1997
- 12) Matsuda Y, Tomosugi T, Maeda Y, Kamitomo M, Kanayama N, Terao T: Cerebral magnetic resonance angiographic findings in severe preeclampsia. *Gynecol Obstet Invest* 40: 249-252, 1995
- 13) Paternoster DM, Rodi J, Santarossa C, Vanin M, Simioni P, Girolami A: Acute pancreatitis and deep vein thrombosis associated with HELLP syndrome. *Minerva Ginecol* 51: 31-33, 1999
- 14) Pereira SP, O'Donohue J, Wendon J, Williams R: Maternal and perinatal outcome in severe pregnancy-related liver disease. *Hepatology* 26: 1258-1262, 1997
- 15) Schaefer PW, Buonanno FS, Gonzalez RG, Schwamm LH: Diffusion-weighted imaging discriminates between cytotoxic and vasogenic edema in a patient with eclampsia. *Stroke* 28: 1082-1085, 1997
- 16) Shiozaki T, Sugimoto H, Taneda M, Oda J, Tanaka H, Hiraide A, Shimazu T: Selection of severely head injured patients for mild hypothermia therapy. *J Neurosurg* 89: 206-211, 1998

- 17) Sibai BM, Ramadan MK, Usta I, Salama M, Mercer BM, Friedman SA: Maternal morbidity and mortality in 442 pregnancies with hemolysis, elevated liver enzymes, and low platelets (HELLP syndrome). *Am J Obstet Gynecol* 169: 1000-1006, 1993
- 18) Tompkins MJ, Thiagarajah S: HELLP (hemolysis, elevated liver enzymes, and low platelet count) syndrome: the benefit of corticosteroids. *Am J Obstet Gynecol* 181: 304-309, 1999
- 19) Trommer BL, Homer D, Mikhael MA: Cerebral vasospasm and eclampsia. *Stroke* 19: 326-329, 1988
- 20) Vigil-De Gracia P, Garcia-Caceres E: Dexamethasone in the post-partum treatment of HELLP syndrome. *Int J Gynaecol Obstet* 59: 217-221, 1997
- 21) Weinstein L: Syndrome of hemolysis, elevated liver enzymes, and low platelet count: a severe consequence of hypertension in pregnancy. *Am J Obstet Gynecol* 142: 159-167, 1982
- 22) Westaby S: Coagulation disturbance in profound hypothermia: the influence of anti-fibrinolytic therapy. *Semin Thoracic Cardiovasc Surg* 9: 246-256, 1997
- 23) Wilde JT: Hematological consequences of profound hypothermic circulatory arrest and aortic dissection. *J Card Surg* 12: 201-206, 1997
- 24) Will AD, Lewis KL, Hinshaw DB Jr, Jordan K, Cousins LM, Hasso AN, Thompson JR: Cerebral vasoconstriction in toxemia. *Neurology* 37: 1555-1557, 1987
- 25) Yalcin OT, Sener T, Hassa H, Ozalp S, Okur A: Effects of postpartum corticosteroids in patients with HELLP syndrome. *Int J Gynaecol Obstet* 61: 141-148, 1998

Address reprint requests to: T. Inamura, M.D., Department of Neurosurgery, Graduate School of Medical Sciences, Kyushu University, 3-1-1 Maidashi, Higashi-ku, Fukuoka 812-8582, Japan.