

# Cerebral Blood Flow Velocity in Two Patients With Neonatal Cerebral Infarction

Shigeru Nishimaki, MD, Kazuo Seki, MD, and Shumpei Yokota, MD

Cerebral blood flow velocity was measured in the middle cerebral artery of two patients who exhibited unilateral neonatal cerebral infarction during the neonatal period. Doppler studies demonstrated increases in cerebral blood flow velocity but decreases in the resistance index on the affected side of the middle cerebral artery in the neonate who developed hemiplegia with cystic encephalomalacia, although the neonate with normal neurologic outcome exhibited symmetric cerebral blood flow velocity and resistance index. The asymmetry in cerebral blood flow velocity measurements of both middle cerebral arteries may be useful to evaluate the severity of brain damage and predict the neurodevelopmental prognosis of unilateral neonatal cerebral infarction. © 2001 by Elsevier Science Inc. All rights reserved.

Nishimaki S, Seki K, Yokota S. Cerebral blood flow velocity in two patients with neonatal cerebral infarction. *Pediatr Neurol* 2001;24:320-323.

## Introduction

Neonatal cerebral infarction is a relatively common identifiable cause of neonatal seizures. Occlusion of a major cerebral artery is due to an embolic or thrombotic origin. Possible causes of the infarction are birth asphyxia, traumatic delivery, infection, congenital heart disease,

twin-to-twin transfusion syndrome, and polycythemia. Some investigators have estimated that the prevalence of unilateral neonatal cerebral infarction in infants of 32 weeks gestation and higher is approximately one in 4,000 [1]. The majority of previous studies describe neonatal cerebral infarction corresponding to the vascular distribution of the middle cerebral artery. The affected neonates in previous studies have demonstrated the unilateral infarction of the left middle cerebral artery more frequently than the right [1-3].

The published reports illustrate a wide range of neurodevelopmental outcomes after neonatal cerebral infarction. Early electroencephalograms (EEGs) or magnetic resonance imaging (MRI) findings in the neonatal period can be an early guide to prognosis [3]. However, little is known about cerebral blood flow velocity measurements using transcranial Doppler examinations in neonatal cerebral infarction [2,4]. The aim of this study was to evaluate whether changes in cerebral blood flow velocity predict the severity of brain damage and later neurodevelopmental outcome in neonates with cerebral infarction.

## Methods

The cerebral blood flow velocity in the middle cerebral artery at the level of the thalami was measured by a transtemporal approach. We recorded stable waveforms and investigated peak systolic velocity and end diastolic velocity by pulsed Doppler ultrasonography (model SONOS 1000, Hewlett Packard, Palo Alto, CA) using a 7.5-MHz transducer. The scanning angle was approximately 0 degrees, and Doppler signals were maximum. A resistance index, which is regarded as a measure of resistance, was calculated from the following formula of Pourcelot:

$$\text{Resistance index} = (\text{Peak systolic velocity} -$$

$$\text{End diastolic velocity})/\text{peak systolic velocity} [5]$$

At the time of Doppler examinations, our neonates were in the sleep state with stable spontaneous respiration, and they exhibited no evidence of hypoxia, hypercapnia, or acidosis. Patent ductus arteriosus and other congenital heart diseases were not detected by pediatric cardiologists.

## Results

### Patient 1

This male was born at 39 weeks gestation via forceps for fetal distress. Pregnancy was uneventful except for well-controlled insulin-dependent diabetes mellitus. There was no meconium staining of the amniotic fluid and no

From the Department of Pediatrics; Yokohama City University School of Medicine; Yokohama, Japan.

Communications should be addressed to:  
Dr. Nishimaki; Department of Pediatrics; Yokohama City University School of Medicine; 3-9, Fukuura; Kanazawa-ku; Yokohama, Kanagawa, 236-0004, Japan.  
Received August 21, 2000; accepted January 16, 2001.

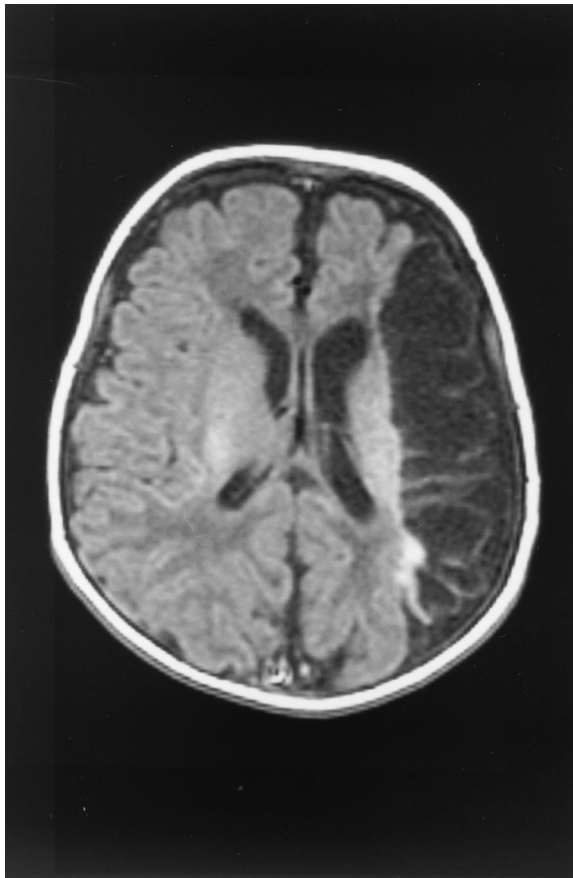


Figure 1. Axial MRI (TR = 440, TE = 15) of Patient 1 at 1 month of age reveals cystic appearance in the territory of the left main branch of the middle cerebral artery. Right mild hemiplegia is presented.

umbilical cord acidosis. Birth weight was 3,692 gm (heavy for gestation), and Apgar scores were seven at 1 minute and nine at 5 minutes. At 3 days of age, the patient was admitted to our neonatal intensive care unit (NICU) because of apnea and clonic seizure of the right arm and leg. Hypoglycemia was not detected. The EEG at admission revealed asymmetric sharp waves in the presence of a normal background. MRI findings indicated the cerebral infarction in the territory of the left main branch of the middle cerebral artery at 3 days of age and cystic appearance at 1 and 7 months of age (Fig 1). Right mild hemiplegia was presented; however, no mental retardation was apparent.

Doppler examinations at 4 and 11 days of age revealed asymmetric cerebral blood flow velocity measurements between the right and left middle cerebral artery. The peak systolic blood flow velocities were greater than 40% higher, and the end-diastolic blood flow velocities were greater than 60% higher in the left middle cerebral artery than in the right middle cerebral artery. There were also marked differences in the resistance index values between the left and right middle cerebral artery (0.58 vs 0.71 at 4 days of age and 0.45 vs 0.71 at 11 days of age, respectively). The resistance index value at 11 days of age was

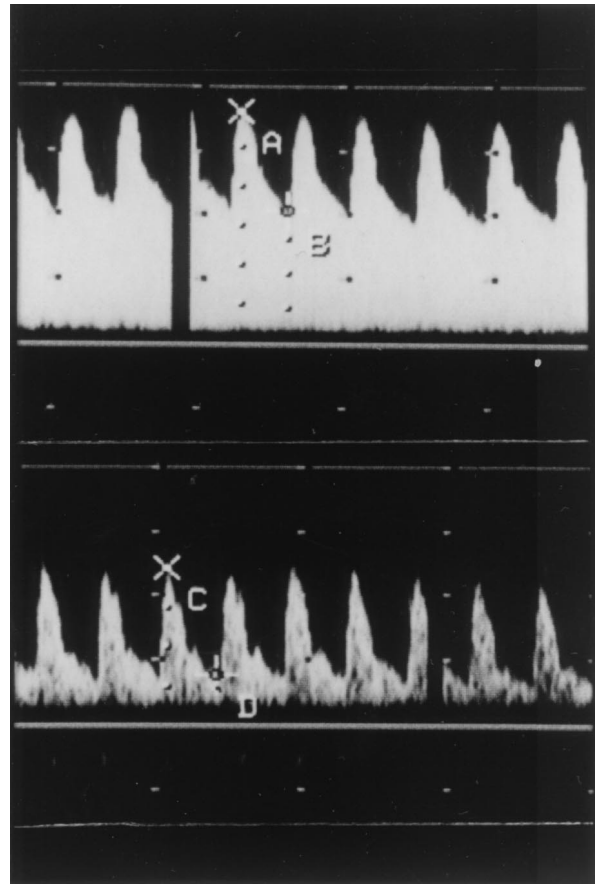


Figure 2. Doppler examinations of Patient 1 performed at 11 days of age demonstrate the peak systolic and end-diastolic blood flow velocities are higher in the left middle cerebral artery (upper) than in the right (lower). In contrast, resistance index values are lower in the left middle cerebral artery (upper) than in the right (lower).

greater than 37% lower on the left side compared with the contralateral side (Fig 2).

### Patient 2

This female was born at 39 weeks gestation via forceps for prolonged delivery. Birth weight was 3,240 gm (appropriate for gestation), and Apgar scores were eight at 1 minute and eight at 5 minutes. At 3 days of age, she exhibited clonic seizure of the right arm and leg. MRI findings at 3 and 11 days of age revealed cerebral infarction with localized changes in the left temporal lobe, and computed tomography (CT) at 5 months of age indicated mild anterior temporal lobe atrophy but no cystic change (Fig 3). The patient's neurologic examination and developmental assessment were both normal.

Doppler examinations at 4 and 8 days of age demonstrated no asymmetric cerebral blood flow velocity measurements of both middle cerebral artery. The peak systolic and end-diastolic blood flow velocities differed by less than 15%. With regard to the resistance index values,

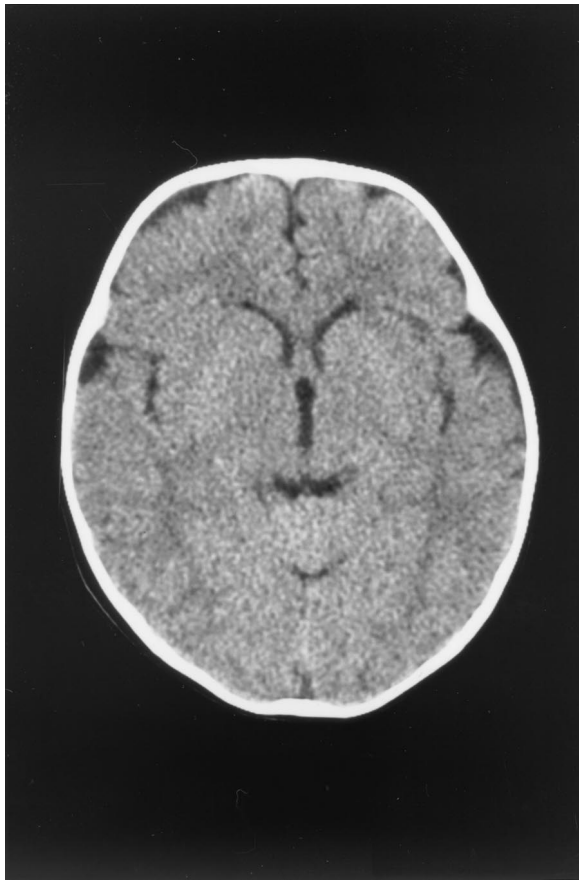


Figure 3. CT scan of Patient 2 reveals mild anterior temporal lobe atrophy (but no cystic appearance) at 5 months of age. Patient 2 was normal on both neurologic examination and developmental assessment.

side-to-side differences were not presented (0.72 vs 0.67 at 4 days of age and 0.64 vs 0.66 at 8 days of age, respectively).

### Discussion

This study found several meaningful relationships between the cerebral blood flow velocity measurements during the neonatal period and the later neurodevelopmental outcome in patients of unilateral neonatal cerebral infarction. The systolic and diastolic blood flow velocities were increased, but the resistance index values were markedly decreased on the affected side of the middle cerebral artery in the neonate who developed hemiplegia with cystic encephalomalacia. On the other hand, these side-to-side differences were not present in the neonate who exhibited normal brain imaging and good neurodevelopmental outcome. The asymmetry in cerebral blood flow velocity measurements of both sides is the main finding.

Brain imaging is essential for the diagnosis of cerebral infarction [3]. Our neonate who developed hemiplegia with cystic encephalomalacia demonstrated the increased cerebral blood flow velocity but decreased resistance

index values on the affected side of the middle cerebral artery. On the other hand, the neonate who was developing normally exhibited normal brain imaging and no asymmetric cerebral blood flow velocity measurements of the two middle cerebral arteries. We found that the magnitude of the increases in cerebral blood flow velocity and the decreases in resistance index values in the cerebral arteries are associated with the severity of brain damage.

Messer et al. [2] observed that cerebral blood flow velocity values are completely absent or extremely reduced on the affected side of the middle cerebral artery in two patients of unilateral neonatal cerebral infarction during the first months of life. Perlman et al. [4] also demonstrated transient decreases in cerebral blood flow velocity on the affected side compared with the contralateral unaffected side of the middle cerebral artery in infants with cerebral infarction. On the other hand, our results revealed normal or increased cerebral blood flow velocity on the affected side of the middle cerebral artery in unilateral neonatal cerebral infarction. It is unclear why our neonates demonstrated no decrease in cerebral blood flow velocity measurements. Olsen and Lassen [6] reported reperfusion leading to hyperemia is observed in about one third of adult patients with middle cerebral artery occlusion 1-4 days after the stroke. Therefore we would suggest that reopening of occluded cerebral vessel had occurred before Doppler study performed.

Birth asphyxia is also the most important cause of ischemic brain injury in neonates born at term. Archer et al. [7] and Levene et al. [8] reported an abnormal Doppler signal with a resistance index value below 0.55 in the anterior cerebral artery of asphyxiated neonates correlating with adverse neurodevelopmental outcome. They describe a state of cerebral hyperemia as *luxury perfusion* after ischemic brain injury. The luxury perfusion occurs as the result of local vasodilation. Our neonate who exhibited right spastic hemiplegia also demonstrated a decreased resistance index value below 0.55 on the affected side of the middle cerebral artery. We speculate that the asymmetry in resistance index values may result from the focal luxury perfusion after focal ischemic brain injury by cerebral infarction. Similar to the previous studies in birth asphyxia, the markedly decreased resistance index values may indicate poor neurodevelopmental prognosis in patients with neonatal cerebral infarction.

In conclusion, our Doppler studies demonstrated the increases in cerebral blood flow velocity but decreases in resistance index values on the affected side of the middle cerebral artery in the neonate who developed hemiplegia with cystic encephalomalacia by infarction whereas the neonate with normal brain imaging and good neurodevelopmental outcome exhibited the symmetric cerebral blood flow velocity and resistance index values. The asymmetry in cerebral blood flow velocity and resistance index values in the neonatal period may be useful to evaluate the severity of brain damage and predict the later neurodevel-

opmental outcome of unilateral neonatal cerebral infarction.

#### References

- [1] **Estan J**, Hope P. Unilateral neonatal cerebral infarction in full term infants. *Arch Dis Child* 1997;76:F88-93.
- [2] **Messer J**, Haddad J, Casanova R. Transcranial Doppler evaluation of cerebral infarction in the neonate. *Neuropediatrics* 1991;22:147-51.
- [3] **Mercuri E**, Rutherford M, Cowan F, et al. Early prognostic indicators of outcome in infants with neonatal cerebral infarction: A clinical, electroencephalogram, and magnetic resonance imaging study. *Pediatrics* 1999;103:39-46.
- [4] **Perlman JM**, Rollins NK, Evans D. Neonatal stroke: Clinical characteristics and cerebral blood flow velocity measurements. *Pediatr Neurol* 1994;11:281-4.
- [5] **Pourcelot, L**. Diagnostic ultrasound for cerebral vascular diseases. In: Donald I, Levi S, eds. Present and future of diagnostic ultrasound. New York: John Wiley & Sons, 1976:141-7.
- [6] **Olsen TS**, Lassen NA. A dynamic concept of middle cerebral artery occlusion and cerebral infarction in the acute state based on interpreting severe hyperemia as a sign of embolic migration. *Stroke* 1984;15:458-68.
- [7] **Archer LNJ**, Levene MI, Evans DH. Cerebral artery Doppler ultrasonography for prediction of outcome after perinatal asphyxia. *Lancet* 1986;2:1116-8.
- [8] **Levene MI**, Fenton AC, Evans DH, Archer LNJ, Shortland DB, Gibson NA. Severe birth asphyxia and abnormal cerebral blood-flow velocity. *Develop Med Child Neurol* 1989;31:427-34.