

Postoperative cortical venous infarction in tumours firmly adherent to the cortex

Katsuzo Kiya MD, Hideki Satoh MD, Tatsuya Mizoue MD, Yasuyuki Kinoshita MD

Department of Neurosurgery, Hiroshima Prefectural Hospital, Hiroshima, Japan

Summary It is sometimes difficult to separate extra-axial tumours from the cortical veins in case of tumours attaching tightly to the cortex and the cortical veins. We present two patients having a postoperative cortical venous infarction. A 59 year old female had convexity meningioma above the motor cortex where abnormal cortical anastomotic veins developed. Transient hemiparesis occurred after total removal of the tumour because of venous infarction and cyst formation resulting from sacrifice of these veins which were tightly adherent to the tumour surface. A 15 year old boy with immature teratoma of the pineal region, showing several draining veins around the vascular-rich tumour, presented transient drowsiness, diplopia and partial impairment of bilateral visual acuity postoperatively because of localised cortical brain and venous damage. It is important to make an effort to preserve main cortical veins during operation as much as possible, even if the tumour adheres to the cortical surface. © 2001 Harcourt Publishers Ltd

Keywords: brain neoplasm, cerebral vein, venous infarction, surgery, surgical complication

INTRODUCTION

Postoperative cortical venous infarction is one of the important complications occasionally affecting outcome in brain tumours.^{1–4} Cortical venous damage is encountered in approaching the deep-seated tumour and separating it along the border of the tumour involving the veins or attaching to them tightly.³ Although attention is usually paid to the large veins and dural sinus for preventing postoperative venous infarction, damage of smaller veins such as cortical anastomotic vein is not so much considered to cause postoperative neurological manifestation. We present two patients having a postoperative cortical venous infarction due to firm adhesion to the tumour surface.

CASE STUDIES

Case 1

The first patient is a 59 year old female with convexity meningioma at the right motor cortex. As she had dizziness, CT scan was taken and showed meningioma incidentally. The tumour size gradually increased to 35 mm in a year. She was admitted to our hospital for surgical removal of the tumour. MRI demonstrated that the tumour was located above the right motor cortex with no peritumoural oedema (Fig. 1). Carotid angiogram revealed thin homogenous tumour stain at the frontoparietal region. The anterior parietal vein could not be seen, supposedly due to tumour compression in venous phase. On the contrary, several cortical anastomotic veins accumulated under and around the tumour and drained toward the frontal ascending veins (Fig. 2). During the operation, the tumour was found to adhere to the cortical surface and cortical veins tightly. Some part of the cortical veins got damaged as a result of difficulty of sharp dissection at the portion involved in the tumour or attaching very closely to the tumour surface. After total removal of the tumour was accomplished without ease, the postoperative course was uneventful for the first 3 days with no abnormality on CT scan. Histological examination of the tumour was confirmed as transitional meningioma. On the following day, hemiparesis and hemisensory disturbance of the left side appeared and gradually worsened.

Repeated CT scan showed rather extensive oedema and cyst formation at the right frontoparietal region (Fig. 3), suggesting the venous infarction caused by damage of the cortical anastomotic veins. MR venography demonstrated no venous channels around the right frontoparietal region corresponding to the cavity of the tumour removal. The symptoms fluctuated under the influence of a growing cyst which was aspirated a couple of times. Left-sided hemiparesis gradually resolved by 6 weeks along with attenuation of low density area on CT scan. She resumed work with no sign of neurological deficit.

Case 2

A 15 year old boy suffered from headache and nausea for 2 weeks without any neurological deficit. MR image revealed a heterogeneously enhanced mass of 45 × 35 mm in size at the pineal region associated with ventricular dilatation (Fig. 4). Vertebral angiogram showed numerous draining veins around the vascular-rich tumour. The posteromedial parietal vein of the left side was one of the main drainers running through the medial occipital lobe into the superior sagittal sinus (Fig. 5). During the operation using the right sided occipital transtentorial approach, the tumour was tightly adherent to the bilateral deep medial occipital lobe and brainstem so that it was not so easy to strip the tumour margin off the cortex without localised small venous and cortical damage, although the deep main venous system such as a basal vein of Rosenthal could be preserved. Subtotal removal of the tumour was accomplished except for the portion around the vein of Galen. Parinaud's sign appeared immediately without remarkable neurological deficits in the recovery room. The next day, he began to have a sleepy tendency in addition to restriction of bilateral eye movement and severe impairment of visual acuity. CT scan revealed irregular low density areas on both sides of the medial occipital lobe, though the approach was only through the right occipital lobe (Fig. 6). A low density area at the left occipital lobe extending toward parietal lobe seemed to result from obliteration of the left posteromedial parietal vein. Repeated MR image disclosed that the range of brain damage extended not only to the bilateral occipital lobes but also to dorsal midbrain and thalamus (Fig. 7). These lesions at the deep site were found mainly along the portion adjacent to the tumour. It seemed that localised injuries of the cortical surface and veins infarction around the cavity of tumour removal. Histology diagnosed this tumour as an immature teratoma.

Radiochemotherapy was effective for tumour control afterwards. Difficulty in preserving recent memory and irregular narrowness of visual field have bothered him for 4 years. Recently, he has been able to return to school.

Correspondence to: Katsuzo Kiya MD, Department of Neurosurgery, Hiroshima Prefectural Hospital 1-5-54 Ujina-kanda, Minami-ku, Hiroshima, 734-8530 Japan. Tel.: +81-(0)82-254-1818; Fax: +81-(0)82-253-8274

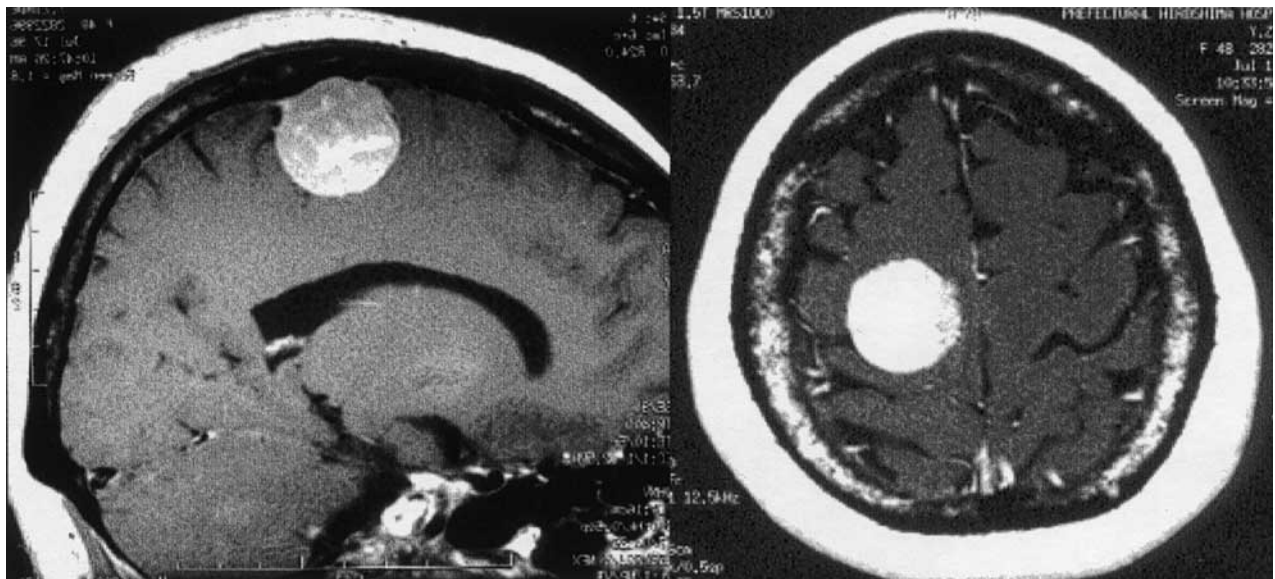


Fig. 1 Preoperative contrast-enhanced MR image showing hyperintense lesion at the right motor cortex.

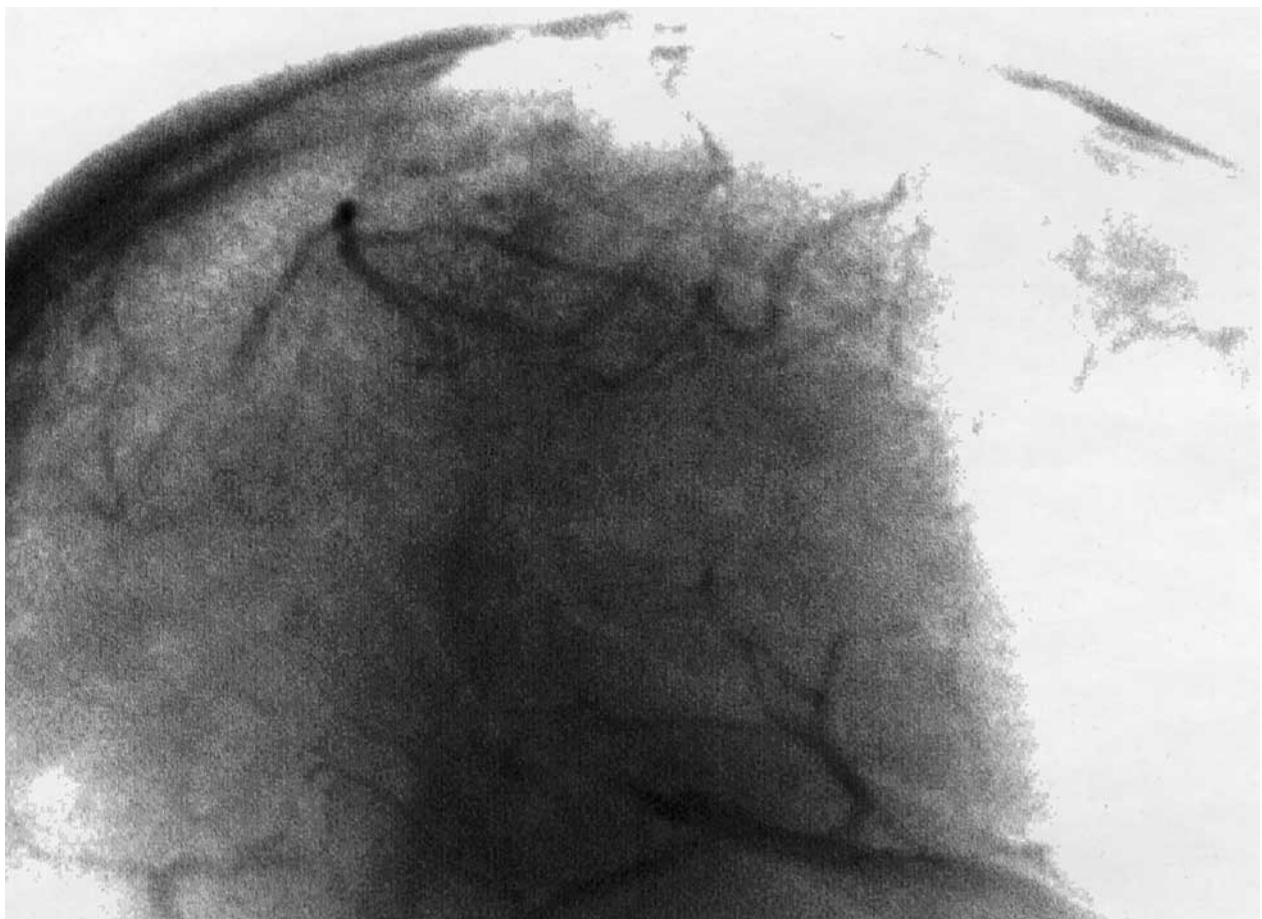


Fig. 2 Angiogram (lateral view in venous phase) revealing several cortical anastomotic veins around the tumour. The anterior parietal vein could not be seen.

DISCUSSION

The importance of preserving the bridging vein and dural sinus during surgery is well-known. Intraoperative venous obliteration may cause cerebral oedema, brain infarction, and intracerebral haemorrhage⁵⁻⁷ which results in occasional clinical deterioration.^{1-4,8}

Attention is always paid to larger venous systems such as Labbe's vein, Rolandic vein, vein of Galen and dural sinus, to avoid intraoperative damage, because of the possibility of incurring severe venous infarction. However, the significance of smaller venous systems such as the cortical anastomotic vein is not noticed

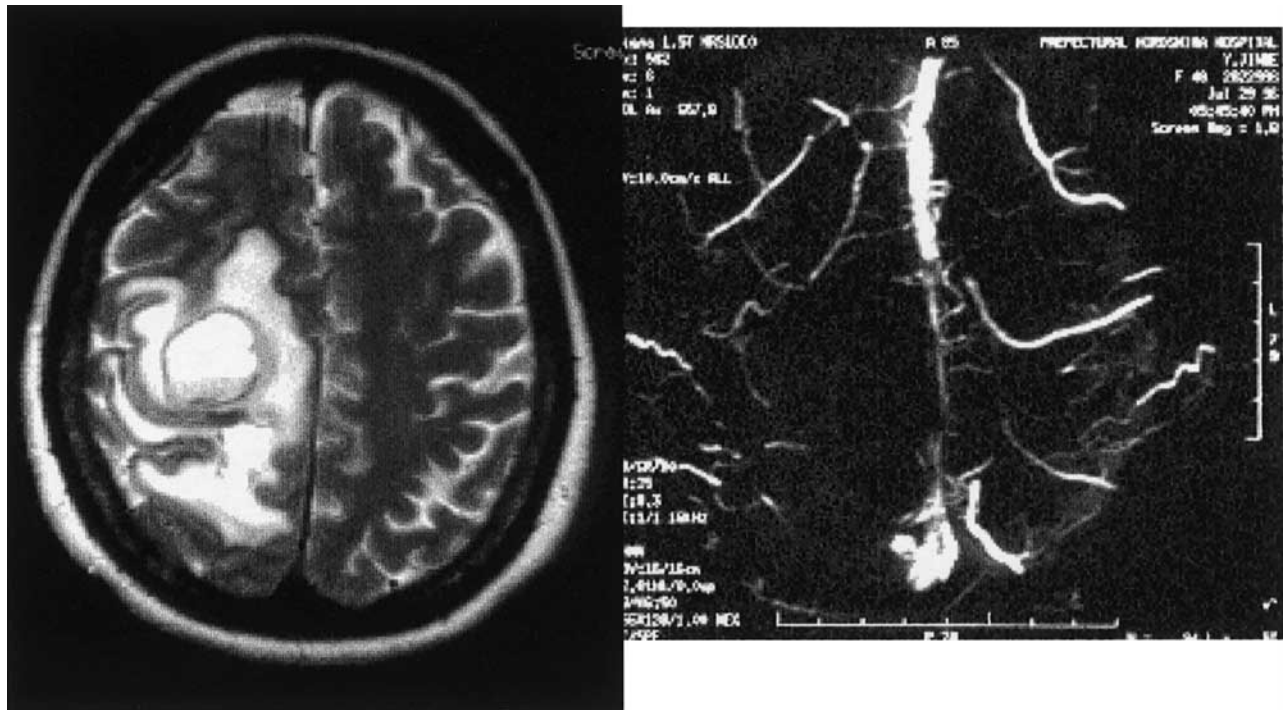


Fig. 3 Left: Postoperative T2-weighted MR image showing hyperintense area associated with cyst formation. Right: MR venogram suggesting venous infarction.

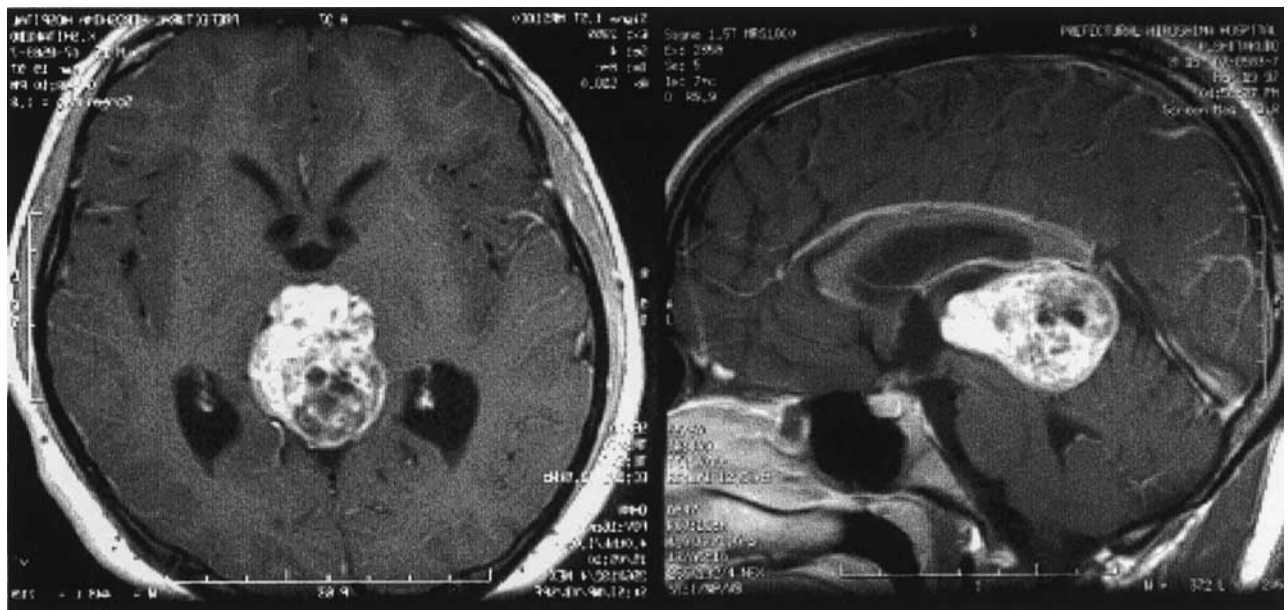


Fig. 4 Preoperative contrast-enhanced MR image demonstrating heterogeneously enhanced mass at the pineal region.

so much. This report emphasises importance of keeping even the smaller cortical veins patent in the course of tumour separation from these veins which are involved in the tumour or firmly attached to it. Samii et al.² suggested four mechanisms for venous complication during surgery: lacerations of venous sinuses; obliteration of veins or venous sinuses; brain retraction interfering with venous flow; and haemodynamic changes in the venous system due to removal of extensive lesions. It is supposed that the cause of venous infarction in case 1 was based on cortical venous obliteration, and that in case 2 was related to the brain retraction as well as lacerations of cortical veins and cortical surface.

Obliteration of the cortical veins during surgery does not always result in clinical damage because collateral pathways of the cerebral

venous system vary greatly among individuals.⁹ However, in case 1, venous infarction occurred after damage of the cortical veins which were tightly adherent to the tumour surface. Venous phase on preoperative cerebral angiogram revealed no obvious anterior parietal vein, supposedly due to compression by the tumour although cortical anastomotic veins connecting the ascending venous group of the lateral frontal surface were visible. Intraoperative partial damage of the cortical anastomotic veins brought venous infarction at the sensorimotor area in addition to no venous drainage into the anterior parietal vein. Cyst formation in this area after reduction of local compression by the tumour reinforced clinical deterioration. Fortunately these symptoms disappeared in 6 weeks. This interval of manifesting symptoms from

onset to recovery due to venous infarction seems to be approximately 1–2 months as we reported previously.³ This case suggests that precise comprehension of the venous drainage system around the tumour before operation is important, and effort to preserve all cortical veins having a function of venous drainage relevant to the normal cortex is necessary even if adhering tightly to the tumour. This case also indicates that much attention should be paid to abnormal cortical anastomotic veins in the area which the tumour occupies. Oka et al.¹⁰ reported that under normal circumstances, end-to-end anastomosis among the superficial cortical veins is a part of the collateral circulation and may function as anastomotic

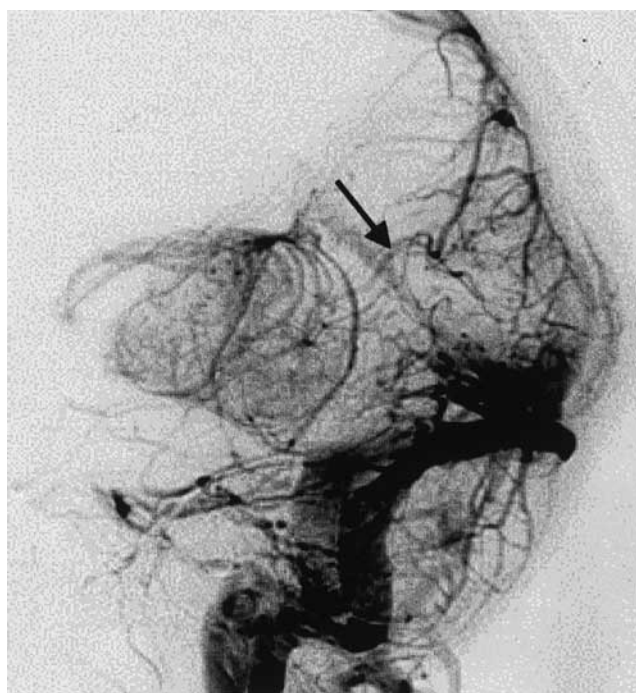

Fig. 5 Angiogram (lateral view in venous phase) showing several draining veins including left posteromedial parietal vein (arrow) around the tumour.

pathways when the superior sagittal sinus is occluded by parasagittal meningiomas. Convexity meningioma may affect cortical veins running under the tumour as a function of anastomotic pathways as shown in case 1.

It is sometimes difficult to separate the extra-axial tumour from its surrounding cortical surface and veins, especially in tumours having rich vascularity, located in the deep region, and adhering tightly to the surrounding tissue. In case 2, local damage of the cortical brain and cortical venous channels including the left posteromedial parietal vein as well as the internal occipital vein in the process of the tumour removal resulted into the clinical deterioration, although the deep major venous system was not injured and only the right sided occipital lobe was retracted intermittently in the lateral-semiprone position. The occipital transtentorial approach provides a larger exposure of the quadrigeminal region but tends to require brain retraction and sacrifice of bridging veins such as the internal occipital vein, resulting in contusion of the occipital lobe and venous infarction and causing a homonymous hemianopsia.^{1,12,13} The posteromedial parietal vein, which may connect the posterior calcarine artery, must also pay attention not to sacrifice during the operation, especially when this vein is relevant to the tumour as a draining vein. To obtain a wider operative view of the pineal region in a large and vascular tumour, the combined supra/infratentorial-transsinos approach was reported by Ziyal et al.¹⁴

To avoid intraoperative venous infarction, several strategies have been pointed out in general. In the management of surgical intervention, it is important to check development of abnormal and collateral venous channels on angiography before operation,^{15,16} and consider an operative approach not to injure the bridging veins.¹⁷ When a cortical vein is thought to be an obstacle in a surgical process, large bridging veins should be preserved with the technique of stripping them from the cortex,¹⁸ and small-sized veins leading out of some veins composing the large bridging vein may be cut off. Monitoring systems such as laser doppler flow meter,⁹ venous stump pressure,^{6,20} somatosensory evoked potentials²¹ and microvascular doppler sonography²² are available for predicting brain damage after temporary venous occlusion. We sometimes measure flow velocity and flow direction of the cortical veins, using microvascular doppler sonography under

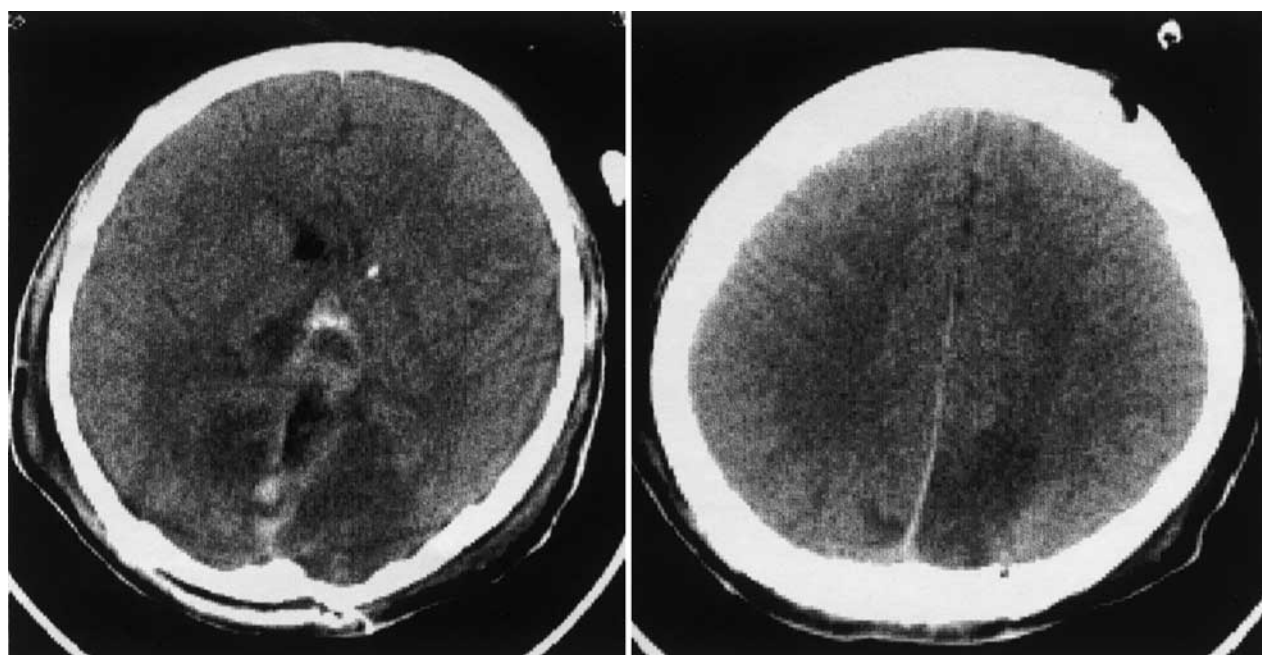


Fig. 6 Postoperative CT scan showing low density area at the bilateral occipital lobes and left parietal lobe.

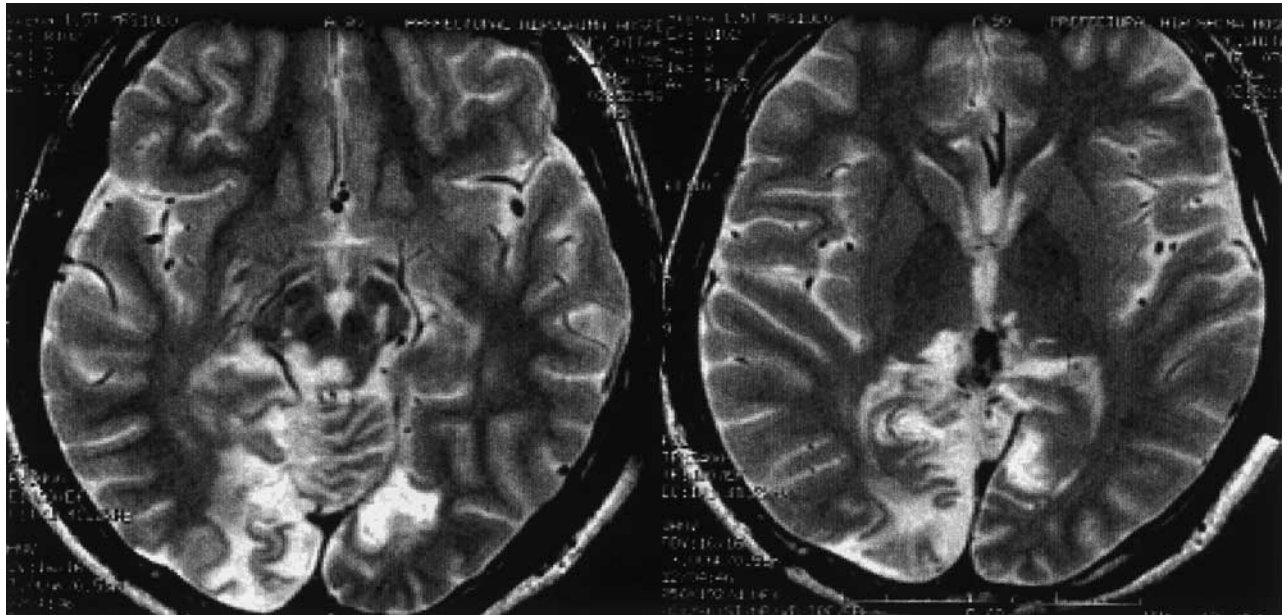


Fig. 7 T2-weighted MR image demonstrating postoperative brain damage at bilateral occipital lobes, dorsal midbrain, and thalamus.

the temporary venous clump, to sacrifice the vein with safety in meningioma. In case of adhesive and invasive extra-axial tumour, how to find a rather loose space between tumour and cortical sulcus may be the first step to expose the cortical surface and vein under the tumour meticulously. Keeping a plane between the tumour and outer layer of the vein seems to be important to avoid damage of the cortical vein during dissection. At the time a main important draining vein is obstructed by chance, Auque et al.²³ recommended stopping the surgical procedure and postponing the removal of the tumour for some weeks, allowing the veins to re-establish an adequate blood supply.

REFERENCES

- Kanno T, Kasama A, Shoda M, Yamaguchi C, Kato Y. A pitfall in the interhemispheric translamina terminalis approach for the removal of a craniopharyngioma. Significance of preserving draining veins. Part 1. *Surg Neurol* 1989; 32: 111–115.
- Samii M, Klekamp J, Vorkapic P. Obstruction of cerebral veins and sinuses: Consequences, treatment, and preventive measures. In: Hakuba A (ed.) *Surgery of the Intracranial Venous System*. Tokyo: Springer-Verlag, 1996; 365–374.
- Kiya K, Yuki K, Ikawa F, Takeshita S, Hamasaki O, Uozumi T. Clinical problems related to the obliteration of intracranial veins during operations for brain tumours. In Hakuba A (ed.) *Surgery of the Intracranial Venous System*. Tokyo: Springer-Verlag, 1996; 295–298.
- Kubota M, Ono J, Saeki N, Yamaura A. Postoperative brain damage due to sacrifice of bridging veins during the anterior interhemispheric approach. In: Hakuba A (ed.) *Surgery of the Intracranial Venous System*. Tokyo: Springer-Verlag, 1996; 291–294.
- Miller JD, Stanek AE, Langfitt TW. Cerebral blood flow regulation during experimental brain compression. *J Neurosurg* 1973; 39: 186–196.
- Yoshimoto Y, Endo M, Mori T, Wakai S. Correlation between venous stump pressure and brain damage after cortical vein occlusion: an experimental study. *J Neurosurg* 1997; 86: 694–698.
- Fries G, Perneczky A. Intraoperative obliteration of cerebral veins with special reference to the vein of Labbe. In Hakuba A (ed.) *Surgery of the Intracranial Venous System*. Tokyo: Springer-Verlag, 1996; 299–303.
- Kageyama Y, Fukuda K, Kobayashi S et al. Cerebral vein disorders and postoperative brain damage associated with the pterional approach in aneurysmal surgery. *Neuro Med Chir (Tokyo)* 1992; 32: 733–738.
- Oka K, Rhoton AL, Barry M, Rodriguez R. Microsurgical anatomy of the superficial veins of the cerebrum. *Neurosurgery* 1985; 17: 711–748.
- Oka K, Go Y, Kimura H, Tomonaga M. Obstruction of the superior sagittal sinus caused by parasagittal meningiomas: the rule of collateral venous pathways. *J Neurosurg* 1994; 81: 520–524.
- Reid WS, Clark WK. Comparison of the infratentorial and transtentorial approaches to the pineal region. *Neurosurgery* 1978; 3: 1–8.
- Tanaka R. Occipital transtentorial approach for pineal tumours by lateral-semiprone position. *No Shinkei Geka* 1990; 18: 413–422.
- Bruce JN, Stein BM. Surgical management of pineal region tumours. *Acta Neurochir (Wien)* 1995; 134: 130–135.
- Ziyal IM, Sekhar LN, Salas E et al. Combined supra/infratentorial-transsinos approach to large pineal region tumours. *J Neurosurg* 1998; 1050–1057.
- Odake G. Meningioma of the falcotentorial region: Report of two cases and literature review of occlusion of the Galenic system. *Neurosurgery* 1992; 30: 788–794.
- Asari S, Yabuno N, Ohmoto T. Collateral venous channels in occlusion of deep cerebral veins and sinuses. *Brain and Nerve (Tokyo)* 1994; 46: 935–939.
- Kurokawa Y, Uede T, Honda O et al. Technical tactics to preserve cortical venous drainage in interhemispheric approach for anterior communicating artery aneurysms. *No Shinkei Geka* 1994; 22: 29–34.
- Sugita K, Kobayashi S, Yokoo A. Preservation of large bridging veins during brain retraction: technical note. *J Neurosurg* 1982; 57: 856–858.
- Nakase H, Kakizaki T, Miyamoto K, Hiromatsu K, Sakaki T. Use of local cerebral blood flow monitoring to predict brain damage after disturbance to the venous circulation: cortical vein occlusion model by photochemical dye. *Neurosurgery* 1995; 37: 280–286.
- Spetzler RF, Dasgupta CP, Pappas CTE. The combined supra- and infratentorial approach for lesions of the petrous and clival regions: experience with 46 cases. *J Neurosurg* 1992; 76: 588–599.
- Al-Mefty O, Krisht AF. The dangerous veins. In: Hakuba A (ed.) *Surgery of the Intracranial Venous System*. Tokyo: Springer-Verlag, 1996; 338–345.
- Morimoto T, Miyamoto K, Ishida Y, Sakaki T. Hemodynamics of bridging veins during surgery: usefulness of microvascular doppler sonography. In Hakuba A (ed.) *Surgery of the Intracranial Venous System*. Tokyo: Springer-Verlag, 1996; 125–131.
- Auque J, Civit T, Braun M. Delayed removal of midline meningiomas after previous surgical venous sacrifice. In: Hakuba A (ed.) *Surgery of the Intracranial Venous System*. Tokyo: Springer-Verlag, 1996; 273–275.