

# Spontaneous Cerebellar Hemorrhage due to a Juvenile Pilocytic Astrocytoma

## Case Report and Review of the Literature

Ali H. Mesiwala Anthony M. Avellino Theodore S. Roberts  
Richard G. Ellenbogen

Department of Neurological Surgery, Children's Hospital and Regional Medical Center,  
University of Washington School of Medicine, Seattle, Wash., USA

### Key Words

Cerebellum · Hemorrhage, spontaneous · Pilocytic astrocytoma, juvenile

### Abstract

A 13-year-old boy presented to the emergency room with headaches and ataxia. Imaging studies revealed a cerebellar hemorrhage within a posterior fossa tumor. The patient underwent complete resection of this lesion and made a full recovery. Microscopic examination of this lesion revealed a juvenile pilocytic astrocytoma.

Copyright © 2001 S. Karger AG, Basel

### Introduction

Cerebellar astrocytomas account for approximately 10% of all pediatric tumors, and 27% of all pediatric posterior fossa tumors [1]. These lesions most commonly present with signs of cerebellar dysfunction or hydrocephalus; spontaneous cerebellar hemorrhage due to these lesions has only been reported 3 times [2–4]. Spontaneous cerebellar hemorrhages in the pediatric population are an uncommon event, usually arising from vascular abnormalities, trauma or hematological anomalies [5]. We present a case in which a juvenile pilocytic astrocytoma presented as a spontaneous cerebellar hemorrhage.

### Case Report

A 13-year-old boy presented to the emergency room with a 10-day history of headaches, increasing lethargy and balance difficulties. He had been previously well until 10 days prior, when he developed an acute posterior headache.

On examination, he was lethargic, but easily arousable. He followed commands without difficulty and had normal speech. His cranial nerve examination was normal, and he had no evidence of papilloedema. He had full motor strength and normal sensation. Deep tendon reflexes were normoactive and symmetrical. Cerebellar examination revealed bilateral ataxia of the upper limbs, worse on the left than the right. Similarly, he had an ataxic gait, falling to the left. The remainder of his physical examination was normal. A noncontrast computed tomographic (CT) scan (fig. 1) revealed a 4 × 4 × 4 cm irregular, hemorrhagic mass lying within the left cerebellar hemisphere causing compression and deviation of the fourth ventricle to the right and mild hydrocephalus. A gadolinium-enhanced brain magnetic resonance imaging study was then obtained (fig. 2) which confirmed the findings on CT, and demonstrated a fluid/fluid level in the superior aspect of the lesion. Magnetic resonance angiography showed no feeding vessels, evidence of arteriovenous malformation or aneurysm in this location.

The patient was admitted to the neurosurgical intensive care unit for observation and started on high dose dexamethasone.

Two days after admission, the patient underwent placement of an external ventricular drain and posterior fossa craniectomy for gross total resection of this tumor. A hemorrhagic lesion was encountered which appeared to be well encapsulated along its posterior, inferior and superior margins. Along its anterior deep and medial margin, however, there appeared to be invasion within the left medullary velum. The tumor appeared to be grossly hemorrhagic along the inferior portion, while the superior portion appeared grayish and friable.

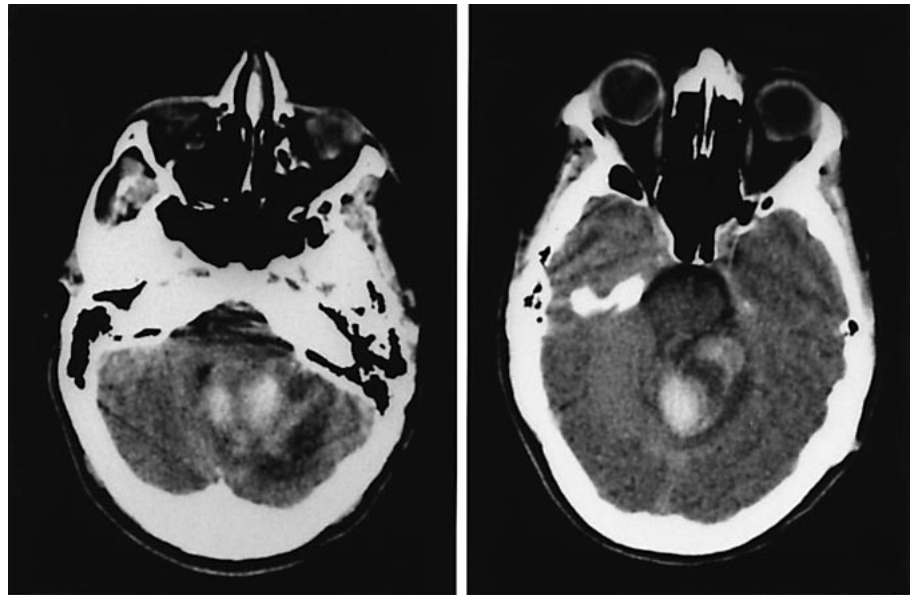
### KARGER

Fax +41 61 306 12 34  
E-Mail karger@karger.ch  
www.karger.com

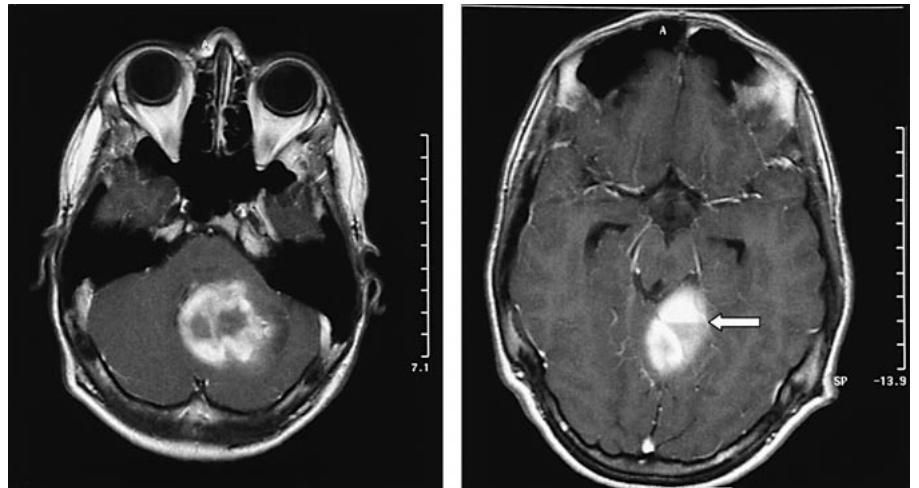
© 2001 S. Karger AG, Basel  
1016-2291/01/0345-0235\$17.50/0

Accessible online at:  
www.karger.com/journals/pne

Richard G. Ellenbogen, MD  
Division of Neurological Surgery, Children's Hospital and Regional Medical Center  
4800 Sand Point Way NE CH-50  
Seattle, WA 98105 (USA)  
Tel. +1 206 526 2544, Fax +1 206 527 3925, E-Mail rellen@chmc.org



**Fig. 1.** Axial noncontrast CT scans demonstrate an irregular, hemorrhagic mass within the left cerebellar hemisphere causing compression of the fourth ventricle and mild hydrocephalus.

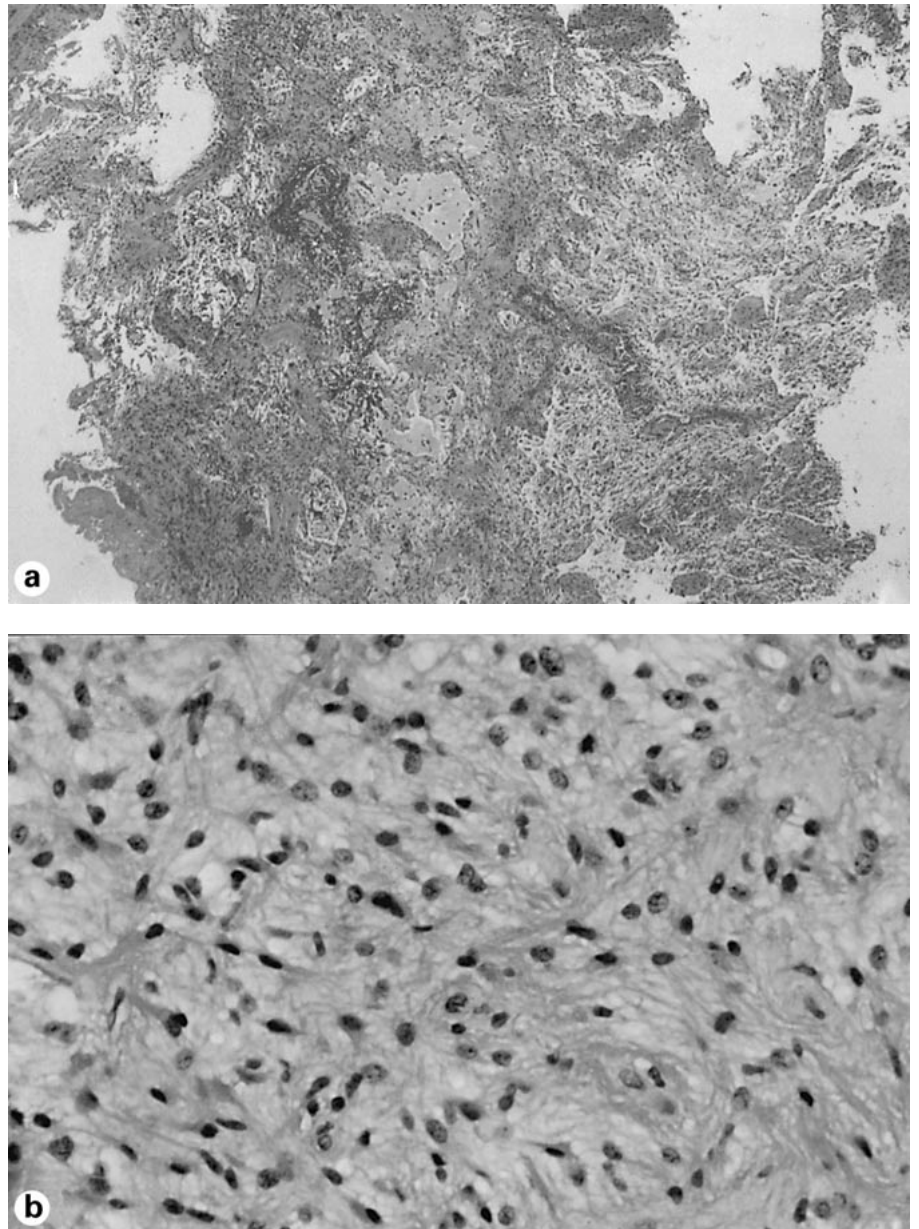


**Fig. 2.** Axial gadolinium-enhanced, T1-weighted MR images reveal a heterogeneously enhancing left cerebellar mass with hemorrhagic central core. Note the fluid/fluid level in the superior aspect of the lesion which is consistent with acute and subacute blood (arrow).

**Table 1.** Spontaneous cerebellar hemorrhage in pediatric tumors

Report	Ref. No.	Number of cases	Patient age/sex	Cerebellar location	Histology	Outcome
Mauersberger and Cuevas-Solorzano, 1977	11	2	10y/M 10y/F	Vermis Vermis	'Spongioblastoma' 'Spongioblastoma'	R E
Vincent et al., 1980	2	1	14y/F	Vermis and right hemisphere	Pilocytic astrocytoma	R
Fogelson et al., 1980	3	1	9y/F	Vermis	Pilocytic astrocytoma	R
Young, 1980	6	1	8m/?	Fourth ventricle, vermis and right hemisphere	Ependymoma	R
Harada et al., 1986	4	1	15y/M	Left hemisphere	Fibrillary astrocytoma	R
Specht et al., 1986	7	1	8y/M	Vermis and right hemisphere	Mixed pilocytic astrocytoma/ oligodendroglioma	E
Present case		1	13y/M	Left hemisphere	Pilocytic astrocytoma	R

y = Years; m = months; R = recovered; E = expired.



**Fig. 3.** Hematoxylin and eosin-stained specimens. **a** Low power ( $\times 4$ ) view demonstrates a lesion of varying cellularity with relatively hypocellular regions of dense stroma alternating with more cellular myxoid areas. Mild cystic degeneration is seen. There is no evidence of vascular proliferation or necrosis. **b** High power ( $\times 40$ ) view of specimen reveals bland cells with round to oval nuclei and focally prominent eosinophilic processes. Nuclear atypia or mitotic activity is not seen.

There was no evidence of invasion into the floor of the fourth ventricle. The patient tolerated this procedure well, and had no new neurologic deficits postoperatively. Postoperative CT scans revealed no evidence of residual tumor. The patient was subsequently discharged home 1 week following his operation. At the time of discharge, his headaches had resolved and he had minimal ataxia.

Microscopic examination revealed a juvenile pilocytic astrocytoma (fig. 3a, b). The tumor had varying cellularity with regions of relatively hypocellular dense stroma alternating with more cellular myxoid areas in which mild cystic degeneration was evident. The cells appeared bland with round to oval nuclei and focally prominent eosinophilic processes. Nuclear atypia, mitotic activity, vascular proliferation and necrosis were not seen.

## Discussion

Acute cerebellar hemorrhage in children is an extremely unusual event. Such hemorrhages are commonly a result of arteriovenous malformations, trauma, infection or hematological abnormalities [5]; a neoplastic origin is rare [2–4, 6, 7, 11]. A review of the literature produced only seven cases [2–4, 6, 7, 11] of posterior fossa tumors presenting as acute cerebellar hemorrhages (table 1); of these, only three were cerebellar pilocytic or fibrillary astrocytomas [2–4].

A careful review of the previously reported cases listed in table 1 revealed the following histological features that may have predisposed these tumors to spontaneous hemorrhage: endothelial proliferation and marked stromal degeneration. In the three previously reported cases of cerebellar pilocytic or fibrillary astrocytomas [2–4], each showed rich vascularity and degeneration of the stroma. Interestingly, in the one case of a mixed cerebellar glioma [7] endothelial proliferation was seen only within the oligodendroglioma component of the lesion; of note, hemorrhage was confined to this portion of the tumor. In our present case, there was no evidence of endothelial proliferation, while mild stromal degeneration was present. It could be conceived, however, that our patient had a large cystic component of the tumor that with trivial head trauma resulted in a large hemorrhage within the cyst.

Cerebellar pilocytic astrocytomas carry a more favorable prognosis than most other brain tumors, because they are histologically benign and amenable to extensive resection. It is clear, however, that a number of factors have an impact on prognosis. In particular, the extent of resection has been strongly associated with progression-free survival: patients undergoing gross total resection appear to have a substantially better prognosis than those undergoing incomplete resection [1]. Brainstem invasion, which is the factor that most often precludes a complete resection, has also been associated with a less favorable prognosis. In addition, histological features indicative of malignancy, such as mitotic figures, endothelial proliferation and necrosis, are clearly associated with a poor outcome [1]. Surprisingly, none of these features were found in our case or

in the previously reported cases of spontaneous hemorrhage.

It is not clear why certain tumors are prone to undergo spontaneous hemorrhage. Speed of tumor growth, vascular invasion, infarction, necrosis and fibrinolysis may all be contributing factors [8, 9]. Previous authors have noted that blood seepage occurs in large brain tumors [10], most likely due to the high degree of vascular proliferation in certain types. The site of fastest growth of a neoplasm is often in the peripheral zone, and brain tissue in this area often undergoes necrosis or infarction; together with the blood supply, brain here is stretched, causing it to bleed [9]. Additionally, vascular invasion by tumor aggregates may cause luminal obstruction, infarction or necrosis of the tumor and associated hemorrhage into the lesion.

Spontaneous cerebellar hemorrhage in children remains an unusual, but clinically emergent event. Prompt evaluation and stabilization of the patient, followed by identification of the underlying structural abnormality is of critical importance. While vascular anomalies, trauma, infection and hematological abnormalities are the most likely etiology of such a bleed, an underlying cerebellar neoplasm must remain in the differential diagnosis.

## Acknowledgments

The authors would like to thank Matthew Bullen for his excellent assistance in preparing the figures for this work. Additionally, we would like to express our gratitude to Laura S. Finn, MD, for reviewing the histology in this case.

## References

- 1 Campbell JW, Pollack IF: Cerebellar astrocytomas in children. *J Neurooncol* 1996;28:223–231.
- 2 Vincent FM, Bartone JR, Jaones MZ: Cerebellar astrocytoma presenting as a cerebellar hemorrhage in a child. *Neurology* 1980;30:91–93.
- 3 Fogelson MH, Oppenheim RE, McLaurin RL: Childhood cerebellar astrocytoma presenting with hemorrhage. *Neurology* 1980;30:669–670.
- 4 Harada K, Hayashi T, Okamoto Y, Shojima K, Utsunomiya H, Maehara F, Sato Y: Cerebellar astrocytoma presenting with cerebellar hemorrhage: A case report. *No Shinkei Geka* 1986;14:411–416.
- 5 Chaddock WM, Duong DH, Kast JM, Donahue DJ: Pediatric cerebellar hemorrhages. *Childs Nerv Syst* 1995;11:579–583.
- 6 Young RE: Cerebellar astrocytoma presenting as a cerebellar hemorrhage in a child. *Neurology* 1980;30:1020–1021.
- 7 Specht CS, Pinto-Lord C, Smith TW, DeGiro-lami U, Suran E, Marshall PC, Davidson RI: Spontaneous hemorrhage in a mixed glioma of the cerebellum: Case report. *Neurosurgery* 1986;19:278–281.
- 8 Oldberg E: Hemorrhage into gliomas: A review of eight hundred and thirty-two consecutive verified cases of glioma. *Arch Neurol Psychiatry* 1933;30:1061–1073.
- 9 Mandybur TI: Intracranial hemorrhage caused by metastatic tumors. *Neurology* 1977;27:650–655.
- 10 Globus JH, Saperstein M: Massive hemorrhage into brain tumor: Its significant and probable relationship to rapidly fatal termination and antecedent trauma. *JAMA* 1942;120:348–352.
- 11 Mauersberger W, Cuevas-Solorzano JA: Spontaneous intracerebellar hematoma during childhood caused by a spongioblastoma of the IVth ventricle. *Neuropädiatrie* 1977;8(4):443–450.

Copyright: S. Karger AG, Basel 2001. Reproduced with the permission of S. Karger AG, Basel. Further reproduction or distribution (electronic or otherwise) is prohibited without permission from the copyright holder.

Copyright: S. Karger AG, Basel 2001. Reproduced with the permission of S. Karger AG, Basel. Further reproduction or distribution (electronic or otherwise) is prohibited without permission from the copyright holder.