

4. Kilduff TS, Peyron C. The hypocretin/orexin ligand-receptor system: implications for sleep and sleep disorders. *Trends Neurosci* 2000;23:359–365.
5. Gencik M, Dahmen N, Wiczorek S, et al. A prepro-orexin gene polymorphism is associated with narcolepsy. *Neurology* 2001;56:115–117.
6. Kirchgessner AL, Liu M. Orexin synthesis and response in the gut. *Neuron* 1999;24:941–951.
7. Hinze-Selch D, Wetter TC, Zhang Y, et al. In vivo and in vitro immune variables in patients with narcolepsy and HLA-DR2 matched controls. *Neurology* 1998;50:1149–1152.
8. Mignot E, Tafti M, Dement WC, et al. Narcolepsy and immunity. *Adv Neuroimmunol* 1995;5:23–37.
9. Kastin AJ, Akerstrom V. Orexin A but not orexin B rapidly enters brain from blood by simple diffusion. *J Pharmacol Exp Ther* 1999;289:219–223.

CME

Narcolepsy and low CSF orexin (hypocretin) concentration after a diencephalic stroke

Article abstract—Idiopathic narcolepsy usually results from a loss of the hypothalamic neuropeptide orexin (hypocretin), but the cause of secondary narcolepsy resulting from focal brain lesions is unknown. The authors describe a young man who developed narcolepsy after a large hypothalamic stroke. His lesion included much of the hypothalamic region in which orexin is produced, and his CSF concentration of orexin was low. The authors hypothesize that a loss of orexin neurons or their relevant targets may be the specific neuropathology causing this and many other cases of secondary narcolepsy.

NEUROLOGY 2001;56:1751–1753

T.E. Scammell, MD; S. Nishino, MD, PhD; E. Mignot, MD, PhD; and C.B. Saper, MD, PhD

After the outbreak of encephalitis lethargica in 1916, von Economo reported that many of these hypersomnolent patients had inflammatory lesions of the posterior hypothalamus and rostral midbrain¹ (figure, A). He hypothesized that these regions contained neurons essential in the promotion of wakefulness, and he speculated that narcolepsy had its origin “in a yet unknown disease of that region.”

Within the last year, accumulating evidence has demonstrated that narcolepsy may be caused by impaired signaling by the hypothalamic neuropeptide orexin (also known as hypocretin). Narcolepsy is characterized by excessive daytime sleepiness and attacks of cataplexy, a sudden loss of muscle tone. Orexin knockout mice have a narcolepsy-like phenotype,² as do dogs with mutations of the orexin type 2 receptor.³ People with idiopathic narcolepsy rarely have mutations in these genes,⁴ but they usually have reduced orexin in their spinal fluid⁵ and loss of orexin neurons in the hypothalamus.^{4,6} Orexin neurons may promote wakefulness and may suppress REM sleep by exciting monoaminergic neurons in the brainstem and caudal hypothalamus. Lack of

this input may allow REM sleep phenomena such as muscle atonia and hypnagogic hallucinations to intrude into the waking state.

On rare occasions, narcolepsy can occur after injuries to the hypothalamus or rostral brainstem. We recently encountered such a case in which CSF orexin levels confirmed depletion of this cell population.

Case report. We evaluated a 23-year-old man with narcolepsy after a hypothalamic stroke. At age 18, the patient had normal intellectual development but was short (164 cm), with gonadal hypoplasia and delayed puberty. A large craniopharyngioma was identified below his posterior hypothalamus and was surgically removed. He became comatose after surgery because of bilateral infarcts of nearly the entire hypothalamus, most likely caused by vasospasm of the circle of Willis. This lesion included all of the caudal 2/3 of the hypothalamus except for the most lateral component on the right, and also extended into the mediodorsal thalamus bilaterally, the left amygdala, and parts of the basal forebrain and the rostral midbrain (see figure, B and C). His postoperative course was complicated by panhypopituitarism, staphylococcal meningitis, and hydrocephalus, requiring placement of a ventriculo-peritoneal shunt.

When seen by us at age 23, his height had increased to 187 cm, and he weighed 111 kg. His neurologic function had improved so that he could work 3 hours/day in a restaurant. He was moderately inattentive, with poor recent memory, pseudobulbar affect, a partial right third nerve palsy, mild dysarthria, and slow fine finger movements bilaterally. Several times each day, he had episodes of sleepiness, with confusion and worsening of his dysarthria and diplopia; these episodes did not improve with anticonvulsants but often improved with several minutes of sleep.

From the Department of Neurology (Drs. Scammell and Saper), Beth Israel Deaconess Medical Center, Boston, MA; and the Center for Narcolepsy (Drs. Nishino and Mignot), Department of Psychiatry, Stanford University School of Medicine, CA.

Supported by National Institutes of Health grants MH01507 and HL60292. Received December 15, 2000. Accepted in final form March 2, 2001.

Address correspondence and reprint requests to Dr. T.E. Scammell, Department of Neurology, Beth Israel Deaconess Medical Center, 77 Ave. Louis Pasteur, Boston, MA 02115; e-mail: tscammel@caregroup.harvard.edu

See also pages 1616, 1749, and 1775

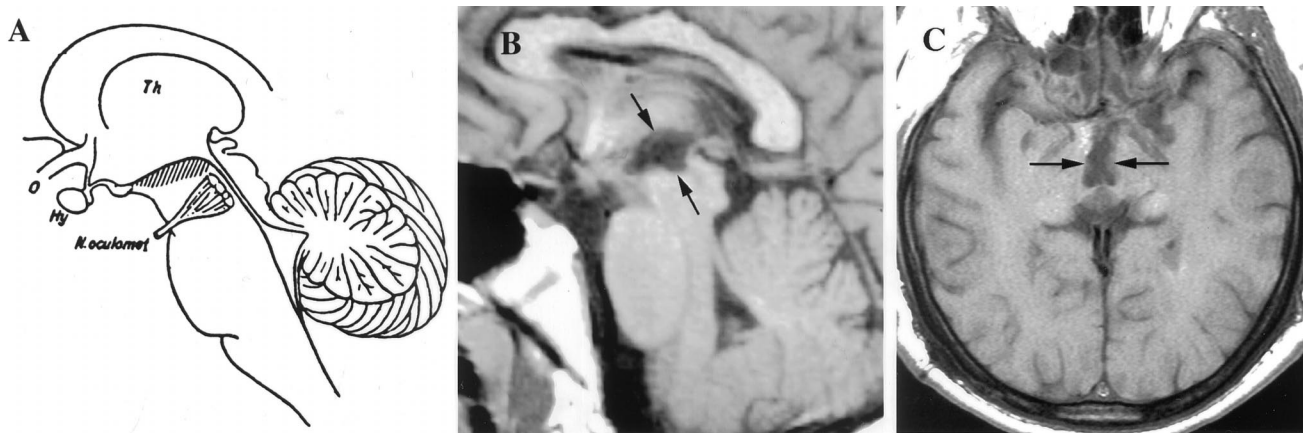


Figure. (A) Diagram of a sagittal section of the brain adapted from von Economo¹; the hatching highlights those regions in which inflammatory lesions produced hypersomnia. (B, C) T1-weighted sagittal and horizontal MR images demonstrating ex vacuo changes (between arrows) in the posterior hypothalamus and rostral midbrain of the patient with secondary narcolepsy. Th = thalamus; o = optic nerve; Hy = hypothalamus; N. oculomot = oculomotor nerve.

He slept 10 hours each night, was difficult to rouse each morning, and would take a 1- to 2-hour nap each afternoon. He often dozed off while watching television or while riding in the car. He had occasional episodes of weakness when he laughed, sometimes falling to the ground without injury, but often these episodes would just include weakness of the neck or right arm. He had experienced two episodes of sleep paralysis, and he often had vivid visual hallucinations when drowsy. There was no family history of narcolepsy or excessive sleepiness.

Routine EEG and several days of video/EEG monitoring demonstrated diffuse cortical slowing but no epileptiform activity. An overnight polysomnogram showed a sleep latency of only 1 minute, REM sleep latency of 1.5 minutes, and 15 spontaneous awakenings, without significant sleep apnea. A multiple sleep latency test showed a latency to stage 1 sleep of less than 0.5 minutes on average across the day, with REM sleep occurring within 3.5 minutes in all four naps. Unlike most individuals with idiopathic narcolepsy, this patient tested negative for HLA-DQB1*0602. The sleep studies were performed 3 weeks after discontinuing stimulants, and lumbar puncture was performed at 11 AM the following day. CSF was immediately frozen at -80°C , and orexin-A concentration was measured by S.N. using a radioimmunoassay kit. CSF protein was mildly elevated, and the concentration of orexin was low (167 pg/mL). In a separate analysis of CSF collected during the daytime, we found that the mean orexin level was 280 ± 33 pg/mL (\pm SD) in 15 normal subjects and 260 ± 37 in 19 patients with neurologic diseases other than narcolepsy.⁷

Discussion. Removal of a craniopharyngioma in this patient was followed by extensive hypothalamic injury, hypersomnia, and narcolepsy. Damage to ascending arousal pathways that traverse the hypothalamus and thalamus is the most likely cause of his hypersomnia. His short latencies to REM sleep, cataplexy, and hypnagogic hallucinations indicate that he has narcolepsy, and this is most likely a result of his hypothalamic injury.

Impaired orexin signaling may be the specific cause of our patient's secondary narcolepsy. Orexin-

producing neurons are found only in the lateral hypothalamus and adjacent perifornical region, and these areas were probably damaged by this patient's stroke. Orexin neurons project heavily to brain regions hypothesized to play critical roles in the control of sleep and wakefulness including the locus coeruleus, raphe nuclei, tuberomammillary nucleus, and cholinergic neurons in the basal forebrain and pons.^{2,8} Orexin increases the firing rates of postsynaptic neurons, and increased activity in aminergic neurons should promote wakefulness and should inhibit REM sleep. Conversely, a lack of orexin as occurs in orexin knockout mice and in humans with idiopathic narcolepsy is associated with poor maintenance of wakefulness and intrusions of REM sleep or REM-like phenomena. Our patient's low CSF concentration of orexin is consistent with his narcolepsy resulting from a loss of orexin neurons or their projections. However, orexin levels are even lower in most patients with idiopathic narcolepsy, and infarction of orexin-responsive, state-regulatory neurons may have contributed to our patient's narcolepsy.

Loss of orexin neurons or their relevant targets may be the specific neuropathology in most cases of secondary narcolepsy. Hypothalamic lesions are the most common cause of secondary narcolepsy (for review, see reference 9), occurring with tumors, surgical injury, MS, sarcoid, encephalitis, and stroke. A rare, familial form of autosomal dominant cerebellar ataxia with deafness and narcolepsy was reported to demonstrate dilation of the third ventricle, presumably from hypothalamic atrophy.¹⁰ Many of these hypothalamic lesions may directly injure the orexin neurons or their projections. Less commonly, narcolepsy occurs with lesions of the midbrain and pontine tegmentum. Orexin neurons heavily innervate key state-regulatory regions in the rostral brainstem,^{2,8} and these cases may involve injury to these pathways or their targets. Very rare brainstem lesions may produce fragments of narcolepsy such as iso-

lated cataplexy after disruption of orexin-responsive brainstem regions that regulate muscle tone.

Impaired orexin signaling may underlie most cases of narcolepsy. Lack of orexin peptide appears to cause most cases of idiopathic narcolepsy, possibly because of an autoimmune attack on orexin neurons. Measurement of CSF orexin levels and detailed anatomic studies may reveal that most cases of secondary narcolepsy also result from a loss of orexin neurons or their targets.

Acknowledgment

The authors thank G. Bertics, MD, for the care of this patient.

References

1. von Economo C. Sleep as a problem of localization. *J Nerv Ment Dis* 1930;71:249–259.
2. Chemelli RM, Willie JT, Sinton CM, et al. Narcolepsy in orexin knockout mice: molecular genetics of sleep regulation. *Cell* 1999;98:437–451.
3. Lin L, Faraco J, Li R, et al. The sleep disorder canine narcolepsy is caused by a mutation in the hypocretin (orexin) receptor 2 gene. *Cell* 1999;98:365–376.
4. Peyron C, Faraco J, Rogers W, et al. A mutation in a case of early onset narcolepsy and a generalized absence of hypocretin peptides in human narcoleptic brains. *Nat Med* 2000;6:991–997.
5. Nishino S, Ripley B, Overeem S, Lammers GJ, Mignot E. Hypocretin (orexin) deficiency in human narcolepsy. *Lancet* 2000;355:39–40.
6. Thannickal T, Moore RY, Nienhuis R, et al. Reduced number of hypocretin neurons in human narcolepsy. *Neuron* 2000;27:469–474.
7. Nishino S, Ripley B, Overeem S, et al. Diagnostic value of low CSF hypocretin/orexin levels in human narcolepsy. *Sleep* 2001;24(suppl):A95–A96.
8. Peyron C, Tighe DK, van den Pol AN, et al. Neurons containing hypocretin (orexin) project to multiple neuronal systems. *J Neurosci* 1998;18:9996–10015.
9. Autret A, Lucas B, Henry-Lebras F, de Toffol B. Symptomatic narcolepsies. *Sleep* 1994;17(suppl):S21–S24.
10. Melberg A, Dahl N, Hetta J, et al. Neuroimaging study in autosomal dominant cerebellar ataxia, deafness, and narcolepsy. *Neurology* 1999;53:2190–2192.

Cytoplasmic and nuclear polyglutamine aggregates in SCA6 Purkinje cells

Article abstract—Aggregations of the alpha1A-calcium channel protein have been previously demonstrated in spinocerebellar ataxia type 6 (SCA6). Here the authors show that small aggregates, labeled by a monoclonal antibody 1C2 that preferentially detects expanded polyglutamine larger than that in SCA6 mutation, are present mainly in the cytoplasm but also in the nucleus of Purkinje cells. Although the length of expansion is small in SCA6, the current finding might indicate that SCA6 conforms to the pathogenic mechanism(s) in other polyglutamine diseases.

NEUROLOGY 2001;56:1753–1756

K. Ishikawa, MD, PhD; K. Owada, MD, PhD; K. Ishida, MD, PhD; H. Fujigasaki, MD, PhD; M. Shun Li, MD; T. Tsunemi, MD; N. Ohkoshi, MD, PhD; S. Toru, MD, PhD; T. Mizutani, MD, PhD; M. Hayashi, MD, PhD; N. Arai, MD, PhD; K. Hasegawa, MD, PhD; T. Kawanami, MD, PhD; T. Kato, MD, PhD; T. Makifuchi, MD, PhD; S. Shoji, MD, PhD; T. Tanabe, PhD; and H. Mizusawa, MD, PhD

Spinocerebellar ataxia type 6 (SCA6) is a dominantly inherited ataxia clinically characterized by mostly

pure, cerebellar symptoms with relatively late age at onset.^{1,2} The Purkinje cell is predominantly affected more than other neurons, such as inferior olivary neurons or cerebellar granule cells.³ The causative mutation is the expansion of trinucleotide (CAG) repeat coding polyglutamine in the 3' region of the alpha1A (P/Q-type)-voltage-dependent calcium channel gene.¹ Importantly, the size of expansion in SCA6 is so small that it falls within the range of normal repeat in other CAG repeat/polyglutamine diseases.

We have shown functional alteration of P/Q-type calcium channel in cultured cells transfected with

From the Departments of Neurology (Drs. Ishikawa, Owada, Ishida, Fujigasaki, Li, Tsunemi, Toru, and Mizusawa) and Pharmacology (Dr. Tanabe), Graduate School of Medicine, Tokyo Medical and Dental University, Bunkyo-ku; CREST (Drs. Ishikawa, Toru, Tanabe, and Mizusawa), Japan Science and Technology Corporation, Wako, Saitama; Department of Neurology (Dr. Ishida), Tamagawa Hospital, Setagaya-ku, Tokyo; Departments of Neurology (Dr. Fujigasaki) and Pathology (Dr. Mizutani), Tokyo Metropolitan Neurological Hospital, Fuchu; Department of Neurology (Drs. Ohkoshi and Shoji), Institute of Clinical Medicine, University of Tsukuba, Ibaraki; Department of Neuropathology (Drs. Hayashi and Arai), Tokyo Metropolitan Institute of Neurological Sciences, Fuchu; Department of Neurology (Dr. Hasegawa), Kitasato University, Sagami-hara, Kanagawa; Third Department of Internal Medicine (Drs. Kawanami and Kato), Yamagata University School of Medicine; and the Department of Neuropathology (Dr. Makifuchi), National Saigata Hospital, Niigata, Japan.

Supported by grants from the Research Committee for Ataxic Diseases (H.M.) and Brain Science Research (T.T., H.M.), the Ministry of Health and Welfare, Japan; from Grant-in-Aid for Scientific Research on Priority Areas (C)—Advanced Brain Science Project, the Ministry of Education, Culture, Sports, Science, and Technology, Japan (H.M., K.I.); from the Kato Memo-

rial Foundation for Intractable Diseases (H.M.); and from the Nagao Takeshi Foundation for Intractable Diseases (K.I.).

Received October 18, 2000. Accepted in final form February 24, 2001.

Address correspondence and reprint requests to Dr. Hidehiro Mizusawa, Professor and Chairman, Department of Neurology, Graduate School of Medicine, Tokyo Medical and Dental University, Yushima 1-chome 5-45, Bunkyo-ku 113-8519, Tokyo, Japan; e-mail: h-mizusawa.nuro@tmd.ac.jp

Neurology[®]

Narcolepsy and low CSF orexin (hypocretin) concentration after a diencephalic stroke

T.E. Scammell, S. Nishino, E. Mignot, et al.

Neurology 2001;56;1751-1753

DOI 10.1212/WNL.56.12.1751

This information is current as of June 26, 2001

Updated Information & Services	including high resolution figures, can be found at: http://www.neurology.org/content/56/12/1751.full.html
References	This article cites 10 articles, 2 of which you can access for free at: http://www.neurology.org/content/56/12/1751.full.html##ref-list-1
Citations	This article has been cited by 7 HighWire-hosted articles: http://www.neurology.org/content/56/12/1751.full.html##otherarticles
Subspecialty Collections	This article, along with others on similar topics, appears in the following collection(s): Infarction http://www.neurology.org/cgi/collection/infarction
Permissions & Licensing	Information about reproducing this article in parts (figures, tables) or in its entirety can be found online at: http://www.neurology.org/misc/about.xhtml#permissions
Reprints	Information about ordering reprints can be found online: http://www.neurology.org/misc/addir.xhtml#reprintsus

Neurology® is the official journal of the American Academy of Neurology. Published continuously since 1951, it is now a weekly with 48 issues per year. Copyright . All rights reserved. Print ISSN: 0028-3878. Online ISSN: 1526-632X.

