

REFERENCES

1. Kandler R, Smith C, Broome J, Aelwyn G, Davies-Jones B. Gliomatosis cerebri: a clinical, radiological and pathological report of four cases. *BJN* 1991; 5: 187-193.
2. Nevin S. Gliomatosis cerebri. *Brain* 1938; 61: 170-191.
3. Landau M. Das diffuse Gliome des Gehirns. *Frankl Path* 1910; 5: 469.
4. Scharenberg K, Jones E. Diffuse glioma of the brain in von Recklinghausen's Disease. A study with silver carbonate. *Neurology* 1956; 6: 269-274.
5. Artigas J, Cervos-Navarro J, Iglesias J, Ebhardt G. Gliomatosis cerebri: clinical and histological findings. *Clinical Neuropathology* 1985; 4(4): 135-148.
6. Ross I, Robitaille Y, Villemure J, Tampieri D. Diagnosis and management of gliomatosis cerebri: recent trends. *Surg Neurol* 1991; 36: 431-440.
7. Hecht B, Turc-Carel C, Chatel M et al. Chromosomes in gliomatosis cerebri. *Genes, Chromosomes and Cancer* 1995; 14(2): 149-153.
8. Couch J, Weiss S. Gliomatosis cerebri. *Neurology* 1974; 24: 504-511.
9. Kim D, Yang H, Park I et al. Gliomatosis cerebri: clinical features, treatment and prognosis. *Acta Neurochir* 1998; 140: 755-762.
10. Troost D, Kuiper H, Valk J, Fleury P. Gliomatosis cerebri, report of a clinically diagnosed and histologically confirmed case. *Clinical Neurology and Neurosurgery* 1987; 89(1): 43-47.
11. Spagnoli M, Grossman R, Packer R et al. Magnetic resonance imaging determination of gliomatosis cerebri. *Neuroradiology* 1987; 29: 15-18.
12. Carpio-O'Donovan R, Korah I, Salazar A, Melancon D. Gliomatosis cerebri. *Radiology* 1996; 198: 831-835.
13. Shin Y, Cnang K, Han M et al. Gliomatosis cerebri: comparison of MR and CT features. *Am J Roentgenology* 1993; 161(4): 859-862.
14. Felsberg G, Silver S, Brown M, Tien R. Radiological-pathologic correlation of gliomatosis cerebri. *AJNR* 1994; 15(9): 1745-1753.
15. Cozad S, Townsend P, Morantz R, Jenny A, Kepes J, Smalley S. Gliomatosis cerebri: results of radiotherapy. *Cancer* 1996; 78(8): 1789-1793.

Multiple cystic brain lesions in a patient with pilocytic astrocytoma

S. Senaratna¹ MBMS, A. Hanieh¹ FRACS, J. Manson² FRACP, I. Toogood³ FRACP

Department of ¹Neurosurgery, ²Neurology and ³Oncology, Women's and Children's Hospital, North Adelaide, 5006, S.A., Australia

Summary Pilocytic astrocytomas are usually present as solitary posterior cranial fossa tumours. An unusual case of pilocytic astrocytoma in a 3 year and 8 month old boy is presented. The patient presented over the course of 10 months with intermittent headaches, vomiting, gait ataxia and drowsiness. After extensive investigations magnetic resonance imaging (MRI) revealed widespread lesions throughout the central nervous system, including multiple cystic cerebral grey matter lesions. A brain biopsy was performed and pathological studies revealed pilocytic astrocytoma. The literature pertaining to neuraxis dissemination of pilocytic astrocytomas in the paediatric population is reviewed. There are only a very limited number of reports of pilocytic astrocytoma causing multiple brain lesions, with no publications of multiple cystic brain lesions. We believe this to be a unique case of pilocytic astrocytoma presenting with widespread cystic lesions throughout the brain. © 2001 Harcourt Publishers Ltd

Journal of Clinical Neuroscience (2001) 8(4), 363-366 © 2001 Harcourt Publishers Ltd
DOI: 10.1054/jocn.2000.0802, available online at <http://www.idealibrary.com> on IDEAL®

Keywords: astrocytoma, glioma, meninges, spinal cord, cyst

Received 8 December 1999

Accepted 8 May 2000

Correspondence to: Sanjeeva Senaratna, Unit 9/123 North East Road, Collinswood 5081, S.A., Australia. Tel.: +61 08 82045511 (B.H.); +61 08 83422862 (A.H.); Fax: +61 08 82045450

INTRODUCTION

Pilocytic astrocytoma is one of the most common paediatric central nervous system (CNS) tumours. It is most frequently found as a solitary mass in the cerebellum. This report concerns a case of a neoplasm which presented over a prolonged period with both atypical clinical and radiological features that eluded diagnosis until a biopsy was performed.

CASE REPORT

The patient was a 3 year and 8 month old boy weighing 15 kilograms. There was a past medical history of otitis media and prenatal hydronephrosis. His symptoms were intermittent vomiting, headaches, unsteadiness of gait and drowsiness occurring up to few times a week over a period of 10 months. At his earlier presentations there were no definite neurological signs apart from the unsteadiness of gait. During the 10 month period he had presented four times to hospital. At his first presentation communicating hydrocephalus was diagnosed by computed tomography (CT) and magnetic resonance imaging (MRI). MRI had also shown a variant of Dandy-Walker malformation and diffuse high signal white matter changes throughout the periventricular area and cerebellum on T₂-weighted images. A ventriculoperitoneal (VP) shunt was inserted. The cerebrospinal fluid (CSF) was noticed intraoperatively

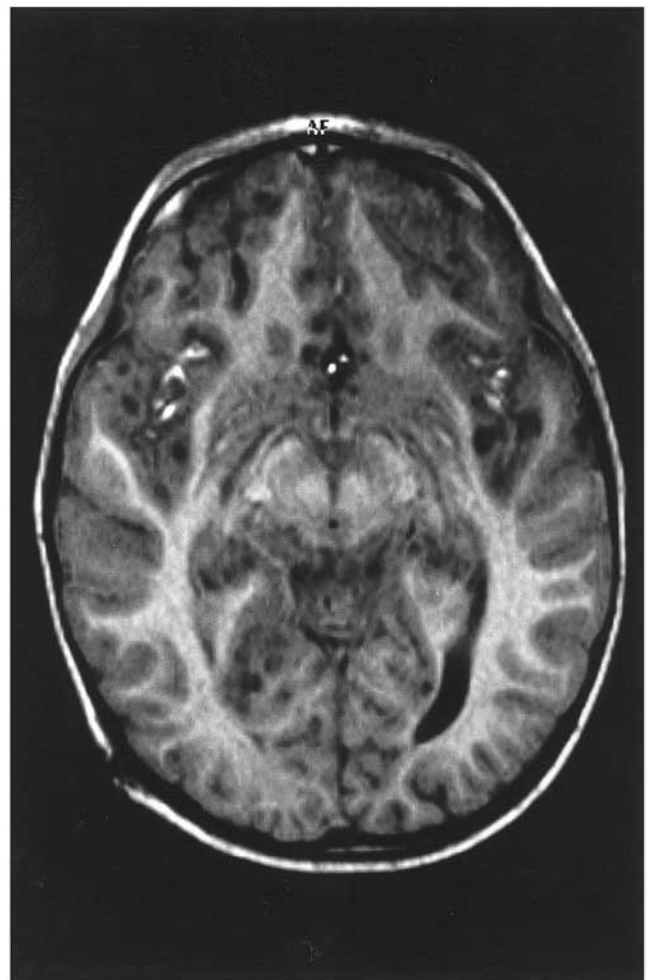


Fig. 1 There are multiple cystic lesions in the grey matter near the grey-white junction on this axial T₁-weighted magnetic resonance image.

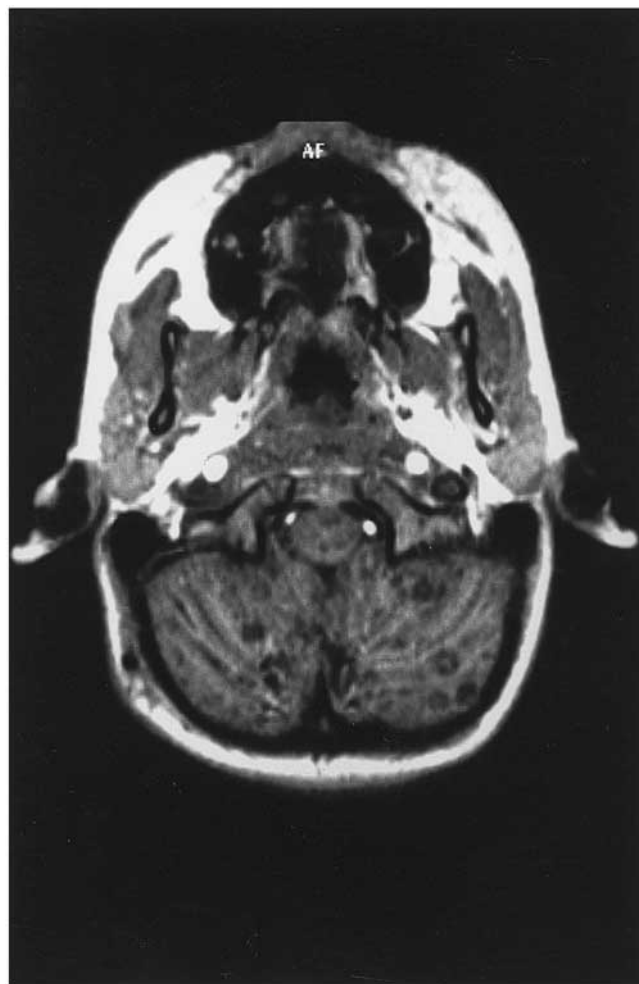


Fig. 2 Axial T₁-weighted magnetic resonance image shows multiple cystic lesions in the cerebellum and medulla.

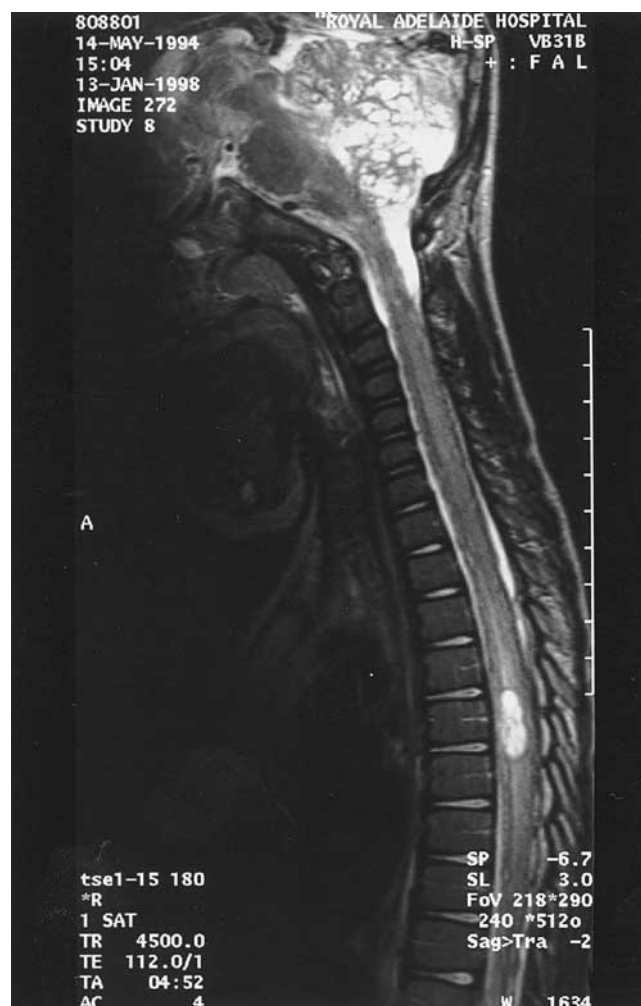

Fig. 3 Sagittal T₂-weighted magnetic resonance image shows prominent cystic cerebellar lesions with high signal, and high signal of the presumed primary lesion in the thoracic spinal cord. There is also marked thickening of the meninges with low signal around the spinal cord.

to be turbid and under very high pressure. The CSF protein concentration was raised at 1.2 gram per litre (normal ventricular value ≤ 0.15), red blood cell count 1115 per microlitre (normal range = 0–5), polymorphonuclear leukocyte count 20 per microlitre (normal count = 0).^{1,2} There were no bacteria nor acid-fast bacilli seen on microscopy. Latex agglutination test was negative for *Cryptococcus neoformans* antigen. On culture there were no growth of bacteria, acid-fast bacilli nor cryptococci. He was readmitted to hospital with a blocked VP shunt, which was subsequently revised; this was complicated by infection of the shunt and peritonitis. After the infections had been treated, a ventriculoatrial shunt was placed. At his latest admission to hospital he presented with drowsiness, dry retching, slurred speech, facial asymmetry and unsteadiness of gait. He was afebrile and had a Glasgow Coma Scale of 11 (Eyes 4, Voice 2, Motor 5). There was a transient right sided upper motor neuron facial palsy and partial right sided abducens nerve palsy. Limb examination revealed slight hypertonia, exaggerated lower limb reflexes and upgoing plantar response. Ventriculoatrial shunt CSF microbiologic examination was negative. The next day he had a respiratory arrest with dilated pupils. He was intubated and ventilated, and given mannitol. A CT scan of the brain revealed cerebral oedema with obliteration of sulci and basal cisterns. The impression was that of encephalitis or encephalopathy. He was then taken to the intensive care unit where he made a prompt recovery. Subsequently,

an electroencephalogram (EEG) revealed a moderate degree of generalised encephalopathy without any periodic complexes, and a radioisotope CSF shunt function study was normal. However, it was MRI of head and spine that revealed striking features. There were multiple cystic cerebral lesions mainly involving the grey matter near the grey-white junction and cerebellar cortex (Figs 1–3). There was diffuse and extensive meningeal enhancement and thickening of meninges surrounding the brain, spinal cord and nerve roots (Figs 4–6). Around the nerve roots there had a nodular appearance and there was also a markedly contrast enhancing large solid lesion in the spinal cord at the third thoracic vertebral level (Fig. 3); this was high signal on T₂-weighted imaging. These MRI features were similar to cysticercosis, cryptococcal meningitis, meningeal carcinomatosis and disseminated melanoma. Extensive investigations for infective and neurodegenerative pathologies were negative. These included serum and CSF *Taenia solium* cysticerci antibodies and thigh X-ray to exclude calcified *Taenia solium* cysts. CSF cytologic examination was also negative. Every sample of CSF taken was from the ventricles.

The provisional diagnosis was neurocysticercosis, despite the negative blood and CSF tests. In view of the uncertain diagnosis after extensive investigations, and due to the progressive deterioration

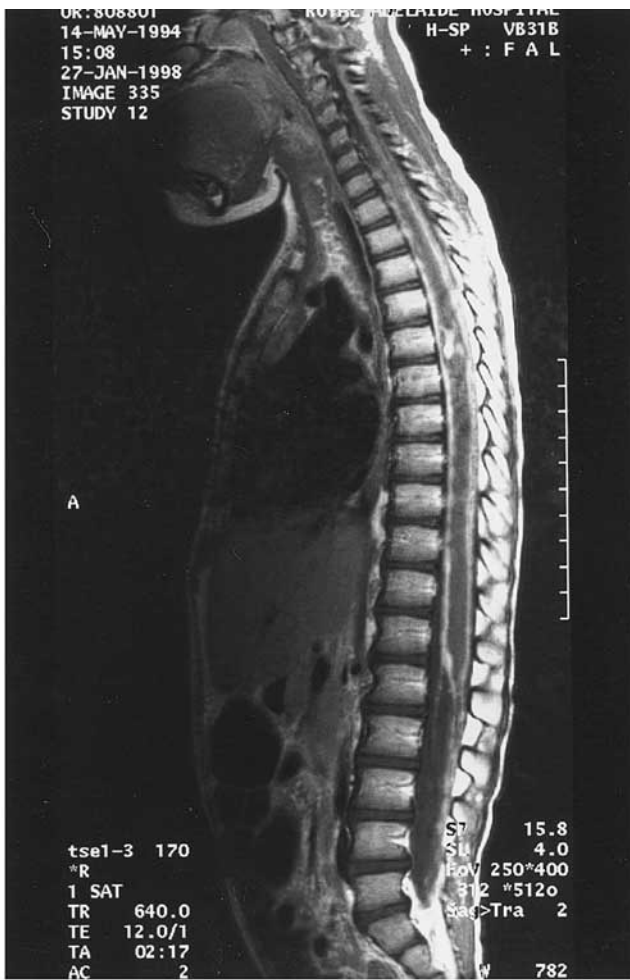


Fig. 4 This post-contrast T₁-weighted sagittal MRI scan demonstrates enhancement of the spinal tumour, and enhancement of the thickened meninges around the spinal cord and cauda equina nerve roots.

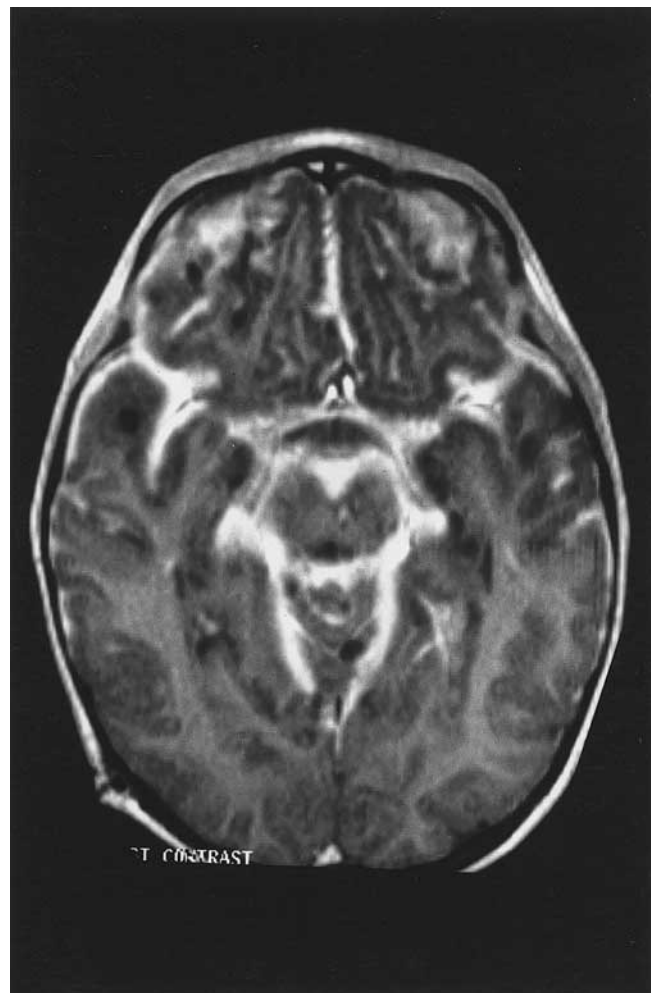


Fig. 5 Gadolinium enhanced MRI scan shows diffuse leptomeningeal enhancement including the perimesencephalic cisterns and tentorium, but without any ring enhancement of the cysts.

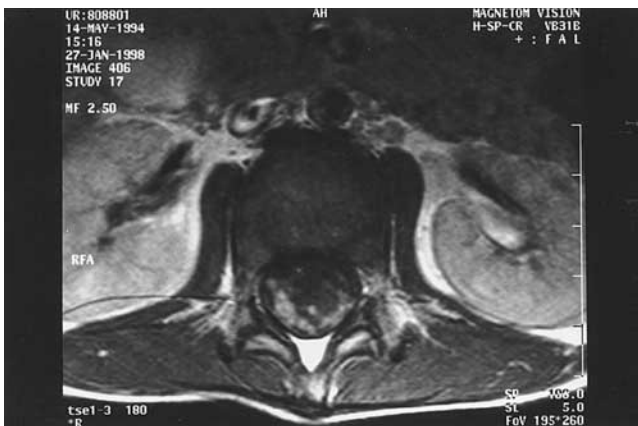


Fig. 6 Post-contrast T₁-weighted axial magnetic resonance image of the spine showing enhancement of cauda equina nerve roots.

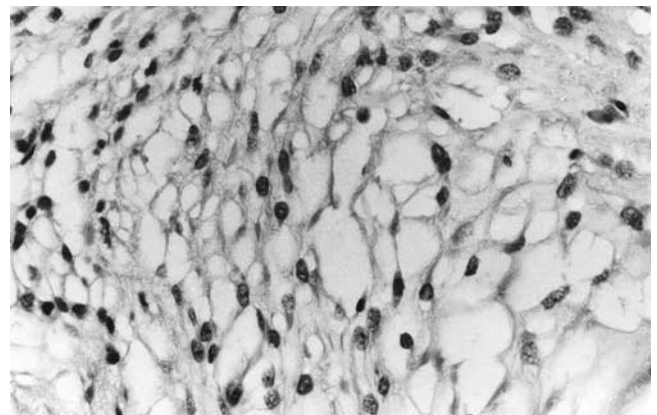


Fig. 7 Photomicrograph showing the histopathological findings of the cerebellar biopsy. The stain was haematoxylin and eosin, and the magnification is 400 times.

in his clinical condition, he underwent a posterior fossa craniotomy and biopsy. It was noted that the meninges were unusually thickened (about 3–4 mm at maximal thickness). The dura mater was extremely vascular on the deep surface. Biopsies of the cerebellar vermis and the right cerebellum were taken. Specimens were sent for microbiologic and histopathologic examination.

Microbiologic examination revealed a growth of *Aspergillus niger*, but this was thought to be a contaminant. Histopathologic examination revealed leptomeningeal and superficial cerebellar infiltration by a cytologically bland glial fibrillary acidic protein (GFAP) positive tumour with desmoplasia in the meninges. Focally, there was a microcystic component and the appearances

were considered to be those of a low grade pilocytic astrocytoma. (Fig. 7). He proceeded to have chemotherapy which included four cycles of vincristine and high dose cyclophosphamide given monthly along with granulocyte colony stimulating factor support. The vincristine was given in a dose of 1.5 mg per metre squared body surface area on days 1 and 15, and the cyclophosphamide in a dose of 60 mg/kg/day on the first and second days of each cycle. There was no convincing evidence of a response to chemotherapy. In the months following there was progressive clinical and radiological deterioration.

DISCUSSION

Neoplasms may present in unusual ways, occasionally mimicking a non-neoplastic disease, causing extensive investigations to be performed. Difficulties with diagnosis arose in our patient because the clinical and radiological features were not typical of pilocytic astrocytoma. The clinical presentation was unusual because the patient was relatively young, the symptoms were intermittent with complete recovery between attacks, and the condition extended over a long period of 10 months. The radiological findings were unusual because the initial CT and MRI of the brain did not show any evidence of a tumour. Subsequently, when MRI did show a definite abnormality, the lesions were similar to features seen in cysticercosis, cryptococcosis, etc. Also, the CSF that was analysed was obtained from the ventricles and not by lumbar puncture; this may explain the negative yield of the CSF cytologic examination as there was no neoplastic involvement of the ventricles on MRI. The most striking features about this case were the radiological findings of numerous cystic brain lesions and the thoracic spinal cord mass, which was probably the primary neoplasm. Usually pilocytic astrocytoma presents as a solitary mass in the cerebellum or optic nerves and chiasma. The explanation for the cystic lesions in the cerebral grey matter and the cerebellum may be dissemination of the neoplasm via the CSF and the Virchow-Robin perivascular spaces, similar to the mode of spread in CNS cryptococcosis.³

A very limited number of studies have reported neuraxis dissemination of pilocytic astrocytoma. Mamelak et al. showed that in their study of 90 adult and paediatric patients with either primary or recurrent pilocytic astrocytoma, 11 (12%) developed multicentric neuraxis spread.⁴ Multicentric spread was defined as either diffuse subependymal or leptomeningeal dissemination well beyond the borders of the primary tumour, or discrete nodular disease separate from the primary tumour. Nine of the 11 patients

were children, and six of these children had disease spread to regions other than the leptomeninges or ependyma. There have been two other reports of paediatric pilocytic astrocytoma spreading to regions of the CNS other than the leptomeninges and ependyma.^{5,6} Other studies, however, did not report on discrete nodular disease. Three studies done within the past few years observed neuraxis dissemination of low grade astrocytomas as a whole.^{7,8,9} These studies revealed low grade astrocytomas, including pilocytic astrocytomas, which had metastasised to the leptomeninges and ependyma at a rate of 4–5 %. In all these reports there was no case of spinal cord pilocytic astrocytoma which had metastasised.

It appears that neuraxis dissemination of pilocytic astrocytoma producing discrete nodular disease was rare. When dissemination was present it preferentially was to the leptomeninges and ependyma. Our patient had leptomeningeal dissemination, but interestingly no obvious primary parenchymal neoplasm in the brain, rendering the spinal cord mass the probable primary lesion. Apart from this there were no other discrete nodular lesions. The unusual multiple lesions that were present in the brain were all small and cystic.

In summary we believe this to be a unique case of paediatric pilocytic astrocytoma with unusual clinical presentation and very unusual MRI features of a solitary thoracic spinal cord mass and multiple cystic brain lesions.

REFERENCES

1. Forfar JO, Arneil GC. *Textbook of Paediatrics*, 3rd ed. Edinburgh: Churchill Livingstone, 1984: 1985–1987.
2. Vaughan VC III, McKay RJ Jr, Behrman RE. *Nelson Textbook Paediatrics*, 11th ed. Philadelphia: W.B. Saunders Company, 1979: 2088–2089.
3. Rubin E, Farber JL. *Pathology*. Philadelphia: J.B. Lippincott Company, 1988: 426, 427, 1445.
4. Mamelak AN, Prados MD, Obana WG, Cogen PH, Edwards MSB. Treatment options and prognosis for multicentric juvenile pilocytic astrocytoma. *J Neurosurg* 1994; 81: 24–30.
5. Kocks W, Kalff R, Reinhardt V, Grote W, Hilke J. Spinal metastasis of pilocytic astrocytoma of the chiasma opticum. *Childs Nerv Syst* 1989; 5: 118–120.
6. Obana WG, Cogen PH, Davis RL, Edwards MSB. Metastatic juvenile pilocytic astrocytoma. *J Neurosurg* 1991; 75: 972–975.
7. Civitello LA, Packer RJ, Rorke LB, Siegal K, Sutton LN, Schut L. Leptomeningeal dissemination of low grade gliomas in childhood. *Neurology* 1988; 38: 562–566.
8. Gajjar A, Bhargava R, Jenkins JJ et al. Low-grade astrocytoma with neuraxis dissemination at diagnosis. *J Neurosurg* 1995; 83: 67–71.
9. Pollack IF, Hurtt M, Pang D, Albright AL. Dissemination of low-grade intracranial astrocytomas in children. *Cancer* 1994; 73: 2869–2878.