

# Multiple Intracranial Aneurysms as Delayed Complications of an Atrial Myxoma: Case Report

Walter C. Jean, M.D., Sabrina M. Walski-Easton, M.D.,  
Eric S. Nussbaum, M.D.

Department of Neurosurgery, University of Minnesota, Minneapolis, Minnesota

**OBJECTIVE AND IMPORTANCE:** Atrial myxomas are rare cardiac tumors that may cause neurological complications; however, delayed neurological events after total tumor resection are rare. In this report, we present a patient who developed transient cerebral ischemic attacks and was found to have multiple intracranial aneurysms 5 years after successful resection of her atrial myxoma. At the time of myxoma resection, there were no neurological symptoms; at the time of presentation with transient ischemic attacks, there was no evidence of atrial recurrence.

**CLINICAL PRESENTATION:** A 32-year-old woman presented with five episodes of right arm and face paresthesia, each lasting 15 to 20 minutes, 5 years after successful resection of her atrial myxoma. Clopidogrel bisulfate therapy was initiated, with resolution of her symptoms. Angiography revealed multiple, peripherally located, fusiform cerebral aneurysms.

**INTERVENTION:** A left frontal craniotomy for resection and biopsy of one of the aneurysms was performed, to establish the diagnosis. Pathological analysis of the biopsied aneurysm provided evidence of direct atrial myxoma invasion and occlusion of the cerebral blood vessel.

**CONCLUSION:** Neurological symptoms may accompany or lead to the diagnosis of atrial myxoma. Rarely, as in this case, myxomatous aneurysms may develop years after definitive treatment of the primary tumor. Patients who have undergone successful resection of a left atrial myxoma may be at risk for delayed cerebral ischemia associated with aneurysm development, and this phenomenon must be considered for patients with neurological symptoms who present even years after myxoma removal. The natural history, pathophysiological features, and treatment dilemma of these aneurysms are discussed. (Neurosurgery 49:200–203, 2001)

**Key words:** Atrial myxoma, Embolism, Multiple fusiform aneurysms, Transient ischemic attacks

Atrial myxomas are rare tumors. They reportedly occur in less than 0.05% of the population, but they constitute approximately 50% of primary cardiac neoplasms (10, 14, 21, 22). These tumors present with systemic embolization in up to 45% of cases (9, 14, 17, 22, 23), with the cerebral circulation being involved in one-half of these instances

(9, 10, 14, 23). Cerebral ischemia resulting from direct tumor embolization is the most common neurological presentation (1, 3, 4, 7, 11, 20). Other rare neurological manifestations include parenchymal brain metastasis (15, 19), intracerebral hemorrhage (2, 7, 13, 23), and oncotic aneurysm formation (2, 3, 5–8, 12, 14, 16, 18, 21, 22).

With rare exceptions, neurological symptoms related to atrial myxomas occur before or at the time of primary tumor diagnosis. Reports of delayed neurological symptoms after surgical removal of the myxoma are sparse (7, 9, 14, 18, 20). We describe a patient who presented with transient cerebral ischemic symptoms 5 years after complete resection of a left atrial myxoma. A cerebral angiogram revealed numerous fusiform intracranial aneurysms. The pathophysiological features of these aneurysms and the symptoms of the patient are discussed, and the pertinent literature is reviewed.

## CASE REPORT

A 32-year-old, right-handed woman was transferred to our institution after experiencing five episodes of paresthesia involving the right arm and face. Each event lasted 15 to 20 minutes and resolved spontaneously, without residual symptoms. The neurological examination revealed no persisting deficits, and a lumbar puncture disclosed no abnormalities. The clinical history of the patient was significant for a left atrial myxoma, which had been discovered 5 years earlier because of tumor embolization to the extremities and coronary vessels. At that time, the patient had undergone an uneventful thoracotomy, with resection of the myxoma. Pathological analysis of the tumor revealed a well-circumscribed mass measuring 3.5 × 3.2 × 3 cm, with loose stroma and scattered spindle-shaped cells. The patient had been without symptoms since the time of surgery.

Ultrasonographic examination of the carotid arteries and magnetic resonance imaging of the brain were performed, and findings were within normal limits. Electroencephalography demonstrated left temporal slowing, without epileptiform activity. Transthoracic echocardiography disclosed no evidence of a recurrent atrial myxoma, but four-vessel cerebral angiography revealed multiple peripheral, fusiform, intracranial aneurysms (Fig. 1).

The patient continued to experience stereotypical episodes of right-sided paresthesia. These symptoms ceased with the institution of clopidogrel bisulfate therapy at 75 mg/d. To establish whether there were active tumor cells within the aneurysm walls, the patient underwent a left frontal craniotomy for resection of one of the aneurysms located at the frontal pole (Fig. 1). During surgery, the aneurysm was noted to be situated at a branch point in the vessel, and one of the two efferent arteries was observed to be thrombosed. The aneurysm was trapped between clips and resected. Histopathological analysis revealed multifocal expansion of the vascular intima by the myxoid tumor, which was characterized by a mucoid matrix with stellate cells (Fig. 2). Disruption of the internal elastic lamina was also observed.

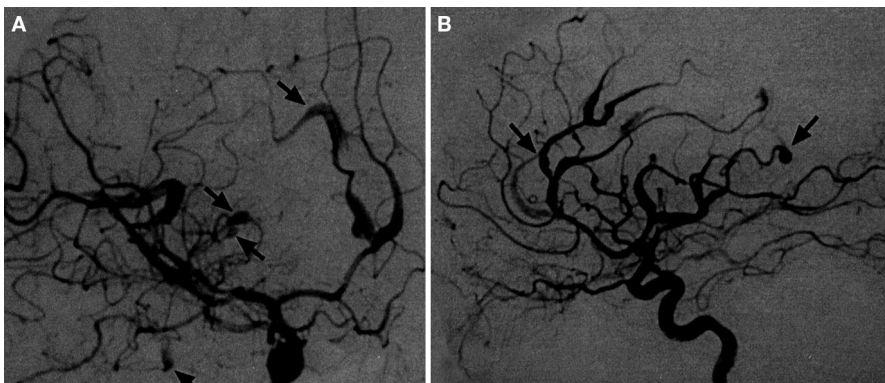
The patient tolerated surgery well and continued to receive clopidogrel bisulfate, without additional symptoms. Follow-up cerebral angiography performed 4 months after her neurological presentation revealed no changes in the remainder of her aneurysms.

## DISCUSSION

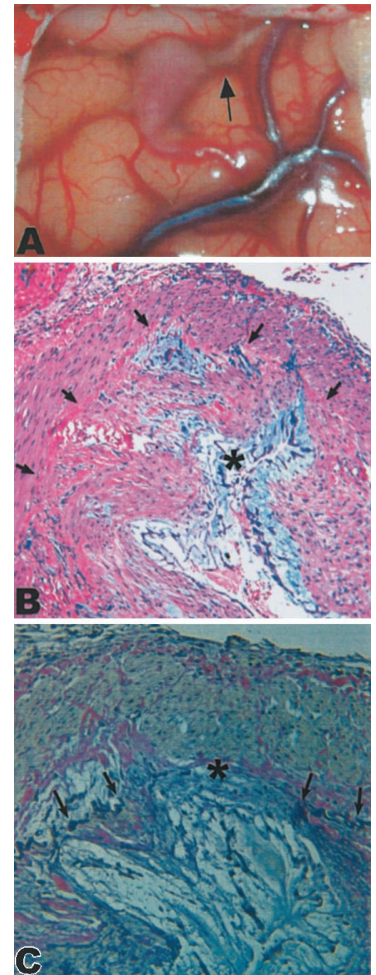
Although neurological symptoms, especially transient ischemia, may accompany or actually result in the diagnosis of left atrial myxomas, delayed neurological complications years after complete tumor excision are rare. Knepper et al. (11) monitored eight patients for up to 8 years after total excision of their atrial myxomas, and none of the pa-

tients experienced subsequent neurological events. Similarly, of 35 patients with atrial myxomas who were monitored at the Mayo Clinic, only 1 experienced cerebral ischemic symptoms 4 years after cardiac surgery (20). The timing of the neurological presentation in our case is extremely unusual. In addition, the large number of peripheral aneurysms observed in this patient is striking. To our knowledge, there are fewer than 15 cases in the literature in which cerebral aneurysms associated with atrial myxomas are described (2, 3, 5-8, 12, 14, 16, 18, 21, 22). The typical angiographic findings included peripherally located, fusiform aneurysms (3, 5, 7, 8, 14, 18, 22). In our case, essentially all major intracranial arteries distal to the circle of Willis were involved.

The pathogenesis of these aneurysms has not been definitively established. It seems that the aneurysms result from direct embolization of tumor material to the intracranial vasculature, with tumor cells lodging in the smaller, more peripheral arteries (5, 7, 8, 14). The cells may then attach to the vessel wall, weaken the endothelium, and invade the internal elastic lamina. The disrupted vascular wall then dilates in an aneurysmal manner. Pathological analysis of a biopsied aneurysm from our patient revealed myxoid tissue occupying the lumen of the vessel, with invasion of the endothelium and disruption of the internal elastic lamina. These findings are consistent with the few previous reports in which pathological results were available (5, 7, 14).



**FIGURE 1.** Cerebral angiograms, indicating multiple fusiform aneurysms. *A*, anteroposterior internal carotid artery injection. *B*, lateral internal carotid artery injection.



**FIGURE 2.** Intraoperative photograph (*A*) and histopathological analyses (*B* and *C*). *A*, fusiform aneurysm in situ. The efferent artery (arrow) had spontaneously thrombosed because of luminal occlusion by tumor cells. *B*, hematoxylin and eosin stain, demonstrating myxoma cells (asterisk) occluding the lumen (arrows) of the artery (original magnification,  $\times 100$ ). *C*, elastin stain, showing invasion and disruption (asterisk) of the elastic lamina (arrows) (original magnification,  $\times 400$ ).

The natural history of myxomatous aneurysms is not well characterized, which further complicates treatment. Both aneurysm enlargement with time and spontaneous thrombosis and resolution have been reported (3, 18). Although both subarachnoid and intracerebral hemorrhage has been described for patients with myxomatous aneurysms, a direct link between aneurysms

and hemorrhage has been difficult to prove (2, 7, 14). Bobo and Evans (2) described a patient with left thalamic hemorrhage, but myxomatous aneurysms were observed only on the distal branches of the right middle cerebral artery. Reports of subarachnoid and intracerebral hemorrhage in patients with atrial myxomas in the absence of cerebral aneurysms further obscure the causal link (11, 13) and suggest that bleeding in these cases may have resulted from hemorrhagic embolic vascular occlusion.

Interestingly, adjuvant treatment of these aneurysms has been described in only one report. Roeltgen et al. (18) used doxorubicin to treat an enlarging right middle cerebral artery myxomatous aneurysm in a 33-year-old female patient. After a 6-month course of chemotherapy, the aneurysm exhibited no further enlargement on follow-up angiograms. Reluctance to use chemotherapy or radiotherapy has arisen from the uncertain efficacy of these modalities and the unknown natural history of the disease. In our case, options for adjuvant therapy are currently being considered.

For our patient, the transient ischemic events were presumably related to local vascular occlusion, as intraoperatively observed in the cortical branch artery associated with an aneurysm. Because the patient did not experience recurrence of her cardiac tumor, the possibility of recurrent embolization from a central source was excluded. The presence of the aneurysms does indicate, however, previous episodes of tumor embolization. We hypothesize that the growth of these emboli with time led not only to aneurysmal dilation of the vessels but also to occlusion of smaller-caliber vessels. Careful follow-up monitoring of these aneurysms is planned.

## CONCLUSION

The development of multiple intracranial aneurysms attributable to oncotic embolization from atrial myxomas is rare. Even more unusual is delayed presentation with transient ischemic episodes years after surgical removal of the tumor. Patients who have undergone successful resection of a left atrial myxoma may be at risk for delayed ce-

rebral ischemia associated with aneurysm development, and this phenomenon must be considered for patients with neurological symptoms even years after myxoma removal.

## ACKNOWLEDGMENTS

We thank Dr. Cornelius Lam for assistance with the manuscript. We did not receive any financial or intellectual backing for this report.

Received, November 2, 2000.

Accepted, December, 4, 2000.

Reprint requests: Eric S. Nussbaum, M.D., Department of Neurosurgery, University of Minnesota, D429 Mayo Building, 520 Delaware Street SE, Minneapolis, MN 55455. Email: nussb002@tc.umn.edu

## REFERENCES

- Bekavac I, Hanna JP, Wallace RC, Powers J, Ratliff NB, Furlan AJ: Intra-arterial thrombolysis of embolic proximal middle cerebral artery occlusion from presumed atrial myxoma. *Neurology* 49:618-620, 1997.
- Bobo H, Evans OB: Intracranial aneurysms in a child with recurrent atrial myxoma. *Pediatr Neurol* 3:230-232, 1987.
- Branch CL, Laster DW, Kelly DL: Left atrial myxoma with cerebral emboli. *Neurosurgery* 16:675-680, 1985.
- Browne WT, Wijidicks EFM, Parisi JE, Viggiano RW: Fulminant brain necrosis from atrial myxoma showers. *Stroke* 24:1090-1092, 1993.
- Burton C, Johnston J: Multiple cerebral aneurysms and cardiac myxoma. *N Engl J Med* 282: 35-36, 1970.
- Castaigne P, Laplane D, Ricou P, Mallecourt J: Multiple intracranial arterial aneurysms of mycotic appearance: Repeated vascular embolic accidents—Myxoma of the left atrium [in French]. *Rev Neurol (Paris)* 131:339-346, 1975.
- Chen HJ, Liou CW, Chen L: Metastatic atrial myxoma presenting as intracranial aneurysms with hemorrhage: Case report. *Surg Neurol* 40: 61-64, 1993.
- Damasio H, Seabra-Gomes R, da Silva JP, Damasio AR, Antunes JL: Multiple cerebral aneurysms and cardiac myxoma. *Arch Neurol* 32: 269-270, 1975.
- Desousa AL, Muller J, Campbell RL, Batnitzky S, Rankin L: Atrial myxoma: A review of the neurological complications, metastases, and recurrence. *J Neurol Neurosurg Psychiatry* 41: 1119-1124, 1978.
- Diflo T, Cantelmo NL, Haudenschild CC, Watkins MT: Atrial myxoma with remote metastasis: Case report and review of the literature. *Surgery* 111:352-356, 1992.
- Knepper LE, Biller J, Adams HP, Bruno A: Neurologic manifestation of atrial myxoma: A 12-year experience and review. *Stroke* 19:1435-1440, 1988.
- Loeper J, Rouffy J, Loeper J, el-Hachimi A, Hammou JC, Chomette G: Myxoma of the left atrium resembling diffuse inflammatory arteriopathy [in French]. *Ann Med Interne (Paris)* 121:559-566, 1970.
- Macaulay VM, Crawford PJ, McKeran RO: Atrial myxoma presenting with cerebral haemorrhage. *Postgrad Med J* 61:331-332, 1985.
- New PFJ, Price DL, Carter B: Cerebral angiography in cardiac myxoma. *Radiology* 96:335-345, 1970.
- Ng HK, Poon WS: Cardiac myxoma metastasizing to the brain. *J Neurosurg* 72:295-298, 1990.
- Patte M, Rakofsky M, Teleman M, Struyven J, Demeurisse G, Levi S: Left atrium myxoma discovered as the result of a cerebral angiography [in French]. *Acta Neurol Belg* 73:252-263, 1973.
- Price DL, Harris JL, New PFJ, Cantu RC: Cardiac myxoma: A clinicopathologic and angiographic study. *Arch Neurol* 23:558-567, 1970.
- Roeltgen DP, Weimer GR, Patterson LF: Delayed neurologic complications of left atrial myxoma. *Neurology* 31:8-13, 1981.
- Samaratunga H, Searle J, Cominos D, Le Fevre I: Cerebral metastasis of an atrial myxoma mimicking an epithelioid hemangioendothelioma. *Am J Surg Pathol* 18:107-111, 1994.
- Sandok BA, von Estorff I, Giuliani ER: Subsequent neurological events in patients with atrial myxoma. *Ann Neurol* 8:305-307, 1980.
- Steinmetz EF, Calanchini PR, Aguilar MJ: Left atrial myxoma as a neurological problem: A case report and review. *Stroke* 4:451-458, 1973.
- Stoane L, Allen JH, Collins HA: Radiologic observation in cerebral embolization from left atrial myxomas. *Radiology* 87:262-266, 1966.
- Wada A, Kanda T, Hayashi R, Imai S, Suzuki T, Murata K: Cardiac myxoma metastasized to the brain: Potential role of endogenous interleukin-6. *Cardiology* 83:208-211, 1993.

## COMMENTS

This is a rare clinical presentation of intracranial myxomatous aneurysms, which presented as transient ischemic attacks several years after apparently successful treatment of the primary atrial myxoma. The authors review the approximately 15 cases with documented myxomatous aneurysms that were previously reported in the literature. The findings from the biopsy of a peripheral lesion in this case were consistent with previously published results. We also have encountered a case of an atrial myxoma presenting with transient ischemic attacks, and a similar single peripheral aneurysm was excised. The diagnosis was established on the basis of the histological examination results, which led to cardiac evaluation and excision of the primary myxoma.

In this case, the situation was quite different and was indeed unusual. It is

not known whether the patient harbored clinically silent, intracranial, myxomatous aneurysms at the time of diagnosis and treatment of the atrial myxoma. Such lesions might have gradually progressed, leading to occlusion of a branch vessel and the presentation described. Another explanation might be that microscopic myxomatous emboli lodged in cerebral vessels, leading to gradual aneurysmal degeneration with time.

We agree with the authors' approach, with close expectant monitoring of these lesions. Little is known regarding their prospective natural history and associated prognosis. Only symptomatic and more likely treated cases have been reported in the literature. Many others may be undiagnosed, unrecognized, and/or untreated. In contrast to bacterial mycotic aneurysms, the relationship of these myxomatous aneurysms to hemorrhage is not well established. They are more likely associated with ischemic complications or unrelated brain hemorrhage. In some cases, they have been observed to progress to parent vessel occlusion.

This case emphasizes the importance of long-term monitoring of patients with atrial myxomas, with a low index of suspicion for thinking about and diagnosing these lesions. This report does not address the question of whether follow-up surveillance with magnetic resonance angiography should be performed every few years for patients with atrial myxomas.

**Issam A. Awad**  
Denver, Colorado

The authors report the fascinating case of a patient who presented with transient ischemic attacks 5 years after removal of an atrial myxoma. As the authors document in their review of the literature, it is extraordinarily rare for such a patient to develop, years later, multiple myxoma-related aneurysms and neurological symptoms resulting

from them. This report should add a level of complexity to the differential diagnosis of patients who present with transient ischemic attacks with a history of atrial myxoma, even if treatment for the latter condition occurred years earlier. This report also suggests that the growth of tumor cells within the vessel wall occurs very slowly and obviously requires adjuvant therapy if the disease is diffuse, as in this case.

**H. Hunt Batjer**  
Chicago, Illinois

Jean et al. provide us with a fascinating case of a 32-year-old woman who presented with transient ischemic attacks 5 years after seemingly successful resection of her left atrial myxoma. Angiography demonstrated the presence of multiple, peripherally located, fusiform aneurysms, which proved to be myxomatous in origin after one such lesion was excised and histologically examined. The authors suggest that late neurological complications resulting from successfully treated left atrial myxomas are quite rare. From their own literature search, it can be concluded that the incidence is no greater than 3% among patients who harbor these unusual tumors. Using the values provided by the authors and knowing the size of my own referral base, I calculate that, on average, I should have encountered only two such cases in my career to date. Apparently I missed both of them.

A question that occurs to me as I read this report is whether transthoracic echocardiography is sufficiently sensitive to detect recurrence. Would transesophageal echocardiography or gated magnetic resonance imaging be superior?

The real crux of the case, however, is how to treat this individual. Antiplatelet therapy has obviously proven to be successful in the short term. But will these lesions progress? I think that everyone would agree with the authors regarding the need for close follow-up monitoring.

The role of chemotherapy remains intriguing, although I certainly have no answers in this regard. Like the authors, I could find only one example in the literature of adjuvant treatment for the management of aneurysms associated with an atrial myxoma. I did, however, find another example of adjuvant treatment for the management of parenchymal metastases. Bernet et al. (1) described a 31-year-old male patient with an atrial myxoma with metastases to soft tissue, lung, and brain. The brain metastases consisted of multiple parenchymal lesions, some measuring more than several centimeters in size. The patient was treated with doxorubicin, ifosfamide, and external-beam radiation (5000 cGy). After 10 years, the patient was in clinically stable condition and free of disease. Given the paucity of data, however, I share the authors' reservations regarding adjuvant treatment.

Although the authors did not elaborate on this point, I find the premise put forth by Wada et al. (2) to be intriguing. Those authors suggest that the endogenous production of interleukin-6 by atrial myxomas may be related to their potential invasiveness and ability to metastasize through vascular channels. Further studies will be needed to determine whether serum levels of interleukin-6 are in any way predictive of future cerebral events. Given the rarity of this tumor type, however, I do not expect to see such studies in the near future.

**Robert E. Breeze**  
Denver, Colorado

## REFERENCES

1. Bernet F, Stulz PM, Carrel TP: Long-term remission after resection, chemotherapy and irradiation of a metastatic myxoma. *Ann Thorac Surg* 66:1791-1792, 1998.
2. Wada A, Kanda T, Hayashi R, Imai S, Suzuki T, Murata K: Cardiac myxoma metastasized to the brain: Potential role of endogenous interleukin-6. *Cardiology* 83:208-211, 1993.

**OPERATIVE**  
*Nuances*