
Mirrored-self Misidentification: Two Cases of Focal Onset Dementia

Nora Breen^{1,2}, Diana Caine^{2,3} and Max Coltheart¹

¹Macquarie Centre for Cognitive Science, Macquarie University, NSW 2109, ²Neuropsychology Unit, Royal Prince Alfred Hospital, NSW 2050 and ³Department of Medicine, University of Sydney, NSW 2006, Australia

Abstract

We present two patients in whom the mirror sign, the inability to recognize one's own reflected image, was a stable and persisting symptom signalling the onset of a progressive dementing illness. Extensive neuropsychological testing was conducted with both patients, with particular emphasis on face processing and the understanding of reflected space. Both patients were also investigated with structural imaging techniques (computed tomography and magnetic resonance imaging). Although the neuroimaging results were not strongly lateralizing for either patient, neuropsychological testing revealed striking right hemisphere dysfunction with relatively intact left hemisphere cognitive function in both patients. Of particular interest was the patients' dissociation on tests of face processing; one patient, FE, had significant face processing deficits while the other patient, TH, had relatively intact face processing. Further testing with TH revealed striking deficits in his ability to interpret reflected space. The results of the face processing tests are discussed in the context of current models of normal face processing, with particular emphasis on the affective component in face recognition. We propose that a combination of cognitive deficits underlie the mirror sign delusion, including perceptual, affective and reasoning impairments, and also discuss the contributions of cortical and subcortical lesions in these two patients and in delusions in general.

Introduction

The umbrella term 'delusions of misidentification' (DM) encompasses a variety of delusory beliefs concerning the identity of oneself, other people, places or objects. These include the mirror sign (*signe du miroir*), the inability to recognize one's reflected image, which has been observed infrequently and most often in patients with advanced global dementia (Foley and Breslau, 1982; Forstl *et al.*, 1991a; Mendez *et al.*, 1992; Bologna and Camp, 1997). Whereas 20–30% of patients with Alzheimer's disease make misidentification errors (of people, television characters, etc.), a much smaller number (2–10%) misidentify their own reflection (Rubin *et al.*, 1988; Burns *et al.*, 1990; Deutsch *et al.*, 1991; Forstl *et al.*, 1991a; Mendez *et al.*, 1992). Because of the global and extensive cognitive deterioration in such patients, detailed cognitive testing has almost invariably been limited and the patients have not generally been able to communicate much, if at all, about the experience itself. In contrast to these previously reported cases, we present the extensive neuropsychological investigation of two patients in whom a stable persisting mirror sign heralded the onset of a dementing illness.

In recent years, studies of patients with DM, in particular,

the Capgras delusion—the belief that certain people, usually the spouse or close relatives, have been replaced by near-identical impostors (Capgras and Reboul-Lachaux, 1923)—have focused on whether these patients have underlying face processing impairments. Although many patients have subtle deficits in face recognition and memory for faces (Young, 1998), they do not have difficulty recognizing faces in daily life. Based on Bauer's (1984, 1986) two-route model of face processing, involving a primary visual route and a secondary affective route in the recognition of known faces, Ellis and Young (1990) proposed that Capgras patients may have relatively intact visual face recognition, but a reduction or absence of the affective route to face recognition. This would lead to a loss of the sense of familiarity that normally results from the affective response to faces of known individuals. Without this sense of familiarity, the Capgras patients develop the delusion that despite the misidentified person looking very much like the original, this person must be an impostor or double. Two independent research groups have now demonstrated this by showing that Capgras patients, unlike normal controls, do not differ in their skin conductance response to known and unknown faces (Ellis *et al.*, 1997;

Hirstein and Ramachandran, 1997). Ellis and Young (1990) further proposed that underlying face processing deficits, corresponding to particular stages of face processing, may explain different forms of DM. A correlation between face processing deficits and the Cotard delusion (belief that one is dead) has now been reported in several patients (Young *et al.*, 1992; Leafhead and Kopelman, 1997).

This approach led us to consider a possible role for face processing deficits in patients with the mirror sign. Despite little formal testing, face processing deficits have generally been dismissed as insignificant in the formation of the mirror sign delusion. Of 20 cases of mirror sign delusion reported, 11—only one of whom was formally tested—were reported as definitely not having prosopagnosia on the basis of their ability to recognize the faces of highly familiar people in person and from pictures or due to their ability to recognize the reflection of other people in the mirror (Foley and Breslau, 1982; Feinberg and Shapiro, 1989; Molchan *et al.*, 1990; Feinberg, 1997; Spangenberg *et al.*, 1998). There was no comment on this issue in eight other cases (Gluckman, 1968; Cummings, 1985; Forstl *et al.*, 1991a; Mendez, 1992; Bologna and Camp, 1995, 1997). Only one mirror sign case, EF, has been reported with prosopagnosia (Phillips *et al.*, 1996), as demonstrated by a severe impairment on both the Warrington Recognition Memory Test for faces, and a test of famous face recognition. Despite these deficits, EF was able to recognize photographs of her husband and herself, thereby demonstrating the need for formal investigation of this question. To date, the role of face processing impairments in the mirror sign delusion remains largely unexplored.

Since Weinstein *et al.* (1952) first drew attention to the preponderance of instances of right as opposed to left hemisphere damage in misidentification syndromes involving reduplication, many authors have linked right hemisphere, or more specifically right cortical, dysfunction, with various forms of DM (Crichton and Lewis, 1990; Young *et al.*, 1991; Ellis, 1994; Stone and Young, 1997). In contrast, Cummings (1986, 1997) has argued that the cortex may play only a secondary role in the formation of delusions such as the Capgras delusion, and that the crucial factors leading to the development of delusions are limbic system lesions and basal ganglia dysfunction. Cummings proposed that any lateralized cortical involvement might modify the delusion by contributing specific characteristics to its form and content. In a review of the English language Capgras literature spanning the last 30 years (1968–1999), we found 69 case reports that included structural brain imaging results (see Table 1). Twenty-seven cases had normal imaging. Of the remaining 42 cases, 31 were reported to have global atrophy or bilateral brain damage, two had global atrophy and a right focal lesion, six had a right hemisphere lesion(s) only and one had left hemisphere lesions only. Two cases demonstrated congenital brain abnormalities only and were excluded from the classification. While the majority of the cases reviewed had bilateral atrophy or brain damage on structural imaging, the small number of cases with lateralized lesions supports

the proposal that right hemisphere lesions are more prevalent in Capgras patients than left hemisphere lesions.

Here we present two cases in which the delusional mirror sign belief remained stable for the investigation period of 2 years in one case and 10 months in the other. The patients retained excellent language skills and detailed conversations were undertaken throughout these periods to explore the patients' experiences of the delusional belief (Breen *et al.*, 2000b). A range of neuropsychological tests was administered to identify the specific nature of any underlying cognitive deficits and to test current theories regarding the cognitive basis of DM. In particular, tests were administered to assess aspects of face processing, the understanding of reflected space and mirrors, and whether these patients experienced generalized depersonalization and/or derealization. The results will be discussed with respect to their implications for both current cognitive modelling of normal face processing and for understanding the mirror sign delusion.

Case reports

Patient FE

At the time of presentation, FE was an 87-year-old gentleman who was married with two children. He had owned a number of successful businesses throughout his working life, and had retired at the age of 84 years. His medical history was unremarkable until the age of 86 years, when he was admitted to hospital after a brief episode of poor hand co-ordination. A transient ischaemic attack was diagnosed. He was discharged home and soon after began having occasional nocturnal hallucinations, which usually involved seeing women and children in his house. There was no other change in his mental state at that time. One year later, FE and his family moved into a new house, and it soon became apparent that FE was unable to recognize his own reflection in the mirror (mirror sign).

The initial neurological examination was normal. His visual fields were full to confrontation and his visual acuity was judged to be normal as he was able to read without difficulty. Serenace was prescribed on two occasions, but it did not affect the mirror sign delusion. The neurological opinion was that FE had a dementia on a vascular basis, although there was clinical evidence of only one definite lacunar infarct.

Description of mirror sign delusion (for a detailed report of the delusional phenomenology, see Breen et al., 2000b). FE believed that his own reflection was another person who was following him around, not only in his home, but anywhere that there was a reflecting surface. FE had attempted to communicate with the person on numerous occasions and was somewhat perturbed that the person never replied but was otherwise undisturbed by the stranger's presence. He would listen attentively to his family's attempts to reason with him, and could articulate that they had told him that

the person was 'a non-entity because it was only a reflection', yet this did not shake his belief that his reflection was a person other than himself. FE continued to shave before a mirror, but it was apparent that he shaved in an automatic fashion, rarely looking at his reflection. FE's semantic knowledge about mirrors was entirely intact. He was able to define what both a mirror and a reflection were and accurately described when a mirror would be used.

FE's mirror sign delusion remained stable over the next 2 years. FE's wife reported that as time went on he began to have difficulty recognizing her reflection. FE incorporated the reflection of his wife into his mirror sign delusion, as evidenced in his report 'I have met the stranger's wife, seen her. I don't think she talks either'.

Neuroradiological examinations. A computed tomography (CT) brain scan reported multiple small paraventricular lacunar infarcts and some generalized reduction in the density of the paraventricular white matter suggestive of chronic small vessel white matter ischaemia. A magnetic resonance imaging (MRI) brain scan 1 year later was reported as showing diffuse cerebral and cerebellar atrophy, and scattered high signal intensity throughout the white matter, however, these findings were reported as appropriate for the patient's age (see Fig. 1).

Evolution of the disease. Twenty-one months after the onset of the mirror sign, FE's sleep/wake cycle became very disturbed and he was admitted to a nursing home. FE remained completely self-caring at that time. The final neuropsychological testing session was conducted in the nursing home 8 months later. At that time he was mobile and self-caring, his conversational speech remained intact and he was able to undertake the range of experimental tests. He remembered the examiner's name and was able to recall details of their previous testing session which had been 4 months previously. However, in the 21 months following the last testing session, FE's condition deteriorated dramatically. In November 1999, almost 4 years after the onset of the mirror sign delusion, FE was completely dependent, incontinent, confined to bed and required maximal assistance to feed, shower and dress. He was able to state his name, but was unable to answer any other simple questions or follow simple commands. FE died in January 2000, 4 years after the onset of the mirror sign delusion. The cause of death was documented as pneumonia and dementia. FE's family did not consent to a brain autopsy so there is no pathological diagnosis.

Patient TH

When first seen TH was 77 years old, and married with three children. He had been experiencing the mirror sign for several months. He had a varied work history which included having been at various times an Evangelical missionary, farm labourer, storeman, market gardener, truck driver and

maintenance worker. TH's medical history included meningitis at the age of 5 years, from which he was thought to have made a full recovery. He had been a heavy drinker for a period of 15 years starting when he was a teenager, but he had been abstinent from alcohol since the age of 30 years. He suffered a head injury as a young man, that resulted in a 30-min period of loss of consciousness, but he was not admitted to hospital and again he stated that he made a full recovery. He had a history of atrial fibrillation, and suffered a cardiac arrest when he was 63 years of age. He had radiotherapy treatment for multiple myeloma at the age of 64 years. He had mild emphysema. Notwithstanding this catalogue of events and ailments, TH had never considered himself or been considered by others to be cognitively impaired prior to the onset of the condition described in this report.

A neurological examination 5 months after the onset of the mirror sign delusion was unremarkable. TH scored 25/30 on the Mini-Mental Status Examination, a normal performance for his age (Folstein *et al.*, 1975; Anthony *et al.*, 1982). His visual fields were not formally tested, but his acuity was judged to be normal based on his intact reading ability. He had an EEG which showed slowing of background rhythms consistent with a diffuse degenerative process. A trial of haloperidol was unsuccessful, and the mirror sign delusion remained stable. The provisional neurological diagnosis was that TH had an atypical dementia, not entirely consistent with classic Alzheimer's disease or with Lewy Body dementia.

Description of the mirror sign delusion (see also Breen et al., 2000b). TH described his reflection as a person who was a 'dead ringer' for himself. TH frequently attempted to talk to the person, and said that as the person never replied he could only assume that he had something wrong with his voice or tongue. When asked what he thought the person's personality was like, TH replied that the person had not given him any reason to be suspicious. Asked where the person lived, TH said that he lived in an apartment adjoining TH's own apartment (although there was no other apartment on that block of land). Further evidence of a reduplicative paramnesia arose during a hospital admission 7 months after the onset of the mirror sign delusion when TH said that in addition to the hospital (B_____) where he was, there was another identical hospital with the same name and a third hospital that was also the same but was named B_____ West. TH fluctuated in his ability to identify other people in the mirror. On some occasions he correctly identified the reflections of both the examiner and his wife. However, on one occasion he reported that he had seen the person's wife and that she looked very much like his own wife and that the two women wore very similar clothes, suggesting that at least some of the time TH was not recognizing her reflection. Specific questioning with TH revealed that his semantic knowledge for mirrors was intact.

At the time of TH's first presentation, the mirror sign

Table 1. Case reports of the Capgras delusion including structural brain imaging published during the period 1968–1998

Study	Case name	Sex	Age (years)	Brain	Imaging	Diagnosis
Normal						
Atwal and Khan, 1986	Mr X	M	34	CT	Normal	Paranoid disorder
Baldwin <i>et al.</i> , 1995		F	68	CT	Normal	Cortical Lewy Body disease
Bienefeld and Brott, 1989	Ms A	F	81	CT	Normal	Minor head trauma superimposed on hyperthyroidism and probable benign senescent forgetfulness
Burjorjee and Al-Adawi, 1992		M	50	CT	Normal	Possible stroke
Christodoulou, 1977 ^a	KK	M	40	CT	Normal	Schizophrenia
	PP	F	64	CT	Normal	Depression
	AK	F	43	CT	Normal	Schizophrenia
	TA	F	50	CT	Normal	Schizophrenia
	JD	F	60	CT	Normal	Depression
	PK	F	43	CT	Normal	Schizophrenia
Collins <i>et al.</i> , 1990	Case 2	F	31	CT	Normal	Nephrotic syndrome
De Pauw and Szulecka, 1988	Mr SC	M	29	CT	Normal	Schizophrenia
Hayman and Abrams, 1977	RS	F	51	CT	Normal	Organic brain disease
MacCallum, 1973	Case 2	F	28	CT	Normal	Basilar migraine
Rojo <i>et al.</i> , 1991	Mr A	M	32	CT	Normal	Insulin-dependent diabetes. Metabolic encephalopathy
Sanati and Mojtabai, 1992	Mr A	M	19	CT	Normal	Schizophrenia
Shraberg and Weitzel, 1979	AR	F	57	CT	Normal	Paranoid personality
Silva <i>et al.</i> , 1992	Ms B	F	32	CT	Normal	Schizoaffective disorder
Silva <i>et al.</i> , 1994	Mr B	M	34	CT	Normal	Schizoaffective disorder
	Case 3	M	25	CT	Normal	Schizophrenia
	Case 4	M	45	CT	Normal	Schizophrenia
	Case 5	M	39	CT	Normal	Schizophrenia
	Case 6	M	29	CT	Normal	Schizophrenia
Silva and Leong, 1995	Ms A	F	32	CT	Normal	Schizophrenia
				MRI	Normal	
Smyth and Dean, 1992		M	23	CT	Normal	Bipolar affective disorder
Waziri, 1978		F	30	CT	Normal	Schizophrenia. Possible neuroleptic toxicity
Wright <i>et al.</i> , 1993	KH	M	35	CT	Normal	Organic delusional syndrome
Bilateral brain damage/atrophy						
Alexander <i>et al.</i> , 1979		M	44	CT	Atrophy of right frontal and temporal regions. Patchy decrease in density in the left inferomedial frontal lobe. Generalized ventricular enlargement in the frontal horns, greater on the right	Head injury
Cawte and Tarrant, 1984	Mrs C	F	76	CT	Moderate atrophy	Subacute delirium associated with inappropriate antidiuretic hormone secretion, subnutrition and dehydration
Collins <i>et al.</i> , 1990	Case 3	F	74	CT	Mild atrophy	Diabetes mellitus. Hypoglycaemic episodes. Three years after the Capgras episode she was diagnosed with dementia
Edelstyn <i>et al.</i> , 1998	Case 1	M	69	CT	Prominent cortical sulci and sylvian fissure	Parkinson's disease. Possible Lewy Body disease
Forstl <i>et al.</i> , 1991b		F	77	CT	Mild generalized cortical atrophy and marked atrophy of the parieto-occipital cortex	Alzheimer's dementia
Gluckman, 1968		F	61	CT	Moderate degree of enlargement of the ventricles, with some enlargement of the cerebral sulci	Cerebral atrophy Paranoid schizophrenia
Hirstein and Ramachandran, 1997	DS	M	30	CT	Enlarged ventricles, with the right lateral ventricle being especially large. Bilateral areas of encephalomalacia, most prominent bifrontally	Head injury
Jenkins <i>et al.</i> , 1997	Case 8	F	83	MRI	Large confluent areas of high signal intensity in right frontotemporal white matter. Widespread hyperintensities throughout the white matter of both hemispheres, worse on the right than the left	Organic delusional disorder

Table 1. continued

Study	Case name	Sex	Age (years)	Brain	Imaging	Diagnosis
Joseph <i>et al.</i> , 1990	Group study	F ^b M ^c	Range 20–50 Median 34	CT	Compared with a control group, patients had significantly more bilateral frontal and temporal lobe atrophy	All diagnosed with paranoid schizophrenia
Kumar, 1987		F	73	CT	Consistent with a generalized degenerative process	Probable Alzheimer's dementia
Lebert <i>et al.</i> , 1994		F	40	CT MRI	White matter hypodensities in subcortical and biparietal areas Symmetrical periventricular white matter signal changes and bilateral signals in the parietal and internal-temporal regions, and atrophy of the corpus callosum	Multiple sclerosis
Lewis, 1987	Jane	F	19	CT	Bilateral occipitotemporal lesions, and smaller symmetrical lesions in the frontal region	Interictal psychosis of epilepsy, precipitated by medication toxicity
Lipkin, 1988	Mrs R	F	71	CT	Mild cerebral atrophy	Dementia
Mackie <i>et al.</i> , 1994		M	25	MRI	Mild ventricular dilation	Schizophrenia
Miller <i>et al.</i> , 1989	Case 1	F	86	CT	Diffuse cerebral atrophy, scattered lacunar infarct, diminished attenuation in the deep white matter underlying the frontal and parietal cortex	Delusional disorder. Dementia
Quinn, 1981	Mr T	M	66	CT	Diffuse cortical atrophy	Acute confusion. Medication toxicity
Silva <i>et al.</i> , 1994	Mr A	M	49	CT	Small calcification of basal ganglia bilaterally	Schizophrenia
Thompson and Swan, 1993	Case 2	M	30	CT	Dilated lateral ventricles	Schizophrenia
Todd <i>et al.</i> , 1981		F	68	CT	Frontal cerebral atrophy	Paranoid schizophrenia and organic brain disease
Young <i>et al.</i> , 1993	ML	F	60	CT	Dilatation of extracerebral spaces filled with cerebrospinal fluid, although not advanced for her age	Delirium, precipitated by hypoxia secondary to pulmonary embolism
Bilateral brain damage/atrophy and right hemisphere focal lesion						
Burns, 1985		F	90	CT	Moderate atrophy. Infarct in the right frontoparietal region	Paranoia
Crichton and Lewis, 1990		M	30	CT	Widened sulci over the vertex, and a small area of diminished density in the right upper medial parietal region, thought to be compatible with a resolving toxoplasma, pneumocystic or cytomegaloviral lesion	AIDS
Right hemisphere lesion only						
Bouckoms <i>et al.</i> , 1986	Mrs B	F	66	CT	Loss of volume in the right frontal lobe (1 year post-Capgras onset)	Subarachnoid haemorrhage
Collins <i>et al.</i> , 1990	Case 1	F	69	CT	Infarct in right internal capsule	Stroke
Hayman and Abrams, 1977	TJ	M	37		–	Right frontoparietal, right lateral ventricular and right basal ganglia haematoma demonstrated at open surgery 2 years prior to delusion
O'Connor <i>et al.</i> , 1996	EB	F	74	CT	Right temporoparietal haematoma	Head injury. Possible early stages of dementia
Rapcsak <i>et al.</i> , 1994	WJ	M	68	CT	Frontotemporoparietal infarction, covering entire area of right middle cerebral artery	Stroke
	BH	M	71	CT	Frontotemporoparietal infarct, covering area of right middle cerebral artery	Stroke
Left hemisphere lesion only						
Todd <i>et al.</i> , 1981		M	56		–	Regenerative brain tumour (left cerebellar and temporal lobes) and neurosurgery to remove it

CT, computed tomography; MRI, magnetic resonance imaging.

^aChristodoulou states that brain scanning was negative in all patients. We presume that this refers to CT imaging.

^b*n* = 7.

^c*n* = 5.

Two cases (Paillere-Martinot *et al.*, 1994; Wilcox, 1984) were not included in the table as structural imaging revealed congenital brain abnormalities only.

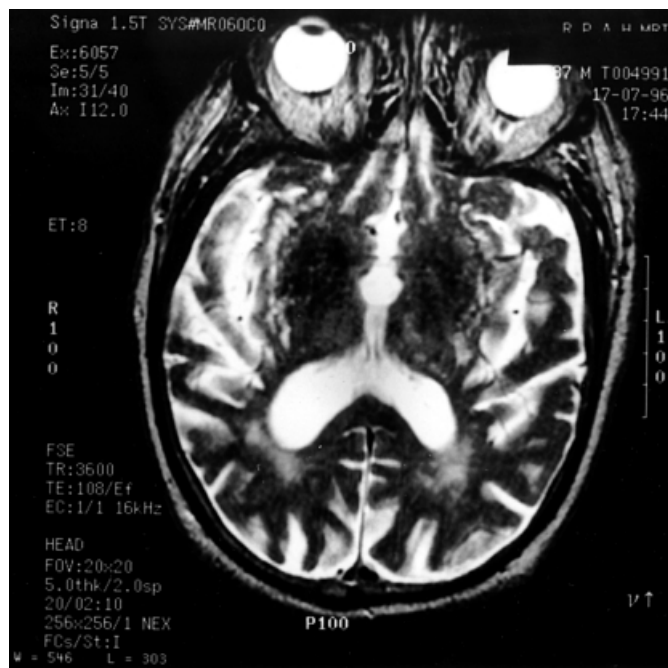

Fig. 1. FE's T2-weighted MRI image showing diffuse cerebral atrophy and scattered high signal intensity throughout the white matter.

delusion had been stable for 5 months, and he continued to have the delusion during the 10-month follow-up period.

Neuroradiological examinations. CT brain scans at the onset of the mirror sign delusion and at follow-up 5 months later were both reported as normal. An MRI brain scan 6 months after onset of the delusion reported diffuse cerebral atrophy, diffuse increased signal in the deep white matter and periventricular areas and patchy areas of increased signal in the pons, all of which were presumed to be ischaemic (see Fig. 2). A small cortical infarct in the posterior right frontal lobe was also reported. A baseline single photon emission computed tomography (SPECT) study at the time of onset of the delusion reported perfusion defects in the posterior parietal cortices bilaterally, but was otherwise normal.

Evolution of the disease. TH was first assessed in November 1997 and testing continued during that year and the following year. In February 1998 TH was admitted to hospital with a left facial droop and left arm and leg weakness. He was discharged from hospital into a nursing home, largely due to his wife's poor health and her inability to cope with TH's disturbed sleep/wake cycle. Further neuropsychological assessments with TH were conducted at the nursing home in 1998. At the time of the last neuropsychological testing session in August 1998, TH's conversational speech was intact and he was able to undertake a range of tests involving mirrors. He identified the examiner by name and was able to recall details of the last session with the examiner 4 months previously. He was mobile, continent and self-caring. In the following 2 years, however, his condition deteriorated dramatically. As of March 2001, TH was completely depend-

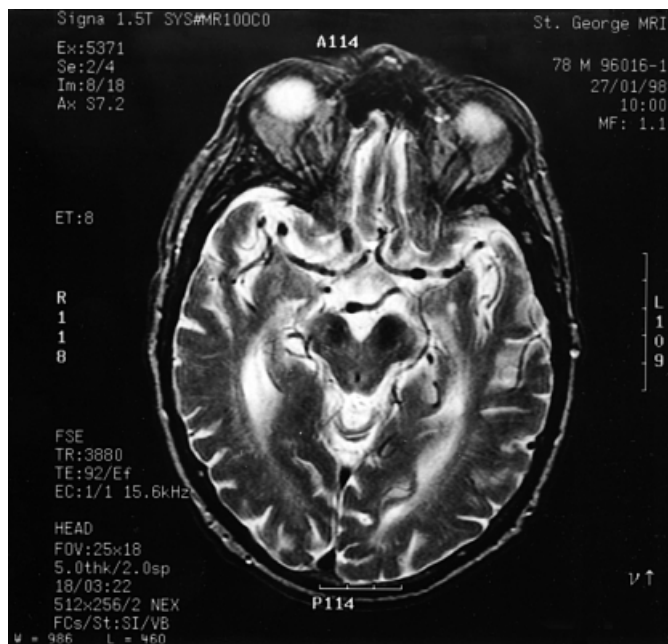


Fig. 2. TH's T2-weighted MRI image showing diffuse cerebral atrophy and diffuse increased signal in the white matter and periventricular areas.

ent in activities of daily living including feeding, showering and dressing and was incontinent. He required two people to assist transfers from his bed to a chair. He was able to state his name but was unable to answer any other simple questions or follow one step commands.

Neuropsychological testing

Neuropsychological testing was undertaken to evaluate their performance in a range of cognitive domains. FE and TH's informed consent was obtained prior to the neuropsychological testing.

As can be seen in Table 2, both patients were of normal intelligence with very well-preserved verbal memory, vocabulary and semantic ability. Although their basic visuo-perceptual skills were intact, they both displayed gross visuoconstructional problems and poor visual memory, indicative of profound right hemisphere dysfunction. In addition, both patients were found to perform poorly on some executive tasks.

Investigation of face processing

A thorough investigation of FE and TH's face processing abilities was conducted using a combination of standardized and experimental tasks including tests of recognition of personally familiar (as opposed to famous) faces. Each of their wives was the control subject on the experimental face processing tests that involved recognition of personally familiar faces. The results of FE and TH on the face processing tests are summarized in Table 3.

Table 2. Neuropsychological results for patients FE and TH. The scores reported for FE and TH on the Wechsler Adult Intelligence Scale-Revised (WAIS-R), Wechsler Memory Scale-Revised (WMS-R) and Controlled Oral Word Association Test (COWAT) are age-scaled scores (ASS) as reported in the Mayo older American normative studies (Malec *et al.*, 1992; Ivnik *et al.*, 1992a, b, 1996)

Test	Patient FE	Patient TH
<i>IQ</i>		
NART	103 (average)	116 (high average)
<i>WAIS-R (Wechsler, 1987)</i>		
Vocabulary		16
Arithmetic	10	
Similarities	5	10
Picture completion	2	
Block design	2	
<i>Memory</i>		
<i>WMS-R (Wechsler, 1981)</i>		
Orientation	12/14	12/14
Mental control	10	5
Digit span	12	10
Logical memory I	8	10
Logical memory II	9	9
Visual reproduction I	3	2
Visual reproduction II	3	Not administered
<i>Language tests</i>		
<i>PALPA</i>		
Spoken word–picture matching	38/40	40/40
BNT	36 ASS 6	54 ASS 11
<i>Visuoperceptual and spatial tests</i>		
<i>RCFT</i>		
Clock drawing	Incomplete copy	Incomplete copy
First attempt	5	4
Second attempt	5	5
Hooper VOT	5.5	
<i>TMT</i>		
Trails A	<10th percentile	Incomplete
Trails B	Incomplete	
Line cancellation		Normal
Line bisection		Normal
<i>Executive function</i>		
<i>COWAT</i>		
FAS	9	8
<i>Category fluency</i>		
Animals	11 (raw score)	7 (raw score)
<i>Stroop (50-item version)</i>		
Words—time in s (errors)	104 (1)	55 (0)
Colours—time in s (errors)	382 (28)	Incomplete
<i>Praxis</i>		
Western aphasia battery (Kertesz, 1982)	58/60 (to command)	
TOLA		84/90 SS 12

NART, National Adult Reading Test (Nelson, 1982); PALPA, Psycholinguistic Assessment of Language Processing in Aphasia Battery (Kay *et al.*, 1992); Hooper VOT, Hooper Visual Organization Test (Hooper, 1957); TMT, Trail Making Test; TOLA, Test of Oral and Limb Apraxia (Helm-Estabrooks, 1992); BNT, Boston Naming Test (Kaplan *et al.*, 1983); RCFT, Rey Complex Figure Test.

Experiment 1. Face matching

Face matching was initially assessed with the Benton Facial Recognition Test (Benton *et al.*, 1983). This is a difficult test of face recognition for several reasons: cues are limited (matching is conducted on the basis of facial features only, as hairstyles have been removed); the varied lighting often results in significant portions of the faces being covered by dark shadow; and the subject is often required to match faces

that are in very different orientations. Therefore, we also devised a much simpler face matching test which required the subject to match a black and white photograph of a face with one of four alternatives matched for gender, approximate age and physical similarity presented in a 2×2 array. Each face was 10×7.5 cm in size, substantially larger than the 3×3 cm face stimuli in the Benton Face Recognition Test. The lighting was invariant in all of the photographs, each face in the test was front facing and each photograph included the person's hairstyle. The correct match was identical with the target.

Results. FE performed very poorly on the simple face matching test, matching only 6/16 correctly. Not surprisingly, on the more difficult Benton Face Recognition Test, he performed in the severely impaired range. In contrast, TH correctly matched 14/16 faces in the simple face matching test, and was in the normal range in the Benton Face Recognition Test.

Experiment 2. Identification of face gender

FE and TH were asked to identify the gender of familiar and unfamiliar faces.

Results. FE was mildly impaired on this task, correctly identifying 16/18 males and 16/22 females. His wife scored 100%. TH correctly identified 24/24 faces as male and 27/28 faces as female, a normal performance, compared with his wife's scores of 22/24 males and 28/28 females.

Experiment 3. Famous face/name recognition

The identification of famous faces was assessed with an experimental test consisting of photographs of the faces of 10 famous (See Appendix for Australian control data on the faces used) and 10 unknown people. The unknown faces were matched to the famous faces according to gender, age and physical similarity. The faces were presented as black and white portrait photographs (10×10 cm), with no other cues visible. The 20 faces were presented in a random order. The subjects were asked to state whether each face was familiar or not, and to name the faces identified as familiar. FE was also assessed on famous face recognition using a subset of 40 faces, judged to be familiar to most people of his age in the Australian context, from the Albert Famous Faces Test.

The patients' ability to identify famous personalities by name was also examined. FE's ability to access identity-specific information about famous people from their name was assessed using the names of eight famous people whose faces he had been asked to identify. He was asked to provide as much information as possible about each person in response to hearing the name. TH was tested in the same way using the names of 39 famous people, including the 10 whose faces he had been asked to name.

Table 3. Face processing test results for FE and TH

Tests	FE	Norms	TH	Norms
<i>Unfamiliar faces</i>				
Face matching				
Simple face matching	6/16		14/16	
Facial Recognition Tests (Benton)	34 (severely impaired)		41 (normal)	
Identification of face gender				
Males	16/18	18/18	24/24	22/24
Females	16/22	22/22	27/28	28/28
Recognition memory for faces				
WRMT faces	32/50	<5th percentile	29/50	<5th percentile
WRMT words	38/50	10–25th percentile		
<i>Familiar faces</i>				
Famous face identification				
Albert Famous Faces	1/40			
Famous face/stranger's face test ^a				
Famous faces				
Identified as familiar	9/10		9/10	
Identity-specific information (Norms mean 8, SD 1.5)	1/9		8/9	
Strangers' faces				
Identified as unfamiliar	1/10		6/10	
Family face recognition test		Control (wife)		Control (wife)
Immediate family				
Identified as familiar	8/8	8/8	8/8	8/8
Correctly named	7/8	8/8	7/8	6/8
Misidentified	0	0	0	1
Relatives				
Identified as familiar	8/12	12/12	18/18	16/18
Correctly named	1/12	10/12	15/18	14/18
Misidentified	1	0	0	1
Strangers				
Identified as unfamiliar	8/20	20/20	21/26	26/26
Misidentified	5	0	6	0
<i>PIN access via famous names</i>				
Correct identity-specific information	6/8		36/39	

WRMT, Warrington Recognition Memory Test (Warrington, 1984); PIN, person identity node.

^aSee Appendix for test description.

Results. Although FE was unable to name correctly any of the 40 famous faces from the Albert Famous Faces Test, he thought many of the faces were familiar and personally known to him. For example, he thought a photograph of Burt Reynolds (movie actor), was that of the man who worked at his local petrol station. When shown the face of Billie Jean King (tennis player), FE said that she was a familiar face around his suburb. FE identified the face of John Denver (singer) as someone who had sold him office machines in the past and identified Tom Selleck (movie actor) as a regular attendee at FE's local church.

On the famous face/stranger's face test, FE rated 9/10 of the famous faces as being familiar but was only able to provide identity-specific semantic information for one. He provided very general semantic information (not identity-specific) for one famous face ('he's a well-known identity'), misidentified two of the famous faces as being hospital employees, and said that, although they were familiar, he did not know who the other five famous faces were. FE's famous face recognition on this test was well below the average of eight faces correctly identified by name by men of FE's age (SD 1.5; see Appendix). In addition to his difficulty in correctly identifying the famous faces on this test, FE also

misidentified 9/10 of the unfamiliar faces as being familiar. TH identified 9/10 of the famous faces as familiar and correctly named 8/9, which is within the normal range for TH's sex and age (see Appendix). With the matched strangers' faces, TH correctly identified 6/10 as unfamiliar, but incorrectly identified the other four strangers' faces as familiar.

FE was able to provide identifying semantic information for 6/8 of the names (e.g. for Winston Churchill, 'Prime Minister of England'; for Don Bradman, 'Australian cricketer'), indicating that semantic information was accessible by name although not by face. TH gave identifying semantic information for 36/39 famous people.

Experiment 4. Recognition of personally known faces

In a preliminary investigation, FE was shown photographs of family members, relatives and strangers and asked if they were familiar or not. While some of the photographs contained individuals only, others were group photographs. In all he was asked to identify 22 personally known people (18 close family members and four infrequently seen relatives) and 56

strangers. If FE thought the individuals were familiar, he was asked to provide as much information about them as possible including their name. FE recognized as familiar 18/18 immediate family members (including himself, his wife, son and daughter), and correctly named 15. For the remaining three, he provided general semantic information for one ('a relative') and stated that one was familiar but he did not know who it was. FE correctly identified the four more distant relatives as familiar, and provided correct semantic information for two but misidentified the other two (his sister-in-law and niece, both of whom he thought were his wife). At the same time, he rated 23/56 photographs of strangers as familiar, and of those he provided erroneous semantic information for six (e.g. 'a friend' or 'a neighbour'), said that eight were familiar but he did not know who they were, and misidentified nine (many incorrectly identified as deceased relatives). All of these photographs were unmodified, often containing not only the face but also bodies and clothing, as well as background cues that may have assisted recognition.

Following this preliminary testing with FE, familiar face recognition was examined more stringently in both patients with individually tailored test stimuli. Photographs of immediate family members and relatives were modified to produce black and white pictures of the faces of individual family members or friends without any other cues (e.g. body parts, contextual cues). Ten appropriate photographs were obtained for FE, 13 for TH. Each known face was matched with an unfamiliar face of the same sex, approximate age and physical likeness. The faces were presented in random order. The subject was initially asked whether each face was familiar or not, and then to provide as much information as possible, including the name, about the individuals whose faces they classed as familiar. The test was administered on two separate occasions to each patient and his wife.

Results. Under more stringent conditions FE was still able to identify 8/8 faces of his immediate family as familiar. He correctly named 7/8 of these family members, but was unable to name the last. FE stated that 8/12 relatives' faces were familiar. Of these, he correctly named one, incorrectly named his sister-in-law, and could not name the other six. Most striking of all was FE's overfamiliarization of the faces of strangers, of whom he rated 12/20 as familiar. FE's wife identified 8/8 immediate family members by name, and rated 10/12 relatives as familiar, naming all 10. She had no difficulty identifying 20/20 of the matched strangers' faces as unfamiliar.

Combining the results of this test with the results from the famous face/stranger's face test, FE incorrectly identified 21/30 strangers' faces as being familiar, offering erroneous specific semantic information for five of them (e.g. identified as a doctor, a hospital employee, a dentist or a neighbour). He did not try to identify or place the others.

On the family face recognition test, TH identified all 26/26 family members as familiar and correctly named

Table 4. Identification of personal belongings

Identification test	Patient FE	Patient TH
Personal belongings ^a		
Identified as familiar	15/16	10/10
Identified as subject's own	12/16	10/10
Unfamiliar objects		
Identified as unfamiliar	15/16	10/10

^aThe personal belongings for FE included his cap, belt, bible, cup, watch, tie, pen and cufflinks. The personal belongings for TH included his cap, dressing gown, watch, slippers, spectacles and spectacle case, belt, jacket, bible, and blazer. Each of these items was matched with a very similar item that the patient had not seen before.

21/26. He did somewhat better on this part of the test than his wife, who identified 24/26 as familiar and correctly named 20/26. With the matched strangers' faces, TH correctly identified 21/26 as unfamiliar, whereas his wife had no difficulty identifying all 26/26 as unfamiliar.

Experiment 5. Affective response to non-face stimuli

In addition to identifying an affective face processing deficit in Capgras patients, Ellis and Young (1990) pointed out that Capgras patients also tend to suffer from depersonalization–derealization, suggesting a generalized dampening of affective responsiveness. For example, Ellis and Young reported that Capgras patients sometimes described their surroundings as looking strange and unfamiliar. It may be that such a generalized dampening of affective responsiveness also contributes to other DM including the mirror sign, but this too has not been investigated to date.

The patients were assessed to determine whether they experienced a feeling of familiarity in relation to salient personal belongings. In each case this was assessed by presenting the patient with a range of personal belongings judged by his wife to have a strong salience for him, together with a set of unfamiliar items matched for type and general appearance. The patient was asked to say whether the item was familiar or not, and whether each belonged to him or not. The familiar and unfamiliar items were presented in random order. For FE the items were his own cap, belt, bible, cup, watch, tie, pen and cufflinks. The test was administered to FE on two separate occasions. TH was tested in the same way with 10 objects (cap, dressing gown, watch, slippers, spectacles and spectacle case, belt, jacket, bible, and blazer) and 10 matched unfamiliar objects.

Results. The results are presented in Table 4. FE identified 15/16 of his personal belongings as being familiar and correctly identified 12/16 of those objects as his own. He correctly identified 15/16 of the matched objects as unfamiliar. TH identified all 10/10 of his personal belongings as familiar and belonging to him. He also correctly identified all 10/10 of the matched objects as being unfamiliar.

Table 5. Mirror testing with patient TH

Mirror reaching ^a	Identify object	Take object
Mirror in front of subject		
Object viewed over left shoulder	10/10	0/10
Object viewed over right shoulder	10/10	0/10
Mirror on subject's right side	10/10	0/10
Mirror on subject's left side	10/10	0/10

^aObjects shown included an apple, cup, spectacles, fork, candle, scissors, reel of cotton, ball, screwdriver and pen.

Experiment 6. Recognition of objects in reflected space

Both patients were assessed on their ability to identify objects when looking only at the objects' reflections. A mirror drawing apparatus was used, and each object was placed beneath a metal plate and hidden from view. The subject looked into the attached mirror and was required to identify each object solely by looking at the reflected image. The stimuli included a cup, scissors, apple, fork, spool of thread, candle, ball, bottle, screwdriver, and pipe.

Results. Both patients were able to identify all the reflected objects.

Experiment 7. Interpretation of reflected space

To assess patient TH's ability to interpret reflected space, an experiment based on that by Ramachandran *et al.* (1997) was devised. The subject sat in a chair facing a full-length mirror and 10 objects (apple, scissors, fork, cup, screwdriver, spectacles, candle, reel of cotton, rubber ball and pen) were then held up one at a time behind his left or right shoulder. Looking in the mirror, the subject was first asked to identify each object by name, and was then asked to take the object in his own hand.

Results. The results are summarized in Table 5. TH was able to name all of the reflected objects. However, when TH was asked to take the object in his hand, he reached towards the mirror on each occasion, scratching on the mirror surface or attempting to reach into or behind the mirror, instead of correctly reaching behind his shoulder to take the object. This behaviour recurred repeatedly over 20 trials. The experiment was repeated, with the mirror placed on TH's right-hand side and then on his left-hand side, but TH's responses and behaviour towards the mirror remained the same.

When the test was completed, the examiner questioned him about the test. TH sat in the chair facing the mirror, and the examiner stood behind him holding up an apple behind TH's shoulder which was visible in the reflection. TH looked at the reflected image of himself and the examiner.

Examiner: Who is holding the apple?

TH: You are.

Examiner: Where am I standing?

TH: Behind me.

Examiner: Can you take the apple from my hand?

TH: Not unless you [pointing to the examiner's reflection] walk over and hand it to me. [Indicating that the reflected image of the examiner would need to walk towards TH and hand TH the apple].

Then the examiner reached forward and took TH's hand and guided it to the apple, while TH looked at the reflected image. This demonstrated to TH that the apple was behind his shoulder. The examiner then used a different stimulus (a cup) and, again with TH looking in the mirror, asked him to take the object which was held in the examiner's hand behind TH's shoulder. TH then said, 'I could take it if I could get up and walk around this glass', and again TH leaned forward and attempted to reach behind the mirror to take the cup in his own hand.

TH was also questioned about the location of his own reflection:

Examiner: You have told me that when people look in the mirror they see their own reflection.

TH: Yes.

Examiner: When you look in the mirror and see the other person, where is your reflection?

TH: It's behind me. It would have to be. When you look in a mirror, you can see the reflection of everything in front of the mirror.

Examiner: So where is your reflection?

TH: My reflection would be on something behind me, behind my back. I've never seen my reflection and the other person together.

Discussion

We have presented two cases in whom the mirror sign was a stable and persisting symptom signalling the onset of a progressive dementia. Both FE and TH presented as communicative, well-groomed and articulate men, who were independently mobile and self-caring. Both were able to provide their own history, capably answered interview questions, responded appropriately to social cues and displayed a keen sense of humour. The fact that the DM was an early feature in each patient's cognitive decline provided a unique opportunity to investigate the cognitive underpinnings of the mirror sign delusion. Our findings will be discussed with regard to the implications for both current cognitive modelling of normal face processing and for understanding DM.

As noted in the introduction, there has been a strong focus on face processing in the investigation of other types of DM, predominantly the Capgras delusion (Ellis *et al.*, 1997; Hirstein and Ramachandran, 1997). Quite unexpectedly, TH and FE differed dramatically in performance on tests of the earliest stages of face processing, the structural encoding of faces. Whereas TH had no difficulty on tests of unfamiliar

face matching and face gender identification, indicating that the earliest stages of face processing were intact, FE's impaired gender identification and very poor face matching indicated poor structural encoding of faces. Interestingly, notwithstanding these difficulties, FE may have been considered 'not prosopagnosic' by some authors of earlier reports of mirror sign delusion: FE did not report any difficulty recognizing faces, his family were not aware of him having any difficulty with face recognition in daily life, and he was able to identify the examiner who regularly tested him.

In the present study, TH was able to identify personally familiar faces and famous faces, indicating that the route to familiar face recognition was entirely intact. In contrast, FE's ability to identify famous and personally known faces was grossly impaired, although he was much more successful in recognizing as familiar, and in naming, close family members than more distant relatives or famous people. In the Bruce and Young (1986) model, a face is judged to be familiar when the structural description has activated the appropriate face recognition unit (FRU). The use of 'familiarity' in this sense signifies merely having seen a face previously, and is thought to occur without activation of identity-specific semantic information. If, as has been previously suggested, FE's structural encoding was impaired, thereby providing degraded input to the FRU, these degraded inputs were nevertheless adequate to achieve threshold FRU activation for his closest family members [and so, in turn, to generate a sense of familiarity and to activate the person identity nodes (PINs) and names] but they were generally not sufficient to activate the FRUs of other less familiar people. One explanation for such differential activation of FRUs is that FRU activation thresholds may vary according to how often a particular face has been seen, and therefore how well the structural descriptions in the FRU are represented.

A feeling of familiarity, in a different sense, can also result from an arousal (affective) response to the faces of known individuals, as noted in the introduction. A dissociation between cognitive and affective 'familiarity' has been demonstrated in both prosopagnosic and Capgras patients (Bauer, 1984, 1986; Ellis *et al.*, 1997; Hirstein and Ramachandran, 1997). In the Bruce and Young (1986) model of face processing, currently the dominant working model, unfamiliar and familiar faces undergo the same early processing but are then represented in independent parallel pathways. Breen *et al.* (2000a) proposed a modification to that model, incorporating a module for affective response to familiar stimuli, including familiar faces (See Fig. 3). Our model follows that of Bruce and Young (1986) up to the point of the FRUs. For familiar faces, the model then bifurcates, with one pathway leading from the FRU module to the PINs and a second pathway leading from the FRU module to an affective response. As we have suggested above for the FRUs, we also propose that the affective response has differential activation thresholds and responses depending on whether the face is better or less well known. Therefore, the stronger

the emotional relationship with the person, the lower the activation threshold and the stronger the affective response that is likely to be activated to that person's face, so that the strongest affective response might be expected for members of one's immediate family.

FE's most striking face processing deficit was the false identification of strangers' faces as familiar and the attribution of incorrect identities or semantic attributes to them. FE misidentified 70% of unfamiliar faces as familiar when no other contextual cues were present, in striking contrast to his wife's effortless ability to identify all of the strangers' faces as unfamiliar. A possible explanation for FE's false recognition of unfamiliar faces is that, due to degradation in structural encoding, unfamiliar faces caused erroneous activation of the FRUs of known people. FE then uncritically accepted the information as correct, as indicated by his identification, by name, of nine of the strangers' faces as belonging to his own relatives. Degraded structural descriptions leading to incorrect FRU and PIN activation might also occur in the normal face processing system. For example, when faces are viewed under less than optimal lighting conditions. Rapcsak *et al.* (1996, 1999) proposed that in situations of uncertainty in face recognition like this, the frontal lobes have a critical role enabling a normal individual to deduce quickly whether the face belongs to a known person or not. They suggested that the frontal lobes, by monitoring the level of activity in the FRUs and PINs, integrate this information with relevant contextual cues and initiate whatever additional procedures are required to verify a person's identity when there is doubt. If this monitoring and strategic problem solving is disrupted by frontal lobe dysfunction, then sub-optimal information delivered via activation of FRUs and PINs in response to a facial cue might be accepted uncritically, such that the person would be unable to reject accurately an incorrectly activated FRU as 'unfamiliar'.

FE did show evidence of executive dysfunction on testing. Specifically, he demonstrated poor response control on the Stroop Test and poor mental flexibility on the Trails B Test. In contrast, his verbal fluency was in the normal range. On the explanation of Rapcsak *et al.*, FE's frontal dysfunction, right more than left, may underlie his poor ability to evaluate information he receives via the impaired face processing system, thereby allowing him to accept uncritically unfamiliar faces as familiar. However, Rapcsak *et al.* (1999) also suggested that the basic mechanism of false recognition in frontal patients would occur regardless of the stimulus category, so that the false recognition phenomenon should be observed across a range of stimuli. However, FE was capable of discriminating personally familiar from matched unfamiliar items, suggesting that, at least in his case, false recognition may have been face specific, rather than a global phenomenon.

Unlike FE, TH's false recognition of unfamiliar faces in the context of otherwise excellent face processing, cannot be explained by degraded structural encoding. An alternative

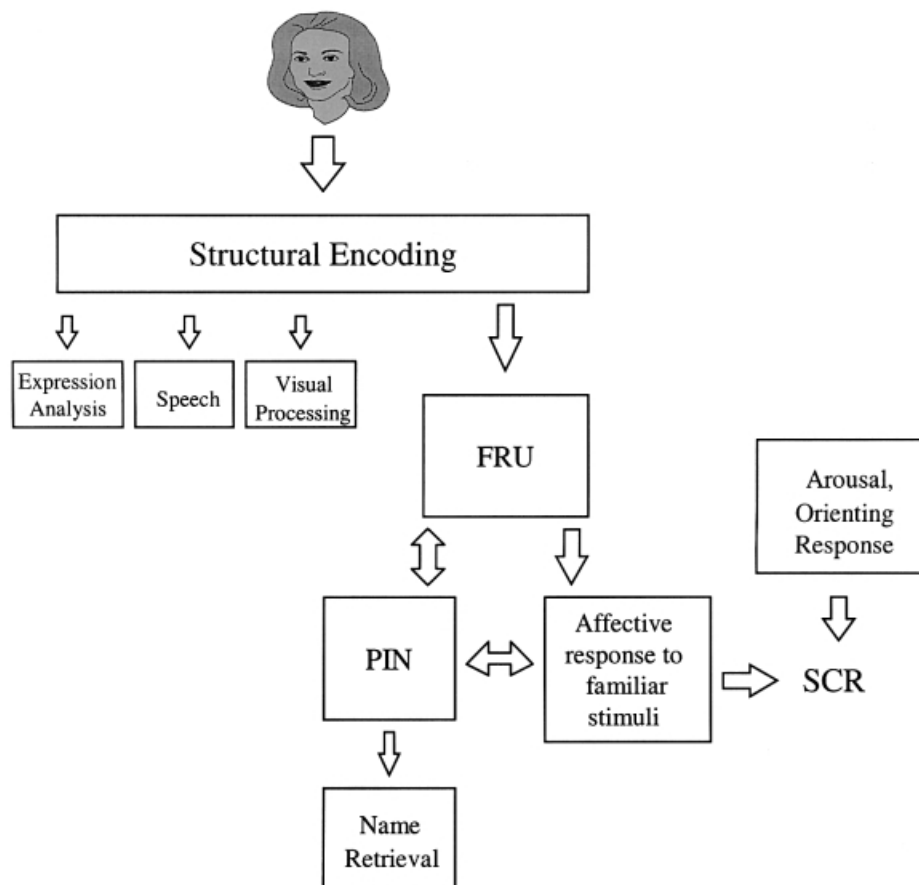


Fig. 3. Breen *et al.*'s model of face processing, based on the Bruce and Young (1986) model. There are two independent pathways from the face recognition units (FRUs): one leading to the person identity node (PIN), and from there a sequential pathway to name retrieval; and a second pathway leading to the affective response to familiar stimuli. The affective response to familiar stimuli is measured by the skin conductance response (SCR). The SCR is also a measure of the arousal or orienting response, which is located in a separate module. (For more details see Breen *et al.*, 2000a).

explanation for this effect in the case of TH is that the problem may result from an inappropriate affective response to faces. We speculate that his false recognition of strangers may be the result of an impairment at the level of the affective response resulting in an inappropriately modulated affective response to all faces, and therefore an erroneous sense of familiarity in response to a stranger's face.

Ellis and Young (1990) have previously proposed that damage to the affective face processing route can result in a reduction or loss of the affective response to known faces, and that this occurs in Capgras patients. Based on the present data, we propose an elaboration of their observation as follows. First, the affective response to faces may become impaired because of degradation in the structural description input to the FRUs resulting in activation of erroneous FRUs and, hence, in an inappropriate affective response to a face wrongly attributed to a familiar person. Second, inappropriate affective responses could arise in spite of good visual face processing because of an impairment in the affective response itself. In addition, whereas Ellis and Young argued that in DM the affective response to known faces may be diminished, our study suggests that the impairment in affective responsiveness may also take the form of excess: that is, inappropriate positive affective responses to faces.

Implications for understanding the mirror sign delusion

The results of the face processing tests demonstrated that FE had a striking face processing deficit, whereas TH did not. Did FE's face processing deficit underlie his self-misidentification in the mirror? It is conceivable that FE's poor face recognition may have resulted in uncertainty as to the identity of the face in the mirror, thereby giving rise to the hypothesis that the person he was viewing was a stranger, and so directly contributing to his DM. Appealing as this interpretation is, it is inconsistent with one fact: despite FE's inability to recognize many faces in photographs, he retained the ability to recognize and discriminate his own face in photographs surprisingly well. This phenomenon has previously been reported in a mirror delusion case (Phillips *et al.*, 1996). It is possible, however, that identification of one's own face in a mirror might differ in important ways from identification of oneself in a photograph. Specifically, identification of a photograph involves recognizing a past representation, whereas mirrored-self recognition involves knowing that the reflection is a concurrent representation of oneself in present time. It is not clear why the latter might be more compromised than the former by the presence of a

face processing impairment; but if that were so, then FE's face processing impairment could play a causal role in his DM. This finding, now formally documented in two mirror sign cases, suggests that self-recognition in a mirror and a photograph are dissociable.

While FE's results suggest that impaired face processing may underlie the mirror sign delusion, TH's results indicate without question that the same DM can develop without a significant face processing deficit. As TH's face processing was almost normal, he was investigated with regard to another factor that we thought might underlie his mirror delusion: the ability to appreciate mirror spatial relations. We demonstrated a striking dissociation between TH's knowledge of mirrors and his ability to interact appropriately with a mirror reflection, a phenomenon previously documented as 'mirror agnosia' (Ramachandran *et al.*, 1997) in patients with neglect. Ramachandran *et al.* proposed two possible interpretations, not necessarily mutually exclusive: the first that mirror agnosia was a specific consequence of neglect; and the second that it was due to a subtle deficit in spatial abilities that occur following parietal lobe lesions. TH had no left visual neglect, but did have striking visuospatial and constructional deficits on neuropsychological testing, and evidence of perfusion defects in the posterior parietal cortices bilaterally, supporting Ramachandran *et al.*'s proposal that mirror agnosia is the result of deficits in spatial abilities.

Although the patients reported by Ramachandran *et al.* (1997), like TH, have a mirror agnosia, they do not have the mirror sign delusion. Similarly, there are many patients reported with severe face processing deficits who do not have the mirror sign delusion. We would also predict that patients who have lesions disrupting the affective route to face processing, resulting in generation of affective responses to completely unfamiliar faces, do not all have the mirror sign delusion. We believe that the perceptual deficits of TH and FE—understanding of spatial relationships especially when reflected, in one case, face processing in the other—contributed to the form of, but do not fully explain, the delusion each experienced. We also believe that the disturbed affective response, more pronounced in FE than in TH, was a significant factor in the formation of the DM. Clearly, however, neither of these fully explains the delusion. In addition to such underlying perceptual and affective impairments, patients who develop and maintain a DM such as the mirror sign must also have a reasoning deficit that allows them to accept an implausible hypothesis. We did not assess FE or TH specifically for a reasoning deficit or for their response to implausible hypotheses in other contexts, but both men demonstrated some impairment in executive function, particularly with regard to response control. Overall, we speculate that the combination of critical factors leading to the development of the mirror sign may include: a perceptual deficit, a disturbed affective response, and a deficit in reasoning, the parameters of which have yet to be defined. At this stage, it remains unclear as to whether the deficit in reasoning is pervasive or whether it pertains only in the

context of highly specific circumstances—namely anomalous perceptual and affective input—that result in a monothematic delusion as opposed to a generally deluded state. We would predict that patients with any one of the deficits, but without the necessary combination, will present with focal cognitive impairments, but not with a DM.

As we have discussed, it is possible that both FE and TH, for different reasons, interpreted the delusional entity in the context of an excessive affective response. Interestingly, most reports of Capgras delusion have described the patient identifying the impostor as evil and sinister, to the extent that there have been cases in which the misidentified individual has been killed by the patient (De Pauw and Szulecka, 1988; Silva *et al.*, 1992, 1994). FE and TH were certainly not paranoid about the presence of the 'person', and both denied feeling threatened by the 'person' (for more detail see Breen *et al.*, 2000b). Neither man contacted the police or raised the alarm regarding the presence of an unknown person in their home. In fact, both men were remarkably unquestioning and non-judgemental about this person who was following them around. If FE and TH experienced feelings of hyperfamiliarity towards their own reflected face, that may have resulted in, or at least contributed to, their experience of the mirror sign 'person' as benign and non-threatening. In contrast, patients with the Capgras delusion have a reduced or absent affective response to familiar faces, and this mismatch between a face that looks familiar but with no accompanying affective response, may be directly contributing to the interpretation of the misidentified person as threatening and evil.

Based on the premise of Ellis and Young (1990) we reasoned that if the delusion arose in the context of depersonalization/derealization, then not only would the misidentified person appear strange to the patient, but so would other things in the environment, including personal possessions. However, FE and TH correctly identified their own belongings and correctly rejected the matched distracters as unfamiliar without difficulty. In addition, when questioned, neither patient reported feeling disconnected from their environment or other people, and denied feeling that their surroundings or other people were strange in any way. Therefore, in the cases of FE and TH, the DM did not arise in the context of generalized feelings of depersonalization/derealization. The results demonstrate that the excessive familiarity that both FE and, to a lesser extent, TH displayed in relation to face processing was a specific rather than a pervasive deficit.

Brain imaging in both of these patients was essentially non-lateralizing. Both were considered to have mild, diffuse atrophy with white matter changes, consistent with age-related changes, and TH had bilateral parietal perfusion defects on SPECT imaging. Six months later, TH was also shown on MRI to have a small cortical infarct in the posterior right frontal lobe. However, as the mirror sign preceded this lesion, this was unlikely to be a causal factor in the formation of his DM. In contrast to the imaging, the neuropsychological profiles of both men clearly indicated gross right hemisphere dysfunction with relative sparing of left hemisphere function, consistent with

the neuropsychological results of two previous case reports of mirror sign patients (Feinberg, 1997; Spangenberg *et al.*, 1998). In addition, both men demonstrated specific right hemisphere deficits that we believe were implicated in the development of their mirror sign delusion; the face processing impairments demonstrated by FE and the impairment in mirror spatial relations demonstrated by TH.

The profile of cognitive deficits identified in these two cases indicates the presence of a combination of cortical and subcortical impairments. These profiles could be interpreted as consistent both with Cummings' (1988, 1997) view that delusional beliefs result from subcortical limbic dysfunction with a secondary modifying role for the cortical hemispheres, and with the view that the right hemisphere is the critical component in the formation of DM. It may be that either a particular combination of lesions or diffuse pathology is required to produce such phenomena which will make identification of their neuroanatomical substrate difficult.

Finally, we would like to suggest a possible interaction between the report and diagnosis of the mirror sign delusion and the phantom boarder delusion. The phantom boarder delusion is the belief that unwelcome guests reside in the home (Flynn *et al.*, 1991). We raise the possibility that what the patient is reporting may actually be the mirror sign delusion. It is very unlikely that the patients themselves will report that the 'person' only appears in reflected surfaces and this may only be ascertained by quizzing perceptive family members.

Acknowledgements

We are extremely grateful to FE and TH and their families for participation in this research. We would also like to thank David Sharpe for referring patient FE, Virginia Arpadí for referring patient TH, and Irina Harris for helpful comments on an earlier draft of this paper.

References

- Alexander MP, Stuss DT, Benson DF. Capgras syndrome: A reduplicative phenomenon. *Neurology* 1979; 29: 334–9.
- Anthony JC, LeResche L, Niaz U, Von Korff MR, Folstein MR. Limits of the 'Mini-Mental State' as a screening test for dementia and delirium among hospital patients. *Psychological Medicine* 1982; 12: 397–408.
- Atwal S, Khan MH. Co-existence of Capgras and its related syndromes in a single patient. *Australian and New Zealand Journal of Psychiatry* 1986; 20: 496–8.
- Baldwin RC, Snowden JS, Mann DMA. Delusional misidentification in association with cortical Lewy Body disease—A case report and overview of possible mechanisms. *International Journal of Geriatric Psychiatry* 1995; 10: 893–8.
- Bauer R. Autonomic recognition of names and faces: a neuropsychological application of the Guilty Knowledge Test. *Neuropsychologia* 1984; 22: 457–69.
- Bauer R. The cognitive psychophysiology of prosopagnosia. In: Ellis H, Jeeves M, Newcombe F, Young A, editors. *Aspects of face processing*. Dordrecht: Martinus Nijhoff, 1986: 253–67.
- Benton AL, Hamsher K deS, Varney NR, Spreen O. *Facial recognition: Stimulus and multiple choice pictures*. New York: Oxford University Press, 1983.
- Bienenfeld D, Brott T. Capgras syndrome following minor head trauma. *Journal of Clinical Psychiatry* 1989; 50: 68–9.
- Bologna SM, Camp CJ. Self-recognition in AD: Evidence of an explicit/implicit dissociation. *Clinical Gerontologist* 1995; 15: 51–4.
- Bologna SM, Camp CJ. Covert versus overt self recognition in late stage Alzheimer's disease. *Journal of the International Neuropsychological Society* 1997; 3: 195–8.
- Bouckoms A, Martuza R, Henderson M. Single case study: Capgras syndrome with subarachnoid hemorrhage. *Journal of Nervous and Mental Disease* 1986; 174: 484–8.
- Breen N, Caine D, Coltheart M. Models of face recognition and delusional misidentification: A critical review. *Cognitive Neuropsychology* 2000a; 17: 55–71.
- Breen N, Caine D, Coltheart M, Hendy J, Roberts C. Towards an understanding of delusions of misidentification. *Mind and Language* 2000b; 15: 74–110.
- Bruce V, Young A. Understanding face recognition. *British Journal of Psychology* 1986; 77: 305–27.
- Burjorjee RN, Al-Adawi S. Delusional misidentification of Capgras: A case report from Oman. *Journal of Nervous and Mental Disease* 1992; 180: 733–4.
- Burns A. The oldest patient with Capgras syndrome? *British Journal of Psychiatry* 1985; 147: 719–20.
- Burns A, Jacoby R, Levy R. Psychiatric phenomena in Alzheimer's disease. II: Disorders of perception. *British Journal of Psychiatry* 1990; 157: 76–81.
- Capgras J, Reboul-Lachaux J. L'illusion des 'sosies' dans un delire systematisé chronique. *Bulletin de la Societé Clinique de Médecine Mentale* 1923; 11: 6–16.
- Cawte J, Tarrant M. Capgras syndrome: Outmoded term for changeling delusions? *Australian and New Zealand Journal of Psychiatry* 1984; 18: 388–90.
- Christodoulou GN. The syndrome of Capgras. *British Journal of Psychiatry* 1977; 130: 556–64.
- Collins MN, Hawthorne ME, Gribbin N, Jacobson R. Capgras syndrome with organic disorders. *Postgraduate Medical Journal* 1990; 66: 1064–7.
- Crichton P, Lewis S. Delusional misidentification, AIDS and the right hemisphere. *British Journal of Psychiatry* 1990; 157: 608–10.
- Cummings JL. Organic delusions: Phenomenology, anatomical correlations and review. *British Journal of Psychiatry* 1985; 146: 184–97.
- Cummings JL. Organic psychoses: Delusional disorders and secondary mania. *Psychiatric Clinics of North America* 1986; 9: 293–311.
- Cummings JL. Organic psychosis. *Psychosomatics* 1988; 29: 16–26.
- Cummings JL. Neuropsychiatric manifestations of right hemisphere lesions. *Brain and Language* 1997; 57: 22–37.
- De Pauw KW, Szulecka TK. Dangerous delusions: Violence and the misidentification syndromes. *British Journal of Psychiatry* 1988; 152: 91–6.
- Deutsch LH, Bylsma FW, Rovner BW, Steele C, Folstein MF. Psychosis and physical aggression in probable Alzheimer's disease. *American Journal of Psychiatry* 1991; 9: 1159–63.
- Edelstyn NMJ, Oyeboode F, Barrett K. Delusional misidentification: a neuropsychological case study in dementia associated with Parkinson's disease. *Neurocase* 1998; 4: 181–8.
- Ellis HD. The role of the right hemisphere in the Capgras delusion. *Psychopathology* 1994; 27: 177–85.
- Ellis HD, Young AW. Accounting for delusional misidentifications. *British Journal of Psychiatry* 1990; 157: 239–48.
- Ellis HD, Young AW, Quayle AH, De Pauw KW. Reduced autonomic responses to faces in Capgras delusion. *Proceedings of the Royal Society, London, Series B* 1997; 264: 1085–92.
- Feinberg TE. Some interesting perturbations of the self in neurology. *Seminars in Neurology* 1997; 17: 129–35.
- Feinberg TE, Shapiro RM. Misidentification-reduplication and the right hemisphere. *Neuropsychiatry, Neuropsychology and Behavioral Neurology* 1989; 2: 39–48.
- Flynn FG, Cummings JL, Gornbein J. Delusions in dementia syndromes: Investigation of behavioral and neuropsychological correlates. *Journal of Neuropsychiatry and Clinical Neurosciences* 1991; 3: 364–70.
- Foley JM, Breslau L. A new syndrome of delusional misidentification. *Annals of Neurology* 1982; 12: 76.
- Folstein MF, Folstein SE, McHugh PR. 'Mini-Mental State'. A practical method for grading the cognitive state of patients for the clinician. *Journal of Psychiatric Research* 1975; 12: 189–98.
- Forstl H, Almeida OP, Iacononi E. Capgras delusion in the elderly: The evidence for a possible organic origin. *International Journal of Geriatric Psychiatry* 1991b; 6: 845–52.
- Forstl H, Burns A, Jacoby R, Levy R. Neuroanatomical correlates of clinical misidentification and misperception in senile dementia of the Alzheimer's type. *Journal of Clinical Psychiatry* 1991a; 52: 268–71.

- Gluckman LK. A case of Capgras syndrome. *Australian and New Zealand Journal of Psychiatry* 1968; 2: 39–43.
- Hayman MA, Abrams R. Capgras syndrome and cerebral dysfunction. *British Journal of Psychiatry* 1977; 130: 68–71.
- Helm-Estabrooks N. TOLA: Test of oral and limb apraxia. Illinois, USA: Riverside Publishing Company, 1992.
- Hirstein W, Ramachandran VS. Capgras syndrome: a novel probe for understanding the neural representation of the identity and familiarity of persons. *Proceedings of the Royal Society, London, Series B* 1997; 264: 437–44.
- Hooper HE. Hooper Visual Organization Test. California: Western Psychological Services, 1957.
- Ivnik RJ, Malec JF, Smith GE, Tangalos EG, Kurland LT. Mayo's older Americans normative studies: WAIS-R norms for ages 56 to 97. *Clinical Neuropsychologist* 1992a; 6 (supplement): 1–30.
- Ivnik RJ, Malec JF, Smith GE, Tangalos EG, Peterson RC, Kokmen E *et al.* Mayo's older Americans normative studies: WMS-R norms for ages 56 to 94. *Clinical Neuropsychologist* 1992b; 6 (supplement): 49–82.
- Ivnik RJ, Malec JF, Smith GE, Tangalos EG, Peterson RC. Neuropsychological test norms above age 55: COWAT, BNT, MAE Token, WRAT-R Reading, AMNART, STROOP, TMT and JLO. *Clinical Neuropsychologist* 1996; 10: 262–78.
- Jenkins MA, Cimino C, Malloy PF, Salloway S, Cohen R, Kohn R *et al.* Neuropsychiatric factors in the illusion of visitors among geriatric patients: A case series. *Journal of Geriatric Psychiatry and Neurology* 1997; 10: 79–87.
- Joseph AB, O'Leary DH, Wheeler HG. Bilateral atrophy of the frontal and temporal lobes in schizophrenic patients with Capgras syndrome: A case-control study using computed tomography. *Journal of Clinical Psychiatry* 1990; 51: 322–5.
- Kaplan E, Goodglass H, Weintraub S. Boston Naming Test. Philadelphia: Lea and Febiger, 1983.
- Kay J, Lesser R, Coltheart M. Psycholinguistic Assessment of Language Processing in Aphasia (PALPA). East Sussex: Lawrence Erlbaum Associates, 1992.
- Kertesz A. Western Aphasia Battery. New York: Grune & Stratton, 1982.
- Kumar V. Capgras syndrome in a patient with dementia. *British Journal of Psychiatry* 1987; 150: 251.
- Leafhead KM, Kopelman MD. Face memory impairment in the Cotard delusion. In: Parkin AJ *et al.*, editors. *Case studies in the neuropsychology of memory*. Hove: Psychology Press, 1997: 165–77.
- Lebert F, Pasquier F, Steinling M, Cabaret M, Caparros-Lefebvre D, Petit H. SPECT data in a case of secondary Capgras delusion. *Psychopathology* 1994; 27: 211–4.
- Lewis SW. Brain imaging in a case of Capgras syndrome. *British Journal of Psychiatry* 1987; 150: 117–21.
- Lipkin B. Capgras syndrome heralding the development of dementia. *British Journal of Psychiatry* 1988; 153: 117–8.
- MacCallum WAG. Capgras symptoms with an organic basis. *British Journal of Psychiatry* 1973; 123: 639–42.
- Mackie J, Ebmeier KP, O'Carroll RE. An MRI, SPECT and neuropsychological study of a patient presenting with Capgras syndrome. *Behavioural Neurology* 1994; 7: 211–5.
- Malec JF, Ivnik RJ, Smith GE, Tangalos EG, Peterson RC, Kokmen E *et al.* Mayo's older Americans normative studies: utility of corrections for age and education for the WAIS-R. *Clinical Neuropsychologist* 1992; 6 (supplement): 31–47.
- Mendez MF. Delusional misidentification of persons in dementia. *British Journal of Psychiatry* 1992; 160: 414–6.
- Mendez MF, Martin RJ, Smyth KA, Whitehouse PJ. Disturbances of person identification in Alzheimer's disease: A retrospective study. *Journal of Nervous and Mental Disease* 1992; 180: 94–6.
- Miller BL, Lesser IM, Boone K, Goldberg M, Hill E, Miller MH *et al.* Brain white-matter lesions and psychosis. *British Journal of Psychiatry* 1989; 155: 73–8.
- Molchan SE, Martinez RA, Lawlor BA, Grafman JH, Sunderland T. Reflections of the self: Atypical misidentification and delusional syndromes in two patients with Alzheimer's disease. *British Journal of Psychiatry* 1990; 157: 605–8.
- Nelson HE. The National Adult Reading Test (NART): test manual. Windsor: NFER-Nelson, 1982.
- O'Connor M, Walbridge M, Sandson T, Alexander M. A neuropsychological analysis of Capgras syndrome. *Neuropsychiatry, Neuropsychology and Behavioral Neurology* 1996; 9: 265–71.
- Pailhere-Martinot ML, Dao-Castellana MH, Masure MC, Pillon B, Martinot JL. Delusional misidentification: A clinical, neuropsychological and brain imaging study. *Psychopathology* 1994; 27: 200–10.
- Phillips ML, Howard R, David AS. 'Mirror, mirror on the wall, who...?': Towards a model of visual self-recognition. *Cognitive Neuropsychiatry* 1996; 1: 153–64.
- Quinn D. The Capgras syndrome: Two case reports and a review. *Canadian Journal of Psychiatry* 1981; 26: 126–9.
- Ramachandran VS, Altschuler EL, Hillyer S. Mirror agnosia. *Proceedings of the Royal Society, London, Series B* 1997; 264: 645–7.
- Rapcsak SZ, Polster MR, Comer JF, Rubens AB. False recognition and misidentification of faces following right hemisphere damage. *Cortex* 1994; 30: 565–83.
- Rapcsak SZ, Polster MR, Glisky ML, Comer JF. False recognition of unfamiliar faces following right hemisphere damage: Neuropsychological and anatomical observations. *Cortex* 1996; 32: 593–611.
- Rapcsak SZ, Reminger SL, Glisky EL, Kaszniak AW, Comer JF. Neuropsychological mechanisms of false facial recognition following frontal lobe damage. *Cognitive Neuropsychology* 1999; 16: 267–92.
- Rajo VI, Caballero L, Iruela LM, Baca E. Capgras syndrome in a blind patient. *American Journal of Psychiatry* 1991; 148: 1271–2.
- Rubin EH, Drevets WC, Burke WJ. The nature of psychotic symptoms in senile dementia of the Alzheimer type. *Journal of Geriatric Psychiatry and Neurology* 1988; 1: 16–20.
- Sanati M, Mojtabai R. Capgras syndrome and the Mignon delusion. *American Journal of Psychiatry* 1992; 149: 709–10.
- Shrager D, Weitzel WD. Prosopagnosia and the Capgras syndrome. *Journal of Clinical Psychiatry* 1979; 40: 313–6.
- Silva JA, Leong GB. Visual-perceptual abnormalities in delusional misidentification. *Canadian Journal of Psychiatry* 1995; 40: 6–8.
- Silva JA, Sharma KK, Leong GB, Weinstock R. Dangerousness of the delusional misidentification of children. *Journal of Forensic Sciences* 1992; 37: 830–8.
- Silva JA, Leong GB, Garza-Trevino ES, Le Grand J, Oliva D, Weinstock R, Bowden CL. A cognitive model of dangerous delusional misidentification syndromes. *Journal of Forensic Sciences* 1994; 39: 1455–67.
- Smyth MG, Dean C. Capgras and Koro. *British Journal of Psychiatry* 1992; 161: 121–3.
- Spangenberg KB, Wagner MT, Bachman DL. Neuropsychological analysis of a case of abrupt onset mirror sign following a hypotensive crisis in a patient with vascular dementia. *Neurocase* 1998; 4: 149–54.
- Stone T, Young AW. Delusions and brain injury: The philosophy and psychology of belief. *Mind and Language* 1997; 12: 327–64.
- Thompson AE, Swan M. Capgras syndrome presenting with violence following heavy drinking. *British Journal of Psychiatry* 1993; 162: 692–4.
- Todd J, Dewhurst K, Wallis G. The syndrome of Capgras. *British Journal of Psychiatry* 1981; 139: 319–27.
- Warrington EK. Recognition Memory Test. Windsor: NFER-Nelson, 1984.
- Waziri R. The Capgras phenomenon: Cerebral dysfunction with psychosis. *Neuropsychobiology* 1978; 4: 353–9.
- Wechsler D. Wechsler Adult Intelligence Scale-Revised. San Antonio: Psychological Corporation, 1981.
- Wechsler D. Wechsler Memory Scale-Revised. San Antonio: Psychological Corporation, 1987.
- Weinstein EA, Kahn RL, Sugarman R. Phenomenon of reduplication. *AMA Archives of Neurology and Psychiatry* 1952; 67: 808–14.
- Wilcox JA. A case of Capgras' phenomenon. *Australian and New Zealand Journal of Psychiatry* 1984; 18: 391–2.
- Wright S, Young AW, Hellawell DJ. Sequential Cotard and Capgras delusions. *British Journal of Clinical Psychology* 1993; 32: 345–9.
- Young AW. Face and mind. New York: Oxford University Press, 1998.
- Young AW, Flude BM, Ellis AW. Delusional misidentification incident in a right hemisphere stroke patient. *Behavioural Neurology* 1991; 4: 81–7.
- Young AW, Robertson IH, Hellawell DJ, DePauw KW, Pentland B. Cotard delusion after brain injury. *Psychological Medicine* 1992; 22: 799–804.
- Young AW, Reid I, Wright S, Hellawell DJ. Face-processing impairments and the Capgras delusion. *British Journal of Psychiatry* 1993; 162: 695–8.

Received on 3 December, 1999; resubmitted on 15 March, 2000; accepted on 29 September, 2000

Appendix

Normative data for the famous face/stranger's face test were collected from 23 healthy males ranging in age from 61 to 87 years who were members of community service clubs (Lions clubs) and senior citizens centres throughout Sydney, New South Wales, Australia. The only selection criterion was that the subjects had lived in Australia for at least the past 10 years.

The 10 famous faces in the famous face/stranger's face test included:

Margaret Thatcher	Robert Menzies
Bob Hawke	Queen Elizabeth
Winston Churchill	Elvis Presley
Marilyn Monroe	John Wayne
John F. Kennedy	Don Bradman

Mean number of famous faces on the famous face/stranger's face test correctly named by 23 Australian male subjects ranging in age from 61 to 90 years

Normative sample	Mean number of famous faces correctly named	Standard deviation
61–70 years ($n = 15$)	8.13	1.4
71–90 years ($n = 8$)	7.75	1.8
Total 61–90 years ($n = 23$)	8.0	1.5

Mirrored-self misidentification: two cases of focal onset dementia

N. Breen, D. Caine and M. Coltheart

Abstract

We present two patients in whom the mirror sign, the inability to recognize one's own reflected image, was a stable and persisting symptom signalling the onset of a progressive dementing illness. Extensive neuropsychological testing was conducted with both patients, with particular emphasis on face processing and the understanding of reflected space. Both patients were also investigated with structural imaging techniques (computed tomography and magnetic resonance imaging). Although the neuroimaging results were not strongly lateralizing for either patient, neuropsychological testing revealed striking right hemisphere dysfunction with relatively intact left hemisphere cognitive function in both patients. Of particular interest was the patients' dissociation on tests of face processing; one patient, FE, had significant face processing deficits while the other patient, TH, had relatively intact face processing. Further testing with TH revealed striking deficits in his ability to interpret reflected space. The results of the face processing tests are discussed in the context of current models of normal face processing, with particular emphasis on the affective component in face recognition. We propose that a combination of cognitive deficits underlie the mirror sign delusion, including perceptual, affective and reasoning impairments, and also discuss the contributions of cortical and subcortical lesions in these two patients and in delusions in general.

Journal

Neurocase 2001; 7: 239–54

Neurocase Reference Number:

O220

Primary diagnosis of interest

Mirrored-self misidentification delusion

Author's designation of case

FE, TE

Key theoretical issue

- The cognitive deficits underlying mirrored-self misidentification

Key words: delusions of misidentification; mirrored-self misidentification; delusions; face processing; affective face recognition; mirror agnosia

Scan, EEG and related measures

FE: CT, MRI

TH: EEG, CT, MRI, SPECT

Standardized assessment

National Adult Reading Test, Wechsler Adult Intelligence Scale-Revised (WAIS-R), Wechsler Memory Scale (WMS-R), Psycholinguistic Assessment of Language Processing in Aphasia Battery (PALPA), Boston Naming Test, Rey Complex Figure Test, Hooper Visual Organisation Test, Trail Making Test, line cancellation, line bisection, Controlled Oral Word Association Test (COWAT), Stroop, Test of Oral and Limb Apraxia (TOLA), Facial Recognition Test

Other assessment

Face matching, face gender identification, famous face recognition, personally familiar face recognition, identification of salient personal belongings, mirror testing

Lesion location

- Right hemisphere

Lesion type

Neurodegenerative (unspecified)

Language

English