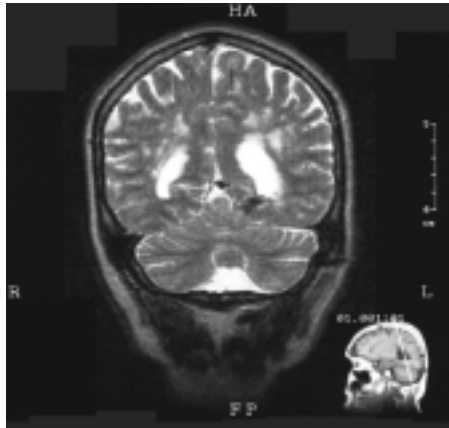


Case report

Fits and strokes

Pankaj Sharma, Tao Wang, Morris J Brown, Anthony H V Schapira

A 41-year-old right-handed engineer was admitted in 1998 with a 10-year history of absence seizures. The seizures were characterised by symptoms of olfactory déjà vu. During the seizures witnesses reported that the patient was able to walk and undertake complex tasks. The seizures, of which the patient had no recollection, lasted for a few minutes and were followed by several hours of lethargy. They would occasionally occur following binge drinking. He had a past history of migraine with visual aura. One of the patient's four siblings one was said to have "multiple sclerosis" but the exact nature of the diagnosis was not clear. His mother had thyroid disease and migraine and his father had diabetes but there was no other family history of note. On examination the patient had vitiligo. His BP was 120/80 mm Hg. He seemed to have brisker tendon reflexes on the left side and foot tapping was marginally diminished on the left. His abstract reasoning was mildly impaired. The remainder of the examination was normal. The following investigations were normal, negative or non-diagnostic: full blood count, liver function, thyroid function, ESR (8 mm/h), syphilis serology, blood lactate, amino acid profile, vitamin B12, folate, lupus anticoagulant, proteins C & S, activated protein C resistance, antibody to thrombin III, autoantibody screen, angiotensin converting enzyme concentrations in serum and cerebrospinal fluid (CSF), visual, brainstem and somatosensory evoked potentials, magnetic resonance imaging (MRI) of the neck vessels, and cardiac echocardiography. An electroencephalogram showed only mild non-specific left temporal disturbances of cerebral activity. CSF examination showed an opening pressure of 16.5 cm of water, glucose 4 mmol/L (peripheral 7 mmol/L), protein 0.96 g/L, lymphocytes $2 \times 10^6/L$, red cells $1 \times 10^6/L$, normal CSF lactate, and no oligoclonal bands. MRI of his head (figure) showed multiple areas of high signal in the white matter bilaterally and one in the pons posteriorly. These areas were confluent periventricularly. 4 months later the patient was readmitted following a sudden onset of unsteadiness of gait, diplopia, nausea, and vertigo. Over the next 48 h he developed slurred speech. On examination he had ataxia with multi-directional and rotatory nystagmus. There was marked cerebellar incoordination in the left arm. A repeat



Magnetic resonance image of brain

MRI head scan showed no substantial change. A muscle biopsy was normal.

We screened the patient's DNA for CADASIL (cerebral autosomal dominant arteriopathy with subcortical infarcts and leukoencephalopathy). A disease-causing mutation C→T⁵⁸³ was found in exon 4.¹ The patient's 67 year old mother also carried the mutation but reported no history of cerebral ischaemic events. When last seen in Feb, 2001, the patient remained stable.

CADASIL is an inherited adult-onset disease due to mutations in the transmembrane receptor of the Notch3 gene (on chromosome 19q12) which either create or destroy a cysteine residue.^{2,3} The acronym CADASIL describes a clinical syndrome characterised most commonly by cerebral ischaemic events (84%), dementia (31%), migraine with aura (22%) and mood disturbances (20%).⁴ 6% of patients with CADASIL have grand mal seizures⁴ but epileptic events as a presenting feature of CADASIL are rare. The mean age of onset of symptoms is 45 years and most patients die by 65 years, as there is no available treatment. MRI of the head shows ischaemic changes with extensive white matter signal abnormalities. Reduplication of the elastic media and granular material in the media of affected arteries is seen in biopsy samples. The cerebral arteriopathy is slowly progressive resulting in thickening and fibrosis of small and medium sized penetrating arteries with consequent narrowing of their lumen. With availability of genetic testing¹ the condition is becoming increasingly recognised. Sporadic cases of CADASIL are likely to be more common than previously thought.⁵ CADASIL is an important cause of ischaemic strokes, which should be considered especially in young patients, and can present with seizures, as illustrated by our patient.

We thank Jean-Claude Baron for helpful comments on this manuscript.

References

- 1 Wang T, Sharma SD, Fox N, Rosser M, Brown MJ, Sharma P. Description of a simple test for CADASIL disease and determination of mutation frequencies in sporadic ischaemic stroke and dementia patients. *J Neurol Neurosurg Psychiatry* 2000; **69**: 652–24.
- 2 Joutel A, Corpechot C, Ducros A, et al. Notch3 mutations in CADASIL, a hereditary adult-onset condition causing stroke and dementia. *Nature* 1996; **383**: 707–10.
- 3 Joutel A, Vahedi K, Corpechot C, et al. Strong clustering and stereotyped nature of Notch3 mutations in CADASIL patients. *Lancet* 1997; **350**: 1511–15.
- 4 Chabriat H, Vahedi K, Iba-Zizen MT, et al. Clinical spectrum of CADASIL: a study of 7 families. *Lancet* 1995; **346**: 934–39.
- 5 Joutel A, Dodick DD, Parisi JE, Cecillion M, Tournier-Lasserre E, Boussier MG. De novo mutation in the Notch3 gene causing CADASIL. *Ann Neurol* 2001; **47**: 388–91.

Lancet 2001; **358**: 120

Clinical Pharmacology Unit, University of Cambridge, Addenbrooke's Hospital, Cambridge CB2 2QQ, UK (P Sharma PhD, T Wang PhD, M J Brown MD); and University Department of Clinical Neurology, The National Hospital for Neurology and Neurosurgery, Queen Square, London (Prof A H V Schapira DSc)

Correspondence to: Dr Pankaj Sharma (E-mail: psharma@hgmp.mrc.ac.uk)