

CASE REPORT

Area-selective stimulus-provoked seizures in post-anoxic coma

S. D. GATZONIS[†], CH. ZOURNAS[†], A. MICHALOPOULOS[‡], S. PRAPAS[‡], S. ARGENTOS[‡] & S. GEROULANOS[†]

[†] *Department of Neurology, Athens Medical School, Eginition Hospital;* [‡] *ICU, Onassis Cardiac Surgery Center, Athens, Greece*

Correspondence to: S. D. Gatzonis, Eginition Hospital, 72 vas. Sofias av., 11528 Athens, Greece.

E-mail: sgatzon@cc.uoa.gr

We describe the case of a 70-year-old patient in whom hemiconvulsive seizures occurred during metabolic derangement, multiple stroke and post-anoxic coma following cardiac arrest.

We employed the methods of clinical and EEG evaluation and CT brain scan.

We found that hemiconvulsive seizures were provoked following a light tactile stimulus in the left-trigeminal area and occasionally a strong tapping in the right-trigeminal area.

We conclude that this type of stimulus-provoked seizure is extremely rare and could be explained by diffuse and severe brain damage.

© 2001 BEA Trading Ltd

Key words: post-anoxic coma; hemiconvulsive seizures; stimulus-sensitive seizures; electroencephalography; encephalopathy.

INTRODUCTION

Stimulus-sensitive myoclonus has been observed in encephalopathic and post-anoxic comatose patients. It is a well-established clinical syndrome associated with a poor prognosis^{1,2}. However, there are stimulus-sensitive epileptic phenomena other than myoclonus which seem to be rare, poorly established clinical entities³.

This paper deals with the case of a patient with spontaneous left-sided clonic seizures experienced after cardiac arrest. Light tactile stimuli on the left-trigeminal area also elicited the same kind of seizure as the spontaneous one.

MATERIALS AND METHODS

A 70-year-old man with a history of diabetes mellitus, chronic atrial fibrillation and chronic renal failure was

operated on to perform coronary artery bypass. During his prolonged stay in the ICU (77 days) the patient developed nosocomial infections, severe sepsis, acute on chronic renal failure and low cardiac output syndrome.

The patient was discharged from the ICU on the 77th POD. Five days later the patient sustained a cardiac arrest due to aspiration and was re-admitted to the ICU. Ten hours after the cardiac arrest, spontaneous hemiconvulsive seizures were noted with a frequency of 4 to 5 seizures per hour. The neurological examination revealed coma, without spontaneous movements and no reactions to painful stimuli. Both pupils were dilated 2-mm with a slight light reflex. No corneal reflex or reaction to tracheal stimulation was observed. Several slow movements of the jaw were noted. There was diffuse hypotonia and muscle atrophy. Tendon reflexes were absent, and no response to the plantar stimulation was elicited bilaterally.

The CT scan revealed: (1) right-cerebellar-hemispheric infarction; (2) smaller left-cerebellar in-

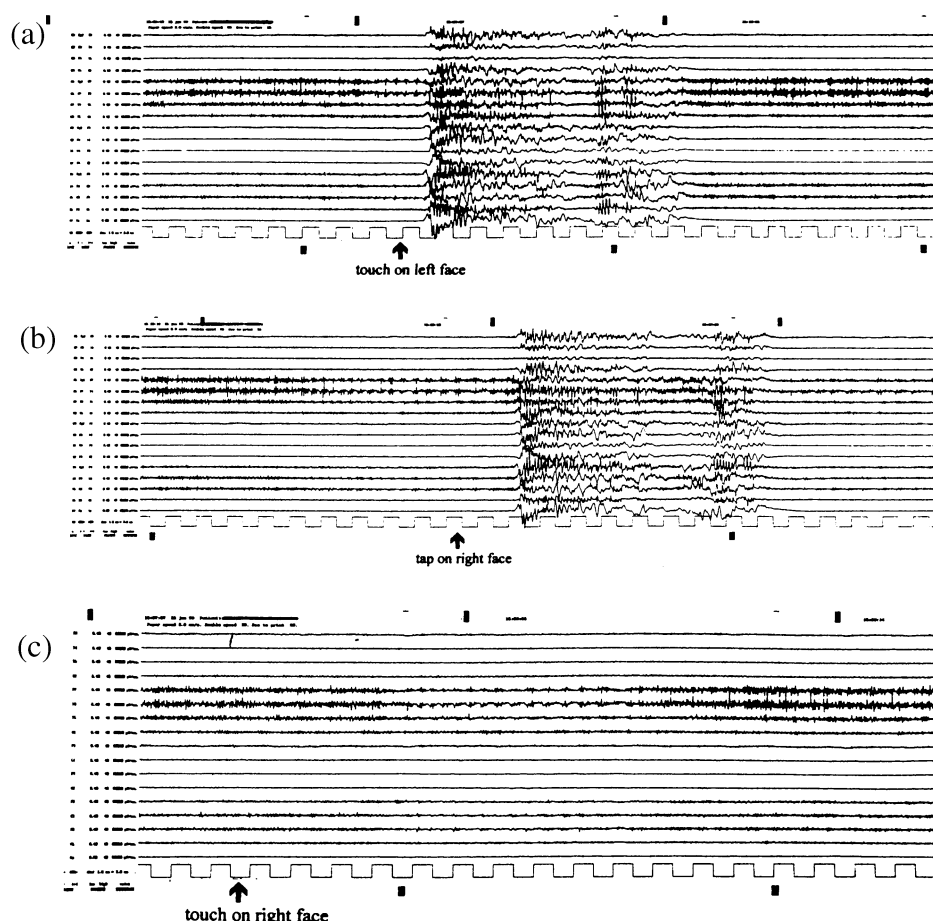


Fig. 1: (a) Seizure following a touch on the left side of the face. (b) Seizure following a tap on the right side of the face. (c) No seizure after a touch on the right side of the face.

farcts; (3) a small infarct (5 mm) in the left pons; (4) deep left-hemisphere infarction, involving the corona radiata, the posterior portion of the external capsule, the posterior limb of the internal capsule and part of the lentiform nucleus; and (5) small focal infarctions in the right-lentiform nucleus, the posterior limb of the internal capsule and part of the ventral aspect of the thalamus (Fig. 2).

During a seizure, the patient displayed simultaneous repetitive clonic jerks of the left side of the face, platysma, tongue, and both the left arm and left leg. The seizures lasted 6–20 seconds. A portable EEG was obtained. The clinical event was accompanied by spike and polyspike bursts and high-voltage sharp-slow-waves in the EEG, recorded bilaterally (Fig. 1). There were prolonged periods of suppression between seizures. While the electrodes were placed, it was noted that a touch on the left-trigeminal area produced a typical seizure similar to the spontaneous seizure.

A systematic application of stimuli was performed as follows:

1. Tactile stimuli were applied to the left-

periorbital area 20, 30, 40, and 60 seconds after seizure cessation, in two series.

2. Five tactile stimuli on the left-hemifacial area no earlier than 60 seconds postictally (periorbital area and cheek).
3. Five tactile and five strong stimuli on the left and right side of the body, respectively (neck, chest (2), arm, leg).
4. Five tactile and six strong stimuli on the right-periorbital area.

The tactile stimulus was performed by a touch from the examiner's finger, without pressure. Strong stimulus was performed by tapping the paramedian finger as strongly as the auscultatory percussion requires.

The results were as follows. In addition to the spontaneous seizures, a tactile stimulus on the left side of the face also elicited a seizure. As shown in Fig. 1, the seizure started 0.5–1.0 seconds after the stimulus to the left-hemifacial area.

Stimuli applied earlier than 30 seconds postictally produced no seizure or discharges. We noted eight

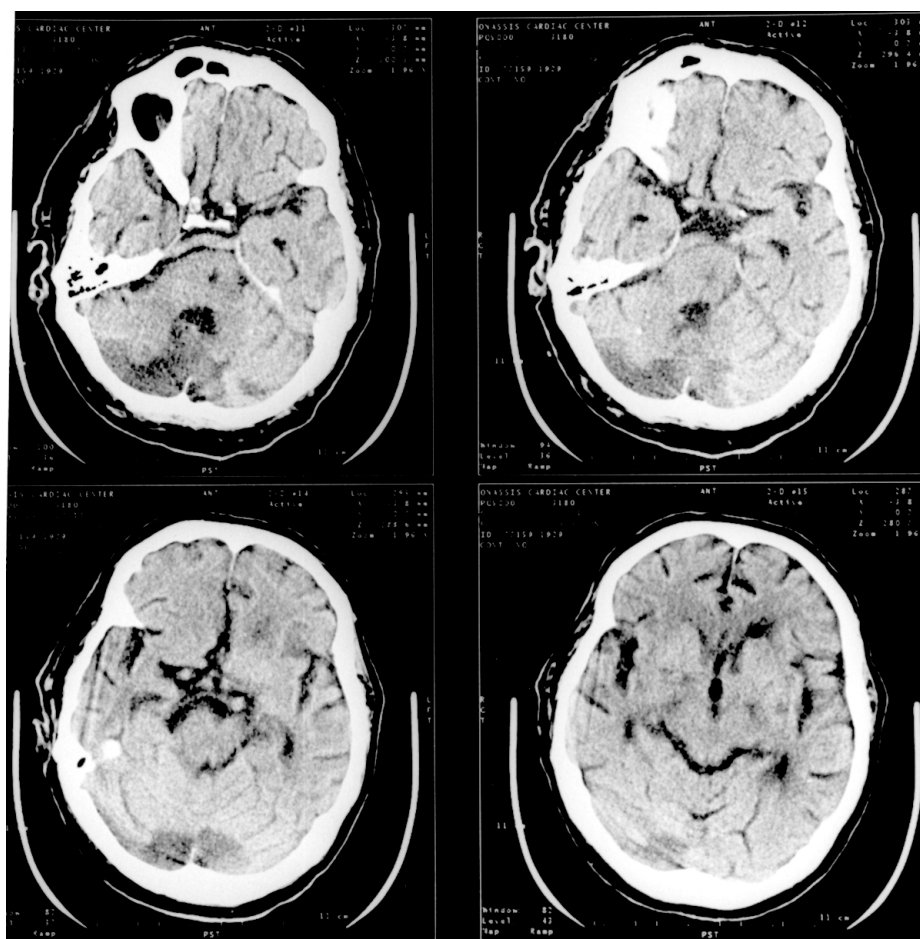


Fig. 2: CT brain scan after cardiac arrest.

seizures following eight light tactile stimuli on the left-periorbital area, applied systematically at least 1 minute after the last seizure (Fig. 1(a)). No seizure was recorded after five light tactile stimuli on the right side of the face (Fig. 1(c)). However, a typical seizure following strong finger tapping over the right frontal area was observed four times in six attempts (Fig. 1(b)). In these cases a time delay of 2–2.5 seconds between stimulus and seizure was noted. Neither auditory nor light stimuli provoked seizures.

An IV infusion of 4 mg of clonazepam resulted in a decrease in the seizure frequency and duration of both spontaneous and provoked seizures.

The patient died 28 hours after cardiac arrest.

DISCUSSION

Somatosensory stimuli as a triggered mechanism of epileptic phenomena are very rare⁴. A number of papers describe a stimulus-sensitive myoclonus during post-anoxic coma. Wijdicks *et al.*¹ referred to 40 patients with post-anoxic myoclonus in whom

touch, tracheal suctioning, loud sound, or placement of central catheters triggered myoclonic jerks. Young *et al.*⁵ reported six patients with post-anoxic myoclonus triggered by touch or nail-bed pressure and one had myoclonus triggered by auditory stimuli. Celesia *et al.*² reported that 11 out of 12 encephalopathic patients with myoclonus had a stimulus-triggered generalized status myoclonus. Recently, Van Cott *et al.*³ reported four patients with stimulus-sensitive seizures following hypoxic-ischemic injury.

As far as we know there is only one case of selective stimulus-sensitive myoclonus in a post-anoxic patient described by Niedermeyer *et al.*⁶ In this case, isolated myoclonic jerks could be elicited by a light touch to the right-trigeminal area. Our case seems to be unique as a somatosensory stimulus in a restrictive skin area, limited to the left trigeminal territory, provoked a hemiconvulsive seizure.

We suggest that a tactile stimulus causes an irritation of somatosensory trigeminal and ascending diffuse projection pathways. Because of the brain damage, concerning, among others, the inhibitory connections of reticular formation, there is no appropriate

inhibition of this ascending signal. This signal seems to be adequate—or appropriately enhanced—to activate the whole cortex or to produce synchronization, or both, resulting in generalized epileptic discharges³.

The epileptic discharges recorded in our case were simultaneously bilateral. The affected parts started to seize simultaneously. These facts imply a synchronous whole-cortex activation, which in turn suggests an underlying mechanism as in generalized seizures.

In spite of the bilateral discharges only the left side of the face and body were seized. A destruction of cortico-pontine and cortico-spinal projections from the left pro-Rolandic and Rolandic areas should be considered. The CT scan findings—findings 3 and 4—could represent such damage. The clinical manifestation of our patient may represent a fragment of generalized tonic-clonic epileptic seizure, the latter modified by brain damage, as Celesia *et al.*² have proposed for post-anoxic myoclonus.

Tactile stimuli applied to the neck and body of our patient did not precipitate any seizure. This could be the result of a bilateral destruction of the ascending somatosensory fibres at a level lower than the pons, but we have no evidence to support this point of view. A meaningful explanation could be the relatively lower 'importance' of tactile stimuli from spinal dermatomes in comparison with the tactile stimuli from the trigeminal area, since the face has a greatly enlarged representation in the thalamus and cortex. Clinical data support this point of view; as in most cases of touch-evoked seizures the effective stimulus is limited to certain regions, particularly on the head⁷. Seizures evoked by hot water appear to be related to the habit of repeatedly pouring hot water over the head and in cases of tactically evoked myoclonic epilepsy of infancy, the face and head are the most usually precipitated areas⁸.

In our patient, only few and strong stimuli such as strong tapping on the right-periorbital area provoked a seizure, with a time delay suggesting that the pathway from the right-trigeminal nucleus to the cortex is not functionally deficient in comparison with the left side. The time delay may represent a spreading of the irritant from the right-trigeminal nucleus to the left brain stem, through polysynaptic connections of reticular formation, ascending to the higher structures through the same pathway as the stimulus from the left-hemifacial area.

Long periods of EEG suppression, lasting from

2–10 minutes were a permanent feature of the EEG recording. Burst suppression patterns in comatose patients have periods of suppression lasting from 2–25 seconds³. Only one patient reported in Van Cott *et al.*³ had suppression periods longer than 25 seconds and it was considered an indication of severe brain injury. In our case, the deep coma, the absence of brain stem reflexes and ensuing death could also suggest that our patient had a severely diffuse brain injury responsible for the long periods of suppression in the EEG.

A post-mortem examination was not performed.

CONCLUSION

In conclusion, widespread hypoxic brain damage was responsible for the abnormal neuronal hyperexcitability or synchronization, or both.

This damage caused, through the ascending diffuse projection system, stimulus-evoked generalized epileptiform discharges, which had a modified clinical expression such as hemiconvulsive seizures. Our case is in agreement with the literature since the seizures in post-anoxic coma carry a poor prognosis.

REFERENCES

1. Wijdicks, E. F. M., Parisi, J. E. and Sharbrough, F. W. Prognostic value of myoclonus status in comatose survivors of cardiac arrest. *Annals of Neurology* 1994; **35**: 239–43.
2. Celesia, G. G., Grig, M. M. and Ross, E. Generalized status myoclonus in acute anoxic and toxic-metabolic encephalopathies. *Archives of Neurology* 1988; **45**: 781–4.
3. Van Cott, A. C., Blatt, I. and Brenner, R. P. Stimulus-sensitive seizures in postanoxic coma. *Epilepsia* 1996; **37**: 868–874.
4. Bickford, R. G. and Klass, D. W. Sensory precipitated and reflex mechanisms. In: *Basic Mechanisms of the Epilepsies* (Eds H. H. Jasper, A. A. J. Ward and A. Pope). Boston, Little Brown & Co, 1969: pp. 543–564.
5. Young, G. B., Gilbert, J. J. and Zochodne, D. W. The significance of myoclonic status epilepticus in postanoxic coma. *Neurology* 1990; **40**: 1843–8.
6. Niedermayer, E., Bauer, G., Burnite, R. and Reichenbach, D. Selective stimulus-sensitive myoclonus in acute cerebral anoxia. *Archives of Neurology* 1977; **34**: 365–368.
7. Gastaut, H. and Tassinari, C. A. Triggering mechanisms in epilepsy. The electroclinical point of view. *Epilepsia* 1966; **7**: 85–138.
8. Deonna, T. Reflex seizures with somatosensory precipitation. In: *Reflex Epilepsies and Reflex Seizures: Advances in Neurology* Vol. 57 (Eds B. G. Zifkin, F. Andermann, A. Beaumanoir and A. J. Rowan). Philadelphia, Lippincott-Raven, 1988: pp. 193–206.