

# TREATMENT OF DEEP CEREBRAL VENOUS THROMBOSIS BY LOCAL INFUSION OF TISSUE PLASMINOGEN ACTIVATOR

Bakhtiar Yamini, M.D., R. Loch Macdonald, M.D., Ph.D., and Jordan Rosenblum, M.D.\*  
*Section of Neurosurgery, Department of Surgery and \*Department of Radiology, Pritzker School of Medicine and The University of Chicago, Chicago, Illinois*

Yamini B, Macdonald RL, Rosenblum J. Treatment of deep cerebral venous thrombosis by local infusion of tissue plasminogen activator. *Surg Neurol* 2001;55:340-6.

## BACKGROUND

Treatment of extensive intracranial venous sinus thrombosis with thrombolytic drugs is described, although the indications for and most efficacious technique for achieving thrombolysis remain uncertain. We report the successful lysis of superficial and deep venous system thrombosis by infusion of recombinant human tissue-type plasminogen activator (rt-PA) into the anterior superior sagittal sinus.

## CASE DESCRIPTION

A 34-year-old man presented with headaches followed by decreased level of consciousness and left hemiplegia. Angiography showed thrombosis of the superior sagittal and both transverse and straight sinuses with extension into the internal cerebral veins. The superior sagittal sinus was catheterized via a transfemoral route and rt-PA, 25 mg, was infused. There was no significant change in the thrombosis. The catheter was left in place and rt-PA was infused at 1 mg/minute for 19 hours. Repeat angiography showed resolution of the thrombosis. The patient was placed on heparin and then coumadin. He recovered completely.

## CONCLUSIONS

This report suggests that superselective infusion of thrombolytics into thrombosed intracranial venous sinuses can lyse intracranial venous sinus thrombosis. The thrombolytic agent must be infused for hours. The apparent successful lysis of clot in the deep venous system when infusion was into the superior sagittal sinus might be related to diffusion of rt-PA throughout the intracranial venous system or to improved venous outflow caused by lysis of clot in superficial dural sinuses. © 2001 by Elsevier Science Inc.

## KEY WORDS

*Dural sinus thrombosis, thrombolytic therapy, plasminogen activator, tissue type, venous thrombosis.*

Although the treatment of cerebral venous thrombosis by superselective infusion of recombinant tissue plasminogen activator (rt-PA) directly into the thrombosed sinuses has been reported in the literature [11,16,18,22], the successful management of deep cerebral venous thrombosis with rt-PA has not been as completely demonstrated [16]. More patients have been described with cerebral venous thrombosis who have been treated with superselective venous infusions of urokinase, although most have had superficial venous sinus thrombosis only [2,5,7,12,14,15,17,19,21,24,26]. We present a patient with extensive dural sinus and cerebral venous thrombosis who was treated with superselective infusion of rt-PA into the superior sagittal sinus. This resulted in resolution of thrombosis in the superficial and deep venous systems and in complete recovery of the patient.

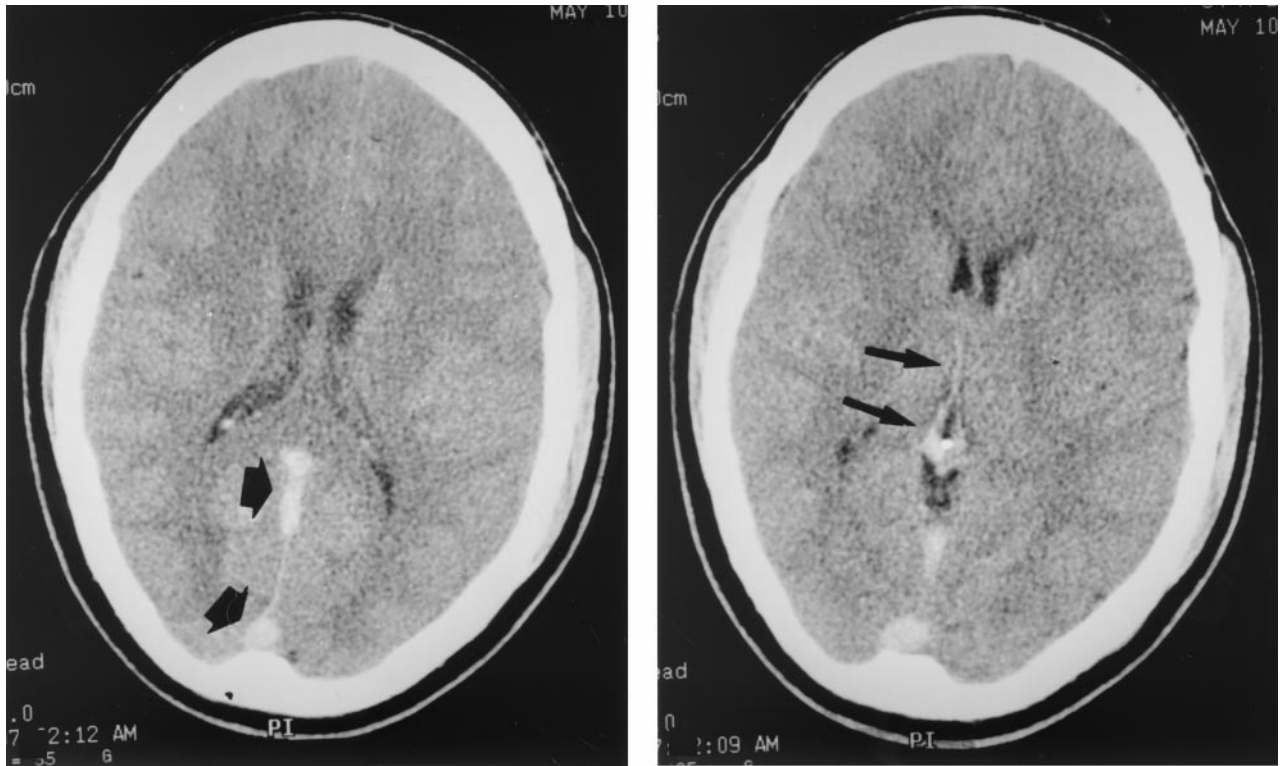
## CASE REPORT

A 34-year-old right-handed man awoke with left-sided periorbital headache. He was seen in the emergency department where a cranial computed tomographic (CT) scan was interpreted as normal. He left against the advice of his physicians before a diagnosis was made but returned to the hospital 12 hours later and 24 hours after the onset of the headache with progressively decreasing level of consciousness, emesis, and left-sided hemiparesis. He had no significant medical history. A brother had suffered a stroke and was found to have transient thrombocytosis and his mother had a history of embolic arterial occlusive disease of the lower extremity.

On examination the patient slept when left alone

Address reprint requests to: Dr. R. Loch Macdonald, Section of Neurosurgery, MC3026, University of Chicago Hospital, 5841 South Maryland Avenue, Chicago, IL 60637.

Received July 12, 2000; accepted February 27, 2001.



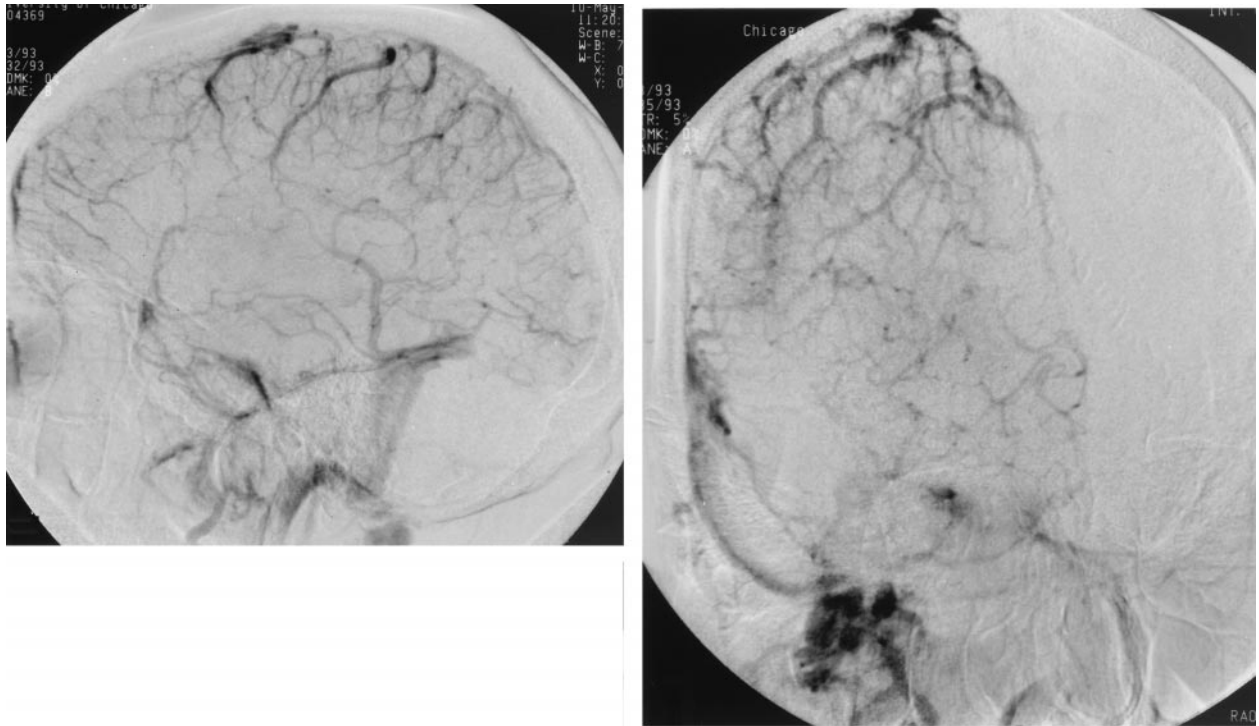
**1** Axial cranial CT scans of the patient on admission to the hospital showing hyperdensity in the superior sagittal sinus and straight sinus (**left**, wide arrows) and linear hyperdensities in the internal cerebral veins (**right**, narrow arrows). The findings are consistent with thrombosis of these structures.

and was confused when awakened. He obeyed commands with the right extremities. There was no papilledema. He had right-sided gaze preference with dense left hemiparesis and hemisensory loss that progressed to hemiplegia within 2 hours. Partial thromboplastin time was slightly less than normal at 17.9 seconds (normal range; 22.7 to 37.1 seconds). Other routine hematological and blood chemistry tests were normal. Platelet count was 424,000.

An unenhanced CT scan of the head showed hyperdensities along the superior sagittal sinus, both transverse sinuses, the straight sinus, the vein of Galen, and both internal cerebral veins (Figure 1). There was no intraparenchymal hypodensity or hemorrhage. The patient was given heparin, 1000 IU per hour by vein, without a loading dose. A cerebral angiogram was obtained immediately and revealed extensive dural sinus and deep cerebral venous system thrombosis as suggested by the CT scan (Figure 2). The decision was then made to attempt clot lysis and, via femoral vein cannulation, a 5 French Weinberg catheter was passed until its tip was in the proximal left sigmoid sinus. A Tracker® 18 catheter (Target Therapeutics, Fremont, CA) was used to selectively catheterize the superior sagittal

sinus, and 25 mg of rt-PA was infused as 2 mg boluses at each centimeter along the thrombosed portion of the superior sagittal sinus. An immediate post-infusion angiogram showed no significant change in the degree of thrombosis. The catheter was advanced again to the junction of the anterior and middle thirds of the superior sagittal sinus and left at that site. It was connected to an infusion pump and rt-PA was infused continuously at 1 mg per hour for 19 hours. The heparin was continued at 1000 IU per hour and prothrombin and partial thromboplastin times and fibrinogen levels were measured every 4 hours. Prothrombin time and fibrinogen levels remained normal. Thrombin time was always greater than 100. The partial thromboplastin time ranged from 36 to 80 seconds.

The following morning an angiogram was performed by transfemoral catheterization of the internal carotid arteries. The venous phase showed almost complete resolution of the thrombosis (Figure 3). The rt-PA was discontinued and all catheters were removed. Over the next several days the patient's neurologic exam improved so that he could be discharged home after 7 days. He was continued on oral coumadin therapy. Further evaluation for hematologic disease including antithrombin III, pro-



**2** Lateral (**left**) and anteroposterior (**right**) venous phase cerebral angiogram of right internal carotid artery injection taken upon admission of the patient to hospital. There is absence of filling of the posterior two thirds of the superior sagittal sinus, both transverse sinuses, the straight sinus, the vein of Galen, and the internal cerebral veins. The findings are consistent with thrombosis of these veins.

tein C and S, and factor V Leiden assay were negative. A work-up for autoimmune disease including a search for anticardiolipin antibodies and lupus anticoagulant was negative. Plasma homocysteine, anti  $\beta_2$  glycoprotein, serology for syphilis, and polymerase chain reaction analysis of factor 2 were all normal. The patient was a professional musician and neurological function recovered such that he was able to resume playing the piano with the same dexterity as before his illness.

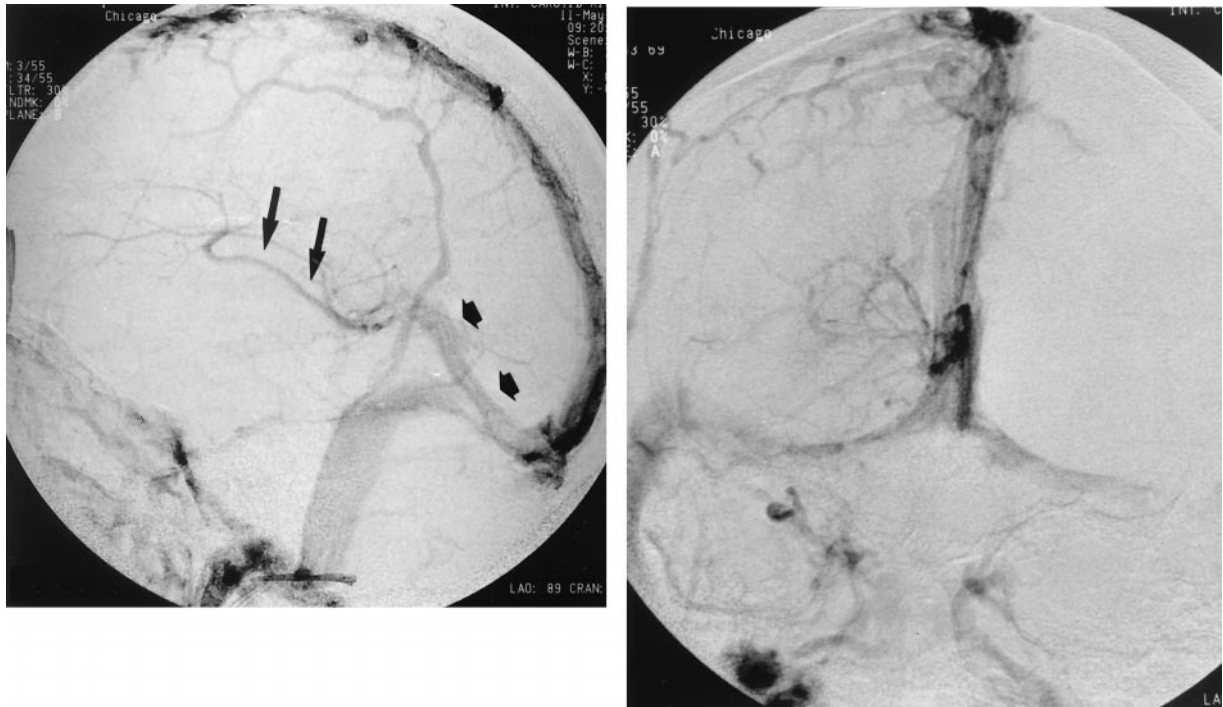
## DISCUSSION

The management of patients with cerebral venous thrombosis is intravenous heparin. We report a patient who presented with altered consciousness and hemiplegia that lasted for 24 hours but from which the patient was able to recover completely. Although such a recovery seems likely to have been brought about by the superselective intrasinus infusion of rt-PA, the controversy regarding optimal management of such patients stems in part from the great variability in the natural history of the disease and the potentially serious risks associated with systemic or superselective fibrinolytic therapies.

The natural history of patients with cerebral ve-

nous thrombosis is highly variable. Early reports noted mortality rates of 30% to 50%, whereas more recent reviews quote a mortality rate of 10% [20]. Several factors may account for this difference, including improved general medical care and management of intracranial hypertension, diagnosis of milder cases because of heightened awareness of the condition and more sensitive diagnostic tests, and possibly more widespread use of intravenous anticoagulation with heparin and coumadin in the acute stage. In survivors, the long-term outlook is good, with 86% of patients having no neurological sequelae, 12% developing second episodes of cerebral venous thrombosis, and 14% having recurrent seizures [20]. Factors that may be associated with worse prognosis include advanced age, coma, presence of hemorrhagic infarction, extensive deep cerebral venous thrombosis, infectious or malignant etiology, increased intracranial pressure, uncontrolled seizures, and associated pulmonary embolism [1-3]. Other series have not confirmed these prognostic factors [2]. The outlook in any given case remains variable and the possibility of good outcome even in comatose patients makes prediction of outcome in individual cases difficult.

There are more than 50 cases of deep cerebral



**3** Lateral (**left**) and anteroposterior (**right**) venous phase cerebral angiogram of right internal carotid artery injection taken approximately 24 hours after the initiation of rt-PA infusion into the anterior portion of the superior sagittal sinus. There is now good filling of the posterior two thirds of the superior sagittal sinus, both transverse sinuses, the straight sinus, the vein of Galen (wide arrows), and the internal cerebral vein (narrow arrows). There has been nearly complete lysis of thrombus in these veins.

venous thrombosis reported in the literature [4,6]. A review of 110 patients with cerebral venous thrombosis found nine cases involving the deep venous system [1]. The clinical presentation of patients with thrombosis of the deep venous system classically includes acute coma, decerebration, hemiparesis, and extrapyramidal hypertonia. When dural sinus thrombosis occurs signs and symptoms of raised intracranial pressure may also be apparent. Crawford et al compared 28 patients with deep cerebral venous thrombosis to 38 patients with superficial dural sinus thrombosis and noted that deep cerebral venous thrombosis was more common in women and more likely to present with acute neurological deterioration and coma [6]. The outcome was worse with death in 36% of patients with deep but only 11% of patients with superficial thrombosis.

Treatment of intracranial venous thrombosis may include surgery to place an intracranial pressure monitor, drain the ventricles, or remove a hematoma. Medical treatment includes anticonvulsants and therapies to reduce intracranial pressure if necessary. Heparin or low molecular weight heparin followed by coumadin may be indicated. Einhäupl et al randomly allocated 20 patients with

sinus venous thrombosis to treatment with placebo ( $n = 10$ ) or intravenous heparin ( $n = 10$ ) [10]. After 3 months, eight patients treated with heparin were normal and two had minor neurological deficits, whereas three patients treated with placebo died, six had severe neurological sequelae, and one recovered fully. This study included a different type of patient from those that are usually treated with superselective intracranial thrombolytics in that patients started treatment on average 1 month after onset of symptoms. Intracranial hemorrhage was present at time of treatment in 30% of heparin-treated and 20% of placebo patients. Patients treated with heparin did not have further intracranial bleeding, whereas two patients who were given placebo did. A double-blind, randomized trial of the low-molecular weight heparin, nadroparin, versus placebo was conducted in 60 patients [8]. There was no significant difference in outcome between groups with poor outcome after 12 weeks in 13% of nadroparin- and 21% of placebo-treated patients. Nadroparin treatment did not cause new intracranial bleeding or increased hemorrhage in 15 patients who had hemorrhagic lesions before treatment. These studies do not show robust beneficial effects of anticoagulation, although the risks seem

small. Combined analysis of these two studies suggested that there was a modest, clinically important but statistically insignificant beneficial effect of anticoagulation [3,8]. As a result, many authorities recommend anticoagulation for most patients with cerebral venous thrombosis.

Fibrinolytic agents administered systemically for cerebral venous thrombosis probably do not produce enough fibrinolysis to lyse intracranial venous clots without producing substantial systemic fibrinolysis that may predispose to dangerous complications such as intracranial hemorrhage [9]. Superselective intracranial administration of urokinase or rt-PA has been reported in selected patients with intracranial venous thrombosis. There are at least 42 reported cases of urokinase treatment [2,5,7,12-15,17,19,21,23-26]. There was no obvious gender predilection with about 50% of patients being female. The average age was 33 (range: newborn to 75 years old) and 15 (36%) presented with varying degrees of altered consciousness. Twelve cases (29%) had thrombus in the straight sinus, vein of Galen, and/or internal cerebral veins. Prolonged infusions of urokinase were undertaken in all but 12 cases with the average duration of treatment being 84 hours (range: 12 hours to 10 days) in the cases with prolonged infusion. The average dose of urokinase was 4.6 million units (range in adult patients: 200,000 to 19 million units). Complications included two intracranial hemorrhages not requiring surgery, one episode of neurological deterioration, one puncture-site infection, two infections, and six systemic bleeding episodes (total: 29%). Outcome was good in 39 cases, with only one death and two patients left with severe disability.

We treated our patient with rt-PA because of limited availability of urokinase. Theoretical advantages of rt-PA over other fibrinolytics are that it may activate fibrinolysis only in the blood clot, that it has a very short half life (6 to 8 minutes), and that it is not antigenic. There are now 24 such cases reported [11,16,18,22]. The average age is 34 years (range: 20 to 55 years old). Thirteen (54%) presented with varying degrees of altered consciousness. Only three cases (12%) had thrombus in the straight sinus and ours is the first case involving deeper veins. Two patients were treated with rt-PA at a single sitting using 3.2 million IU heparin and 35 mg tPA. Prolonged infusions of an average of 84 mg (range: 10 to 300 mg) were used in all other cases with the average duration of treatment of 23 hours (range: 8 to 77 hours). Complications included bleeding at a femoral puncture site in two cases, retroperitoneal hemorrhage requiring transfusion in one, and worsening of intracranial hemorrhage in

two. Seven patients had intracranial hemorrhage before thrombolytic therapy, and this worsened in two (29%). There was no increase in intracranial hemorrhage in 18 patients with intracranial hemorrhage among 40 treated with heparin [8,10].

The indications for superselective infusions of urokinase or rt-PA remain ill-defined. Given the risks of aggravating or precipitating intracranial bleeding, most authorities have limited its use to patients who continue to deteriorate despite medical management, who have substantial neurological deficits, and who probably do not have intracranial hemorrhage [11]. The outcome is better when the thrombosed veins recanalize. This clearly can be achieved more rapidly with superselective urokinase or rt-PA [3,11], but it may be at the expense of an increased risk of intracranial bleeding, although this has only been reported in patients who have hemorrhage before treatment. All published reports are small series or case reports, and it is difficult to draw any conclusions about efficacy, but the overall outcome seems to be better than the natural history in the general group of patients with cerebral venous thrombosis.

We report that selective infusion of rt-PA into the superior sagittal sinus resulted in thrombolysis of clot in the internal cerebral veins. It also is possible that the improved deep venous flow was not due directly to clot lysis but to improved venous outflow secondary to lysis of clot in the area of the torcula. In previous reports of infusion of urokinase for straight sinus and internal cerebral vein thrombosis, patency was achieved in the deep venous system in only 4 of 8 cases [12,15,19]. It was not clear in most cases where the infusions were given. Overall, complete patency was achieved in 32 of 59 patients (54%) treated with urokinase or rt-PA for whom adequate information was available. Our case shows that it may be possible to obtain adequate thrombolysis of the deep venous system even with infusion into superficial sinuses.

## REFERENCES

1. Ameri A, Bousser MG. Cerebral venous thrombosis. *Neurol Clin* 1992;10:87-110.
2. Barnwell SL, Higashida RT, Halbach VV, Dowd CF, Hieshima GB. Direct endovascular thrombolytic therapy for dural sinus thrombosis. *Neurosurgery* 1991; 28:135-42.
3. Bousser MG. Cerebral venous thrombosis. Nothing, heparin, or local thrombolysis? *Stroke* 1999;30:481-3.
4. Brown JIM, Coyne TJ, Hurlbert RJ, Fehlings MG, Ter Brugge KG. Deep cerebral venous system thrombosis: case report. *Neurosurgery* 1993;33:911-3.
5. Chaloupka JC, Mangla S, Huddle DC. Use of mechanical thrombolysis via microballoon percutaneous transluminal angioplasty for the treatment of acute

- dural sinus thrombosis: case presentation and technical report. *Neurosurgery* 1999;45:650-7.
6. Crawford SC, Digre KB, Palmer CA, Bell DA, Osborn AG. Thrombosis of the deep venous drainage of the brain in adults. Analysis of seven cases with review of the literature. *Arch Neurol* 1995;52:1101-8.
  7. D'Alise MD, Fichtel F, Horowitz M. Sagittal sinus thrombosis following minor head injury treated with continuous urokinase infusion. *Surg Neurol* 1998;49:430-5.
  8. de Bruijn SFTM, Stam J, for the Cerebral Venous Sinus Thrombosis Study Group. Randomized, placebo-controlled trial of anticoagulant treatment with low-molecular-weight heparin for cerebral sinus thrombosis. *Stroke* 1999;30:484-8.
  9. DiRocco C, Iannelli A, Leone G, Moschini M, Valori VM. Heparin-urokinase treatment in aseptic dural sinus thrombosis. *Arch Neurol* 1981;38:431-5.
  10. Einhäupl KM, Villringer A, Meister W, Mehraein S, Garner C, Pelkofer M, Haberl RL, Pfister HW, Schmiedek P. Heparin treatment in sinus venous thrombosis. *Lancet* 1991;338:597-600.
  11. Frey JL, Muro GJ, McDougall CG, Dean BL, Jahnke HK. Cerebral venous thrombosis. Combined intrathrombus rtPA and intravenous heparin. *Stroke* 1999;30:489-94.
  12. Gerszten PC, Welch WC, Spearman MP, Jungreis CA, Redner RL. Isolated deep cerebral venous thrombosis treated by direct endovascular thrombolysis. *Surg Neurol* 1997;48:261-6.
  13. Gurley MB, King TS, Tsai FY. Sigmoid sinus thrombosis associated with internal jugular venous occlusion: direct thrombolytic treatment. *J Endovasc Surg* 1996;3:306-14.
  14. Higashida RT, Helmer E, Halbach VV, Hieshima GB. Direct thrombolytic therapy for superior sagittal sinus thrombosis. *Am J Neuroradiol* 1989;10:S4-S6.
  15. Horowitz M, Purdy P, Unwin H, Carstens GI, Greenlee R, Hise J, Kopitnik T, Batjer H, Rollins N, Samson D. Treatment of dural sinus thrombosis using selective catheterization and urokinase. *Ann Neurol* 1995;38:58-67.
  16. Kim SY, Suh JH. Direct endovascular thrombolytic therapy for dural sinus thrombosis: infusion of alteplase. *Am J Neuroradiol* 1997;18:639-45.
  17. Kuether TA, O'Neill O, Nesbit GM, Barnwell SL. Endovascular treatment of traumatic dural sinus thrombosis: case report. *Neurosurgery* 1998;42:1163-7.
  18. Niwa J, Ohyama H, Matumura S, Maeda Y, Shimizu T. Treatment of acute superior sagittal sinus thrombosis by t-PA infusion via venography—direct thrombolytic therapy in the acute phase. *Surg Neurol* 1998;49:425-9.
  19. Philips MF, Bagley LJ, Sinson GP, Raps EC, Galetta SL, Zager EL, Hurst RW. Endovascular thrombolysis for symptomatic cerebral venous thrombosis. *J Neurosurg* 1999;90:65-71.
  20. Preter M, Tzourio C, Ameri A, Boussier MG. Long-term prognosis in cerebral venous thrombosis. Follow-up of 77 patients. *Stroke* 1996;27:243-6.
  21. Rael JR, Orrison WW Jr, Baldwin N, Sell J. Direct thrombolysis of superior sagittal sinus thrombosis with coexisting intracranial hemorrhage. *Am J Neuroradiol* 1997;18:1238-42.
  22. Renowden SA, Oxbury J, Molyneux AJ. Case report: venous sinus thrombosis: the use of thrombolysis. *Clin Radiol* 1997;52:396-9.
  23. Scott JA, Pascuzzi RM, Hall PV, Becker GJ. Treatment of dural sinus thrombosis with local urokinase infusion. Case report. *J Neurosurg* 1988;68:284-7.
  24. Smith TP, Higashida RT, Barnwell SL, Halbach VV, Dowd CF, Fraser KW, Tietelbaum GP, Hieshima GB. Treatment of dural sinus thrombosis by urokinase infusion. *Am J Neuroradiol* 1994;15:801-7.
  25. Spearman MP, Jungreis CA, Wehner JJ, Gerszten PC, Welch WC. Endovascular thrombolysis in deep cerebral venous thrombosis. *Am J Neuroradiol* 1997;18:502-6.
  26. Tsai FY, Higashida RT, Matovich V, Alfieri K. Acute thrombosis of the intracranial dural sinus: direct thrombolytic treatment. *Am J Neuroradiol* 1992;13:1137-41.

---

### COMMENTARY

Yamini et al do an excellent job of concisely describing the current management schemes for superficial and deep cerebral sinus thrombosis. I agree that aggressive management of this entity is often necessary to avoid the sequelae of intraparenchymal hemorrhage or acute and chronic intracranial hypertension. Since urokinase and pro-urokinase are not currently available, Yamini et al do us a service by describing their tPA dosage for clearing the superficial and deep systems.

As an aside, we have found two other useful techniques for the management of sinus thrombosis. The first is the aggressive movement of a curved wire in the sinuses to macerate the clot before and during drug instillation. This technique seems to speed up the lysis, perhaps by exposing more surface area to the drug's effects. The second is the use of the Possis Angiojet, which is a device designed for peripheral use but which can, with some difficulty, be advanced into the transverse and sagittal sinuses to evacuate thrombus.

**Michael Horowitz, M.D.**

*Department of Neurological Surgery  
University of Pittsburgh  
Pittsburgh, Pennsylvania*

Intrasinus thrombolytic therapy can be very effective in the treatment of symptomatic dural sinus thrombosis, as it was in the patient described in this report. Several points merit discussion: (1) The primary treatment is IV heparin, whether or not venous hemorrhage is present. (2) MRI and MR venography are important tools in the diagnosis and management of these patients; the MRV can be used as a baseline for noninvasive follow-up studies. (3) The timing of application of intrasinus thrombolysis is controversial, but I would apply this in patients failing heparin therapy who have at