

Moyamoya Syndrome With Spherocytosis: Effect of Splenectomy on Strokes

Yoichi Tokunaga, MD*,
Shouichi Ohga, MD*, Sachiyo Suita, MD[†],
Toshio Matsushima, MD[‡], and
Toshiro Hara, MD*

A 3-year-old male patient with hereditary spherocytosis who developed moyamoya syndrome, presenting hemiplegia, and slurred speech is reported. Transient ischemic attacks occurred repeatedly with hemolytic crises. Magnetic resonance imaging and angiography revealed bilateral occlusion of the internal carotid and middle cerebral arteries with the formation of moyamoya vessels and multiple infarctions in the basal ganglia. Although splenectomy can increase the risk of stroke, no stroke occurred after splenectomy. On aspirin and dipyridamole therapy the patient has been free of neurologic deficits and progression of the vasculopathy for 5 years. This rare observation suggests that anemic hypoxia more greatly contributes to the progression of moyamoya syndrome than postsplenectomy thrombocytosis or reduced deformability of spherocytes. © 2001 by Elsevier Science Inc. All rights reserved.

Tokunaga Y, Ohga S, Suita S, Matsushima T, Hara T. Moyamoya syndrome with spherocytosis: Effect of splenectomy on strokes. *Pediatr Neurol* 2001;25:75-77.

Introduction

Moyamoya disease is an idiopathic cerebral vasculopathy characterized by bilateral occlusion of the intracranial carotid arteries and proximal portions of anterior and/or middle cerebral arteries associated with a collateral net-

work of telangiectatic vessels ("moyamoya" vessels) in an adjacent area [1]. Ischemic attacks of hemiplegia or seizures constitute the major presentation in childhood, whereas subarachnoid hemorrhage occurs more frequently in adults. Because of its progressive nature, the disease's neurologic outcome is unfavorable without surgical intervention to reconstitute the cerebral circulation [2,3]. To diagnose moyamoya disease, other underlying diseases, including vasculitis, atherosclerosis, and malformations must be excluded. Such a vasculopathy with any underlying diseases is called *moyamoya syndrome*. Hereditary spherocytosis is a common inherited hemolytic anemia caused by the abnormal molecules in red cell membranes, such as spectrin and ankyrin [4]. Cerebrovascular accidents are major complications of sickle cell disease, accompanied by narrowing and occlusion of the internal carotid arteries [5]. On the other hand, only one patient with hereditary spherocytosis and moyamoya disease or moyamoya syndrome has been reported so far [6].

A 3 year-old male with hereditary spherocytosis who developed stage 2 moyamoya syndrome is presented. After successful splenectomy, the transient ischemic attacks disappeared with no progression of the vasculopathy. The potential role of spherocytic anemia in the pathophysiology of moyamoya syndrome is also discussed.

Case Report

A 37-month-old Asian male was hospitalized with transient hemiplegia. This patient had no family history of consanguinity or cerebrovascular accidents. His father had undergone splenectomy for hereditary spherocytosis. He was born to a healthy mother via a full-term delivery. Phototherapy was initiated for neonatal jaundice. On day 5 after birth, the patient was diagnosed with hereditary spherocytosis from the findings of microspherocytic anemia (Hb 9.8 g/dL), reticulocytosis (6.7%), and increased osmotic fragility of red cells. The hemoglobin concentration was around 6.5 g/dL until he was 2 years old. Hemolytic crises repeatedly occurred with infections. At 35 months of age, left hemiparesis, lasting 15 minutes, occurred. Recurrent episodes of hemiplegia and slurred speech made hospitalization necessary.

On admission, physical examination revealed a pale icteric male of 92 cm in height (30th percentile) and 14 kg in weight (46th percentile). His pulse rate was 120 beats/minute, and his blood pressure was 108/64 mm Hg. Auscultation revealed normal respiratory sounds and a functional heart murmur. The liver was palpated 4 cm, and the spleen was palpable 8 cm below the costal margin. No neurologic abnormality was observed on the examination. The peripheral blood counts revealed leukocytes $6.41 \times 10^9/L$, erythrocytes $1,400 \times 10^9/L$, hemoglobin 3.5 g/dL, hematocrit 11.1%, reticulocytes 7.2%, and a platelet count of $159 \times 10^9/L$. Blood chemistry indicated hemolysis; lactate dehydrogenase 810 IU/L, and indirect bilirubin 4.0 mg/dL. The protein C (47%) and protein

From the Departments of *Pediatrics, [†]Pediatric Surgery, and [‡]Neurosurgery; Graduate School of Medical Sciences; Kyushu University; Fukuoka, Japan.

Communications should be addressed to:
Dr. Ohga; Department of Pediatrics; Faculty of Medicine; Kyushu University; 3-1-1 Maidashi; Higashi-ku; Fukuoka 812-8582; Japan.
Received December 14, 2000; accepted March 19, 2001.

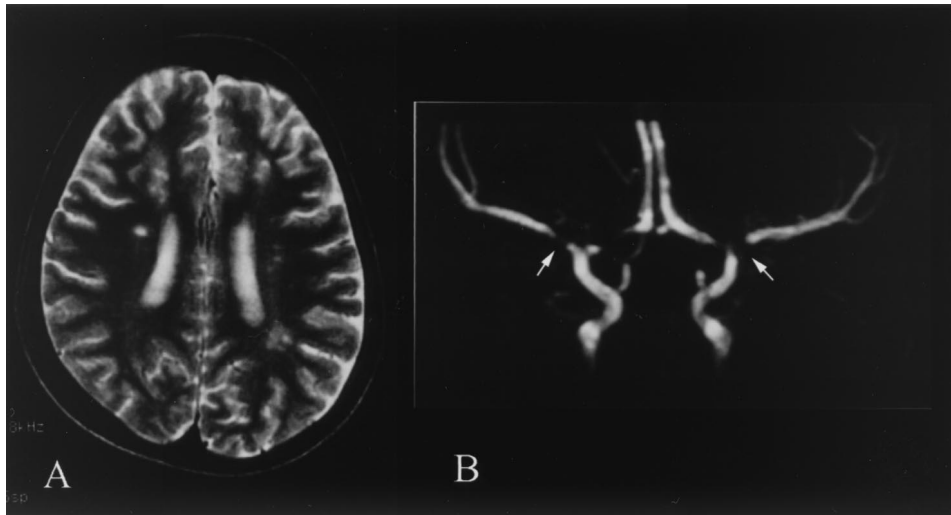


Figure 1. (A) MRI of the brain illustrates multiple small infarctions in the bilateral frontal lobes and left parietal white matter (T_2 -weighted image $TR = 2500$ ms, $TE = 110$ ms). (B) Cranial magnetic resonance angiography demonstrates bilateral narrowing of the supraclinoid portions of the internal carotid arteries and the proximal portions of the anterior and middle cerebral arteries (arrows).

S (51%) activities were subnormal. Echocardiography revealed a mild left ventricular hypertrophy. Electroencephalogram (EEG) revealed high-voltage slow waves in the left hemisphere. Cranial computed tomography (CT) revealed multiple low-density across the right caudate and lenticular nuclei. Magnetic resonance imaging (MRI) disclosed small infarctions in the bilateral frontal and left parietal white matter (Fig 1A). Magnetic resonance angiography depicted bilateral narrowing of the supraclinoid portions of the internal carotid arteries and proximal portions of the anterior and middle cerebral arteries along with the formation of collateral vessels (Fig 1B). After the diagnosis of moyamoya syndrome, ischemic strokes occurred with hemolytic crises (hemoglobin less than 6 g/dL). He underwent splenectomy because transient ischemic attacks were not prevented without frequent transfusions. The hemoglobin level exceeded 13 g/dL, and the platelet count peaked at $1,707 \times 10^9/L$. Cerebral angiography 2 months after the splenectomy illustrated findings compatible with stage 2 moyamoya disease (Fig 2). Single-photon emission computed tomography (SPECT) revealed reduced blood flow in

the right striate body and left posterior temporal lobe. With the administration of oral aspirin and dipyridamole therapy, the patient has been free from neurologic deficits and progression of the vascular lesions for 5 years, as judged on repeated follow-up magnetic resonance angiography.

Discussion

Moyamoya syndrome occurs in patients with brain tumors, vascular malformations, neurofibromatosis, primary or secondary vasculitis after irradiation, infections, and head trauma. Holz et al. [6] reported the first association of hereditary spherocytosis and moyamoya syndrome; for example, a 6-year-old male revealed bilateral occlusion of the supraclinoid internal carotid arteries and

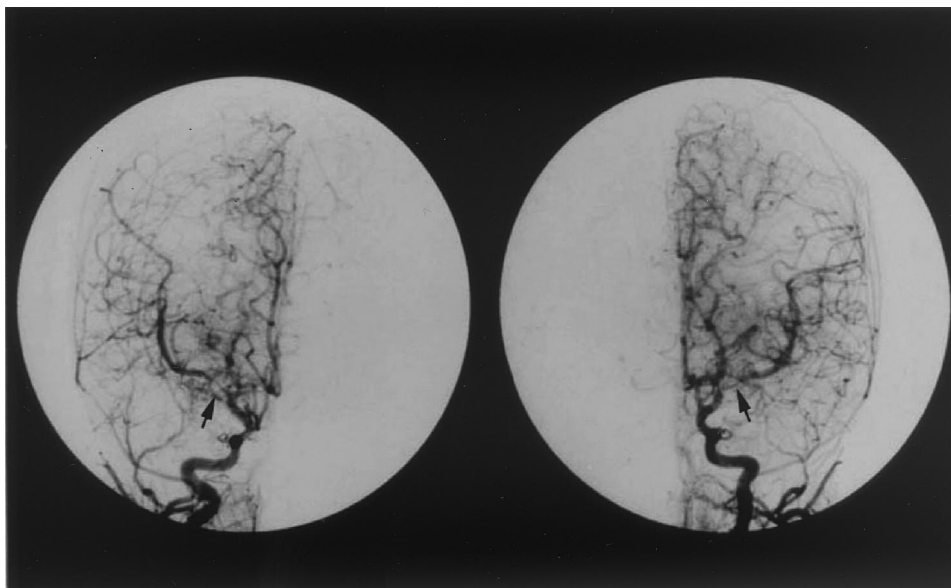


Figure 2. Cerebral angiography illustrates bilateral stenoses at the end of the left internal carotid artery, the proximal portions of the middle cerebral arteries, and the anterior cerebral arteries (arrows), along with the formation of collateral vessels. These findings are consistent with stage 2 moyamoya syndrome.

moyamoya vessels without any other underlying disease. Our patient manifested typical features of moyamoya disease with no conceivable predisposition except for slight decreases in protein C and protein S activities and abnormal red cells. Patients homozygous for abnormal hemoglobins are prone to develop cerebral infarction [5], internal carotid artery narrowing, and occlusion with the moyamoya pattern being the most common arteriographic findings [7,8]. The progressive vasculopathy seems to be a consequence of the flow in the vasa vasorum being obstructed by sickle cells, which leads to ischemia of the internal carotid artery wall, intimal proliferation, and occlusion but not exclusively of direct obstruction of small cerebral vessels by the cells [7,8]. In 1989 van Hilten et al. [9] described two hereditary spherocytosis brothers with cerebral infarction who manifested elevated aggregation and reduced deformability of red cells along with hyperviscosity. They suggested that similar occlusion of the vasa vasorum in sickle cell disease induced cerebral ischemia in hereditary spherocytosis patients. Holz et al. [6] postulated that increased blood flow, caused by anemia, together with less-deformable spherocytes, produces progressive endothelial proliferation, which results in vascular occlusion. Red cells in beta-thalassemia are resistant to osmotic pressure, and some thalassemic patients have been reported to develop moyamoya syndrome [10,11]. In this context, less-deformable red cells may contribute to the development of moyamoya vasculopathy. Cohen et al. [12] reported a 10-year-old male with Fanconi's anemia and moyamoya syndrome, suggesting a Fanconi's anemia-associated congenital vascular anomaly. However, the present patient had no vascular anomalies. The entire course in our patient may raise the possibility that both the abnormal rheology of spherocytes and chronic anemia led to the formation and progression of the cerebral vasculopathy.

Another concern is the clinical indication for splenectomy. Splenectomized patients are liable to have polycythemia, thrombocytosis, and hyperlipidemia, which substantially raise the risks of strokes and embolism [13,14]. Bruguier et al. [15] emphasized the risk of postsplenectomy thrombocytosis for accidental cerebral infarction in a 3-year-old female with hereditary spherocytosis. Thrombocytosis also contributes to cerebral infarction in patients with iron-deficiency anemia [16]. Anemic hypoxia by itself exacerbates cerebral ischemia, especially in infants and older individuals. Exchange transfusions cannot halt the progression of the cerebral vasculopathy in patients with sickle cell anemia [7]. On the other hand, the preventive effect of transfusions on the strokes in our patient may reflect the critical role of anemic hypoxia in the progression of the cerebral vasculopathy. In this context, severe anemia, as well as thrombocytosis after splenectomy, might be predisposing factors for ischemic

cerebrovascular accidents [17]. The postoperative condition of our patient was monitored carefully in the intensive care unit to avoid dehydration, hypotension, and thrombotic accidents. Successful splenectomy on antiplatelet aggregation therapy could imply the greater contribution of anemic hypoxia to the progression of moyamoya disease than that of thrombocytosis or reduced deformability of spherocytes.

The authors thank Drs. Taketsugu Minami, Kenjiro Gondo, Ryutaro Kira, Hiroyuki Torisu, and Yuka Sasaki of the Department of Pediatrics, Graduate School of Medical Sciences, Kyushu University, for helpful discussions.

References

- [1] Suzuki J, Takaku A. Cerebrovascular. "moyamoya" disease. Disease showing abnormal net-like vessels in base of brain. *Arch Neurol* 1969;20:288-99.
- [2] Kurokawa T, Tomita S, Ueda K, et al. Prognosis of occlusive disease of the circle of Willis (Moyamoya disease) in children. *Pediatr Neurol* 1985;1:274-7.
- [3] Matsushima Y, Aoyagi M, Nariai T, Takada Y, Hirokawa K. Long-term intelligence outcome of post-encephalo-duro-arteri-synangiosis in childhood Moyamoya patients. *Clin Neurol Neurosurgery* 1997;99 (Suppl 2):S147-50.
- [4] Gallagher PG, Forget BG. Hematologically important mutations: Spectrin and ankyrin variants in hereditary spherocytosis. *Blood Cells Mol Dis* 1998;24:539-43.
- [5] Ohene-Frempong K, Weiner SJ, Sleeper LA, et al. Cerebrovascular accidents in sickle cell disease: Rates and risk factors. *Blood* 1998;91:288-94.
- [6] Holz A, Woldenberg R, Miller D, Kalina P, Black K, Lane E. Moyamoya disease in a patient with hereditary spherocytosis. *Pediatr Radiol* 1998;28:95-7.
- [7] Grotta JC, Manner C, Pettigrew LC, Yatsu FM. Red blood cell disorders and stroke. *Stroke* 1986;17:811-7.
- [8] Stockman JA, Nigro MA, Mishkin MM, Oski FA. Occlusion of large cerebral vessels in sickle-cell anemia. *N Engl J Med* 1972;287: 846-9.
- [9] van Hilten JJ, Haan J, Wintzen AR, et al. Cerebral infarction in hereditary spherocytosis [letter]. *Stroke* 1989;20:1755-6.
- [10] Peerless SJ. Risk factors of moyamoya disease in Canada and the USA. *Clin Neuro Neurosurg* 1997;99 (Suppl 2):S45-8.
- [11] Mukherjee A. Moyamoya disease and β -thalassemia. *J Assoc Physician India* 1995;43:710-1.
- [12] Cohen N, Berant M, Simon J. Moyamoya and Fanconi's anemia. *Pediatrics* 1980;65:804-5.
- [13] Schilling RF. Spherocytosis, splenectomy, strokes, and heart attacks. *Lancet* 1997;350:1677-8.
- [14] Hayag-Barin JE, Smith RE, Tucker FC Jr. Hereditary spherocytosis, thrombocytosis, and chronic pulmonary emboli: A case report and review of the literature. *Am J Hematol* 1998;57:82-4.
- [15] Bruguier A, Clement MC, Texier P, Ponsot G. Cerebral ischemic accident and hereditary spherocytosis. *Arch Franc Pediatr* 1983;40:653-4.
- [16] Hartfield DS, Lowry NJ, Keene DL, Tager JY. Iron deficiency: A cause of stroke in infants and children. *Pediatr Neurol* 1997;16:50-3.
- [17] Adams RJ, McKie VC, Hsu L, et al. Prevention of a first stroke by transfusions in children with sickle cell anemia and abnormal results on transcranial Doppler ultrasonography. *N Engl J Med* 1998;339:5-11.