

with late-onset familial and sporadic Alzheimer's disease. *Neurology* 1993;43:1467-72.

- 4 Grimaldi LME, Casadei VM, Ferri C, et al. Association of early-onset Alzheimer's disease with an interleukin-1 α gene polymorphism. *Ann Neurol* 2000;47:361-5.
- 5 Combarros O, Sanchez-Guerra M, Llorca J, et al. Polymorphism at codon 129 of the prion protein gene is not associated with sporadic AD. *Neurology*;55:593-5.

Complex musical hallucinosis in a professional musician with a left subcortical haemorrhage

Auditory hallucinosis consists of abnormal acoustic perceptions that occur in the absence of a corresponding acoustic stimulus while the patient is aware of their non-real nature.¹

Musical hallucinosis represents a particular type of acoustic hallucinosis, in which the acoustic perception is formed by music, sounds, or songs. It is frequent in psychiatric diseases and is sometimes reported in sensory neural deafness, but rarely after stroke.^{1,2} We describe a case of musical hallucinosis in a professional musician with a left subcortical haemorrhagic lesion, presumably caused by a cavernous angioma.

A 35 year old, right handed man was referred to our inpatient department in July 1999 7 days after the onset of a slight clumsiness of his right hand followed by complex acoustic perceptions. The patient had attended a symphonic concert where an orchestral transcription of Wagner's "Siegfried" was played: the patient is a connoisseur of music and a composer. When he returned home, about 1 hour later, his musical hallucinosis started. Auditory perceptions were described by the patient as a symphonic piece of music performed by an orchestra with numerous kettledrums and percussion instruments. It was a rather familiar music, unknown to him, but similar to what he had heard during the concert. The theme was played in a minor tonality with frequent use of drums and other percussion instruments interspersed with string instruments. A chorus played by string instruments accompanied the theme. The patient said that the music resembled a piece by the late German romantic authors (for example, Mahler, Bruckner, and Wagner's latest works). The music was initially low in intensity but progressively increased; it was perceived in the middle of his head as if he was listening with headphones on. Conflicting emotions occurred: he felt that it was the most frightening and terrifying music he had ever heard and strongly desired to push it out of his mind but, on the other hand, he was deeply fascinated and said that he would like to compose such an exciting piece.

The patient said that during his musical hallucinosis he was able to speak, watch, and understand television programs and to go about his normal activities. He reported that during the phenomenon his hearing was normal and he could hear everything going on around him, such as the noise outside the house (for example, from the road) and all the usual noise going on in his own house.

The musical hallucinosis lasted about 90 minutes and afterwards the patient fell asleep; he did not have musical hallucinosis during the next day on awakening and it did not recur during the next 20 months.

Seven days after the episode the patient was admitted to our department. On admission a neurological examination evidenced

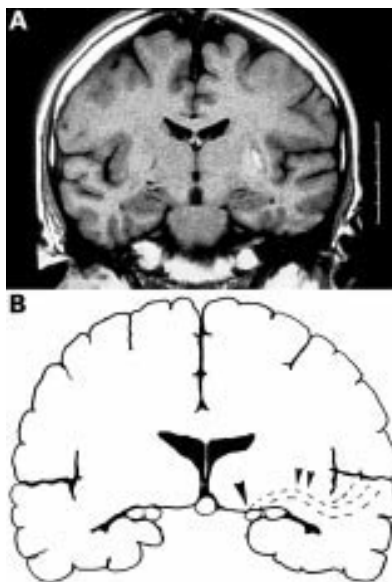


Figure 1 (A) T1 weighted brain MRI and (B) anatomical drawing of the coronal MRI images. An area of altered signal (hyperintense in centre and hypointense at periphery), consistent with a haemorrhagic lesion, involves the left putamen and the external capsule and just touches the acoustic radiation. Comparison between the images outlines the strict relation between the haemorrhagic lesion and the acoustic radiation (double arrows) that runs from the medial geniculate body (single arrow) to the acoustic cortex in the superior temporal gyrus.

only a slight motor impairment of the right hand. His hearing sensation was normal on clinical and instrumental examination. No signs of drug or alcohol misuse were evident. Moreover there was no history of psychiatric disorders.

A cranial CT showed a small hyperdense lesion on the left temporal lobe at subcortical level. Brain MRI (fig 1A) evidenced a haemorrhagic lesion involving the left putamen and the external capsule near the insula. The lesion was located next to the acoustic radiation (fig 1A and B). Cerebral angiography was normal. Three EEG recordings (performed on days 1, 3, and 5 after admission) highlighted only a mild abnormal slow activity at the temporal level, without epileptiform grapho-elements. Audiograms and brain stem auditory evoked potentials were normal.

Transient musical hallucinosis has been described in several situations, such as psychiatric disorders, alcoholism, drug and chemical intoxication, ear and acoustic nerve diseases and, rarely, brain stem lesions mainly involving the tegmentum.^{1,2} Even if musical hallucinosis has been reported in hemispheric lesions² a clear relation with the central acoustic pathway has never been described.

In our patient the prolonged duration of the episode, the preservation of consciousness and memory, and the absence of epileptiform abnormalities on EEG rule out an epileptic genesis of musical hallucinosis. In patients with sensory-neural deafness musical hallucinosis may be determined by an increased cortical excitability due to a deafferentation phenomena¹ or by a spontaneous activation of cerebral areas involved in musical perception.³

In the present case, it might be directly related to the impairment of the acoustic radiation, containing both ascending (excitatory) and descending (inhibitory) fibres. The

inhibitory fibres run from the auditory cortex to lower structures of the central acoustic pathway (medial geniculate nucleus and inferior colliculus) and presumably modulate acoustic perception. The comparison of brain MRI (fig 1A) and of a corresponding anatomical drawing (fig 1B) suggests that the lesion just touches the acoustic radiation between the left medial geniculate body and the auditory cortex. Another explanation of such peculiar findings in our patient may derive from a recent hypothesis regarding musical hallucinosis in acquired deafness⁴: the subcortical lesion may have caused either a disconnection between the primary auditory and the association cortices or an impairment of the "neural networks for the perceptions and imagery of sounds, including the auditory association and the frontal cortex".³ Indeed, the closeness of the lesion to the superior temporal gyrus may interfere with the associative fibres connecting the auditory cortex to the other cerebral areas involved in musical perceptions.

Compared with previously reported cases,¹⁻³ our patient presents several peculiarities. Firstly, the duration of the musical hallucinosis was shorter and the auditory perceptions were heard bilaterally and not lateralised in the opposite ear. Secondly, it occurred in the absence of sensory-neural deafness and might be related to a lesion involving the central acoustic pathway, even at a hemispheric level. This is not in agreement with the notion that complex acoustic hallucinosis is invariably related to damage to the peripheral acoustic pathway or to combined central and peripheral dysfunction.^{1,2} Thirdly, our report greatly supports the role of the dominant hemisphere in musical processing, by contrast with the accepted notion that musical perception is a specific function of the non-dominant hemisphere.^{1,4} We can speculate that the musical training of the patient might have determined the shift of musical representation from the non-dominant to the dominant hemisphere.⁵

Finally, several features of musical hallucinosis in our patient are fascinating. The similarity between the acoustic perceptions and the symphonic music that he had previously heard leads to the hypothesis of an involvement of acoustic memory circuits. The professional experience and the personal sensibility towards symphonic music might both have contributed in the determination of musical hallucinosis influencing the processing of musical sensations.

P CERRATO
D IMPERIALE
M GIRAUDO
C BAIMA
M GRASSO
L LOPIANO
B BERGAMASCO

First Division of Neurology, Department of Neuroscience, University of Torino, Via Cherasco 15, 10126 Torino, Italy

Correspondence to: Dr P Cerrato

- 1 Berrios GE. Musical hallucinations: a historical and clinical study. *Br J Psychiatry* 1990;156:188-94
- 2 Paquier P, et al. Transient musical hallucinosis of central origin: a review and clinical study. *J Neurol Neurosurg Psychiatry* 1992;55:1069-73
- 3 TD Griffiths. Musical hallucinosis in acquired deafness. Phenomenology and brain substrate. *Brain* 2000;123:2065-76
- 4 Kasai K, Asada T, Yumoto M, et al. Evidence for functional abnormality in the right auditory cortex during musical hallucinations. *Lancet* 1999;354:1703-4

5 Bever T, Chiarello RJ. Cerebral dominance in musicians and non-musicians. *Science* 1974; 185:537-9.

Cochlear implantation in a profoundly deaf patient with MELAS syndrome

Cochlear implantation is now an established technology for restoring hearing in profoundly deaf patients. Adults who have lost all useful hearing in both ears are suitable for cochlear implantation if they are profoundly deaf (generally this implies hearing thresholds of 100 dB nHL or worse, across the frequency range 125 to 8000 Hz), with aided hearing thresholds worse than 60 dBA for the frequencies 250 to 4000 Hz and scoring less than 30% in a test of sentence discrimination, using their hearing aids and without lip reading. We describe a patient with MELAS syndrome (mitochondrial myopathy, encephalopathy, lactic acidosis and stroke-like episodes) who became profoundly deaf and who has successfully undergone cochlear implantation and rehabilitation.

A right handed secretary with MELAS syndrome, and a confirmed A to G mutation at nucleotide 3243 in the mitochondrial genome, was referred to the cochlear implant programme of The Royal National Throat, Nose, and Ear Hospital. She had insulin dependent diabetes, congenital cataracts, short stature, leg weakness, fatigue, and hearing loss. She had never had encephalopathy or strokes. Her mother is also diabetic, has glaucoma, and has a lesser degree of deafness, and her sister has been profoundly deaf from adolescence in addition to having severe mental retardation. The patient had begun to experience bilateral hearing loss at the age of 22, with slow deterioration up to the age of 29, by which time she was profoundly deaf in the right ear. By the age of 30 she was also profoundly deaf in the left ear and had developed tinnitus. She had no spontaneous vertigo, but sudden movements could leave her temporarily unsteady. At the age of 31 she was referred for assessment for cochlear implantation. Her ability to communicate with her family was severely restricted because of her deafness. She had developed a modest lip reading ability and was able to lip read her husband to a limited extent, but relied greatly on finger spelling and written information. Her own voice quality had begun to deteriorate. She was found to have no measurable hearing thresholds except for a 250 Hz tone at 105 dB nHL in the right ear. No tests of speech discrimination were possible, as she had virtually no hearing in either ear. Middle ear impedance was normal, and she had normal bilateral vestibular function on caloric testing. Auditory brain stem responses and electrocochleography showed no peaks in response to wide band clicks presented to either ear at 100 dB nHL, consistent with profound sensorineural deafness. Electrical stimulation of the cochlea, using sinusoidal stimuli presented through a transtympanic needle electrode placed through the tympanic membrane onto the promontory of the middle ear,^{1 2} gave rise to a subjective sensation of hearing in both ears, with better performance on gap detection and temporal difference limen tests on the right. A CT scan of the temporal bones was normal.

The findings listed above showed her to be within the criteria for cochlear implantation, and she was implanted in the right ear at the age of 32 with a Nucleus 22 multichannel

implant. All 22 electrodes were inserted into the cochlea and there were no surgical complications.

Subsequent switch on and rehabilitation went well, and the patient has made good progress. She is able to discriminate environmental sounds well, including different bird-songs, and participate in conversation. Verbal communication with her family has improved. There have been no specific problems with the implant and she is able to converse on the telephone using the implant. The patient has resumed full time work in an office. The tinnitus has remained stable, and there have been no vestibular problems. At the 2 year assessment she scored 97% correct on CUNY/UCL sentences (a British adaptation of a sentence discrimination test developed at City University, New York), using her implant and lip reading and 92% correct on BKB (Bamford, Kowal and Bench) sentences (another speech discrimination test) using her implant but without lip reading. Speech production was within normal limits, although the narrow pitch range reflected her slightly flat pattern of intonation.

MELAS syndrome was first described in 1984 and is one of a group of mitochondrial cytopathies, associated with point genetic mutations. In the brain the characteristic abnormalities are basal ganglia calcification and focal lesions of cerebellar and cerebral atrophy, resulting from cellular rather than vascular dysfunction.³ Although it does not feature in the acronym, hearing loss is a common finding in MELAS. Reports of large kindreds and patient series have shown that at least 50% of patients have a moderate or severe sensorineural hearing loss: 21 of 28 patients with MELAS in an Australian series were deaf,⁴ as were eight of 14 patients in a British series.⁵ The phenotypic expression of the mutation is subject to at least three constraints; the percentage of mutant mitochondrial DNA in the target tissue (which has at most a loose correlation with clinical lesions),⁵ the oxidative stress to which different organs or cell populations are exposed, and as yet unidentified collaborating somatic mutations which enhance selective aspects of the syndrome.

The cochlea is an organ exquisitely vulnerable to oxidative stress. The outer hair cells have a precarious, indirect metabolic support from Deiter cells, and the stria vascularis is both metabolically very active and non-mitotic, hence further subject to mutation accumulation. Recently detailed audiological findings have been reported in 18 patients with MELAS, and the authors argued that the hearing loss in their patients was entirely due to cochlear lesions.⁴ There were excellent speech discrimination scores in six of 12 patients with mild to moderate deafness, and excluding severe and profoundly deaf patients with absent responses, there were normal and symmetric brain stem evoked responses in 18 of 20 latencies recorded from 10 patients. Promontory stimulation testing in two patients was normal, and CT and MRI were reported as showing no lesions which could contribute to hearing loss.

Central auditory lesions have been reported as a cause of hearing loss in MELAS. Imaging studies using both CT and MRI have shown that the occipital and parietal lobes and cerebellum are the brain regions most likely to show focal lesions,³ and a perfusion study using ¹²³I-IMP SPECT, and acetazolamide challenge, showed that patients with MELAS typically have hypoperfusion of the occipital and parietal lobes, with

a significant defect in perfusion reserve.⁶ A case report of a patient who died after having had severe seizures and stroke-like events, and who had had multiple imaging studies, showed mild temporal lobe atrophy at necropsy with associated spongy degeneration of the cortex.⁷ All cortical regions were demonstrated radiologically and pathologically to be abnormal in this patient, with the occipital lobe showing the most marked hypoperfusion. She had become deaf 2 years before her marked clinical deterioration.

The patient we report has had no seizures or stroke-like episodes. Her presenting complaint was hearing loss, which progressed over 8 years to profound deafness. Her selection as a candidate for cochlear implantation was straightforward, and she has been successful in adapting to the device and has gained a significant benefit from it. The performance of the patient in the BKB word tests places her in the top 5% of adult performers in our patient series. Another patient with profound deafness and MELAS, who had had seizures and strokes, has recently been reported incidentally in a large series to have been implanted with a successful outcome, but unfortunately details were not provided.⁴

The fact that this patient has gained considerable benefit from her cochlear implant raises the possibility that other patients with MELAS syndrome and profound sensorineural deafness could benefit from this procedure.

D HILL
S WINTERSGILL
L STOTT
B CADGE
J GRAHAM

Cochlear Implant Unit, Royal National Throat, Nose and Ear Hospital, 330-2 Grays Inn Road, London WC1X 8DA, UK

Correspondence to: Mr J Graham

- 1 House WF, Brackmann DE. Electrical promontory testing in differential diagnosis of sensorineural hearing impairment. *Laryngoscope* 1974;84:2163-71.
- 2 Graham JM, Hazell JWP. Electrical stimulation of the human cochlea using a transtympanic electrode. *Br J Audiol* 1977;11:59-62
- 3 Sue CM, Crimmins DS, Soo YS, et al. Neuro-radiological features of six kindreds with MELAS tRNA-Leu A3243G point mutation: implication for pathogenesis. *J Neurol Neurosurg Psychiatry* 1998;65:233-40.
- 4 Sue CM, Lipsitt LJ, Crimmins DS, et al. Cochlear origin of hearing loss in MELAS syndrome. *Ann Neurol* 1998;43:350-9.
- 5 Morgan-Hughes JA, Sweeney MG, Cooper JM, et al. Mitochondrial DNA (mtDNA) diseases: correlation of genotype to phenotype. *Biochim Biophys Acta* 1995;1271:135-140.
- 6 Watanabe Y, Hashikawa K, Moriwaki H, et al. SPELT findings in mitochondrial encephalomyopathy. *J Nucl Med* 1997;39:961-4.
- 7 Clark JM, Marks MP, Adalsteinsson E, et al. MELAS: clinical and pathologic correlations with MRI, xenon/CT, and MR spectroscopy. *Neurology* 1996;46:223-7.

CORRESPONDENCE

Lead poisoning from complementary and alternative medicine in multiple sclerosis

In response to the article *Lead poisoning from complementary and alternative medicine in multiple sclerosis*,¹ we are very concerned that this