

## Post-apoplectic trigeminal trophic syndrome

G Ferrara,† G Argenziano,‡\* G Cicarelli,§ F Cusano,¶ M Delfino‡

†Pathologic Anatomy Service and §Division of Dermatology, 'Gaetano Rummo' General Hospital, Via dell'Angelo 1, I-82100 Benevento, Italy,

‡Departments of Dermatology and §Neurologic Sciences, 'Federico II' University, Via S. Pansini 5, I-80131 Naples, Italy, 'Federico II' University,

Naples, Italy. \*Corresponding author, c/o Clinica Dermatologica, Università 'Federico II', Via S. Pansini 5, 80131 Napoli, Italy, tel. +398 1 746 2412;

fax +398 1 746 2442; E-mail: argenziano@tin.it

### ABSTRACT

Trigeminal trophic syndrome is an uncommon clinical entity in which cutaneous trophic ulceration develops with continuous manipulation of trigeminal dermatomes. Patients spontaneously refer picking, rubbing and/or scratching at the affected areas because of hypo-anaesthesia, paraesthesia and/or pain following damage of the sensory trigeminal fibres or nuclei. We herein describe a patient who developed the syndrome as a sequela of brain stem infarction. Diagnosis by scrape cytology in ruling-out basal cell carcinoma and other ulcerative skin diseases is discussed and the importance of neurological examination in disclosing hemi-anaesthesia of trigeminal dermatome(s) is emphasized.

**Key words:** trigeminal trophic syndrome, brain infarction, hypo-anaesthesia, paraesthesia, cutaneous cytohistopathology

Received: 30 November 1999, accepted 13 October 2000

### Introduction

Neurotrophic ulceration in the trigeminal area<sup>1,2</sup> is a well-recognized, although rare, complication of alcohol injections into the Gasserian ganglion for trigeminal neuralgia therapy.<sup>3</sup> This so-called trigeminal trophic syndrome (TTS) is also encountered in several other neurological diseases, such as neoplasms,<sup>4</sup> infarction,<sup>5</sup> syringobulbia<sup>6</sup> and leprosy.<sup>7</sup>

We report here an example of TTS following occlusion of the posterior inferior cerebellar artery.

### Case report

A 64-year-old Caucasian man presented with multiple facial ulcers that had been present for 18 months. He reported that the cutaneous lesions first appeared 6 months after a cerebellar apoplectic stroke. Since then he had experienced pronounced paraesthesias, mainly consisting of a crawling and tickling sensation strictly limited to the right side of the face and scalp. The man reported picking at and scratching the affected areas.

Dermatological examination evidenced six distinct ulcers (fig. 1), all strictly limited to the right side of the face; the tip of the nose was spared. Each ulcer showed

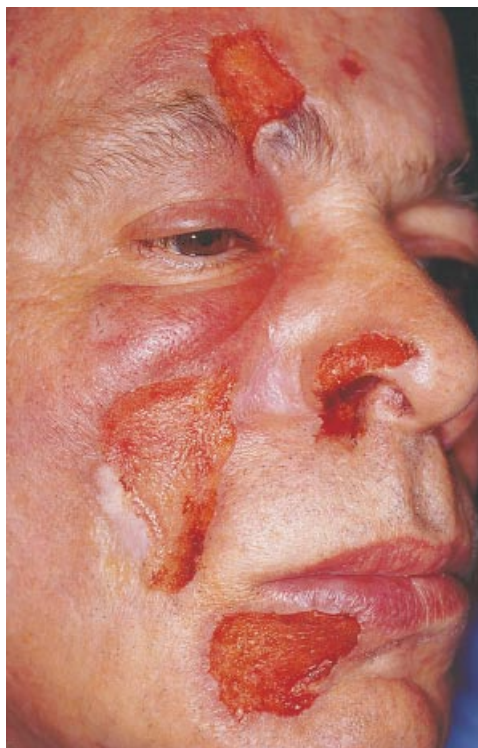well-defined borders with irregular, sometimes bizarre outlines and no nodularity.

A scrape cytology smear and a subsequent punch biopsy fragment were taken at the border of the ulcer located on the right nasolabial fold. The cytopathological picture showed only inflammatory cells, elastic fibres and a few hyperplastic basal cells (fig. 2); histology revealed chronic non-specific ulceration (fig. 3). Neurological examination disclosed loss of the left corneal reflex and anaesthesia to touch, temperature and pinprick in the distribution of V<sub>1</sub>, V<sub>2</sub> and V<sub>3</sub>. Computed tomography examination failed to reveal any area of parenchymal damage outside the cerebellum. A psychiatric consultation gave unremarkable results.

The patient was treated with vitamin B supplements and amitriptyline, and a protective device was applied in order to prevent manipulation during night. However, the clinical improvement was minimal and the patient was lost to follow-up.

### Discussion

TTS, neurotrophic trigeminal ulceration, and ulceration en arc<sup>1</sup> indicate facial ulceration(s) that follows damage to the fibres conveying pain and temperature sensation in the trigeminal area.



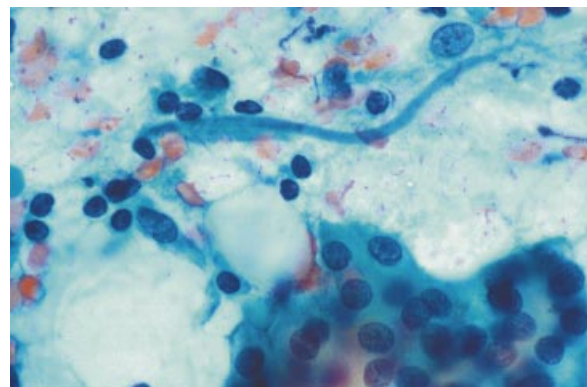
**fig. 1** Multiple monolateral ulcers with minimal inflammatory response.

The first case of TTS was reported by Loveman in 1933 as a 'carcinomatous-like ulcer' following resection of the Gasserian ganglion.<sup>2</sup> A brain infarction, as observed in our patient, may cause a TTS when the vascular damage takes place along the posterior inferior cerebellar artery, which supplies both the cerebellum and the trigeminal nuclei of the brain stem. In such a case, the trophic disease appears to be direct proportional to the degree of residual analgesia in the trigeminal areas.

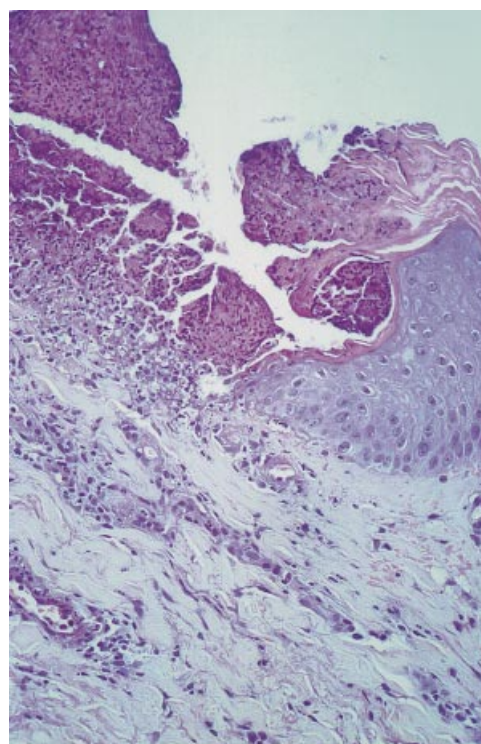
Clinically, the typical picture of TTS is one or several crescentic ulcers that often begin at one side of the nose, sparing the tip. The ulcers are strictly monolateral and painless, but often cause considerable distress; bleeding may be troublesome.

In virtually all cases, patients spontaneously refer paraesthesias (burning, itching, crawling and/or tickling sensations) and repeated manipulations (picking, rubbing and/or scratching) at the affected areas. Therefore, the differential diagnosis of TTS from factitial skin syndromes, such as neurotic excoriations, can be easily made even on the basis of the patient's report alone. Moreover, factitial skin syndromes differ from TTS by showing normal sensitivity, an abnormal personality of the obsessive-compulsive type, and a bilateral (and often symmetrical) distribution of the skin lesions.<sup>8</sup>

The differential diagnosis of TTS must also include basal cell carcinoma, squamous cell carcinoma, lethal midline granuloma, herpetic reactivation and ulceration, syphilis, leishmaniasis, leprosy, trigeminal vasculitis, yaws, blastomycosis, paracoccidioidomycosis, pyoderma gangrenosum, Wegener's granulomatosis.<sup>9</sup>



**fig. 2** Elastic fibres, inflammatory cells and hyperplastic basal cells on scrape cytology (Papanicolaou, original magnification  $\times 400$ ).



**fig. 3** Histological examination showing a non-specific ulceration (haematoxylin and eosin, original magnification  $\times 200$ ).

Cutaneous histopathology of TTS is not specific *per se*, but allows the exclusion of most of the above-mentioned entities. In our opinion, in an adequate clinical context, even a scrape cytology sample is sufficient to rule out both neoplastic and granulomatous skin diseases;<sup>10-12</sup> compared with biopsy histopathology, scrape cytology sampling is less traumatic, less expensive, and a shorter technical procedure.

In order to achieve the final diagnosis of TTS, one must keep in mind the following problems: (i) patients almost invariably report paraesthesias in the trigeminal area; however, paraesthesias

are symptoms, i.e. subjective (and not objective) data; (ii) continuous manipulations at the affected areas are spontaneously referred as well (these are not pathognomonic and may be superimposed on other dermatoses); (iii) in the case of post-apoplectic TTS, neuroradiological examinations may give negative results when the vascular damage of the brain stem is restricted to small areas; and (iv) cutaneous cytohistopathology is non-specific.

For these reasons, in our opinion, the final diagnosis of TTS must be based on neurological examination: the finding of hypo-anaesthesia within the trigeminal dermatome(s) allows evaluation of the neurological impairment, which is the pathogenetic basis of the syndrome.

The therapy of TTS often proves unsatisfactory. Good results are occasionally reported with plastic surgery in which innervated flaps from the unaffected side of the midline are used to cover the defect.<sup>13</sup> In other cases, either cervical sympathectomy<sup>14</sup> or transcutaneous electric stimulation<sup>15</sup> are effective, thus providing evidence for a trophic effect of the normal trigeminal innervation on its dermatomes; the repeated trauma could act as a precipitating factor, as observed in cases of diabetic neuropathy in diabetic foot ulcers.<sup>16</sup>

## References

- 1 Jaeger H. Un type nouveau d'ulcère neurotrophique de l'aile du nez après neurotomie rétrogasserienne. *Dermatologica* 1950; **100**: 201–206.
- 2 Loveman A. An unusual dermatosis following section of the fifth cranial nerve. *Arch Dermatol Syphilol* 1933; **28**: 369–375.
- 3 Shea CR, Scott RA, Tompkins SD. Herpetic trigeminal trophic syndrome. Treatment with acyclovir and sublesional triamcinolone. *Arch Dermatol* 1996; **132**: 613–614.
- 4 Weintraub E, Soltani K, Hekmatpanah J, Lorincz AL. Trigeminal trophic syndrome. *J Am Acad Dermatol* 1982; **6**: 52–57.
- 5 Walton S, Keczkas K. Trigeminal neurotrophic ulceration. A report of four patients. *Clin Exp Dermatol* 1985; **10**: 485–490.
- 6 Karnosh LJ, Scherb RF. Trophic lesions in the distribution of the trigeminal nerve. *JAMA* 1940; **115**: 2144–2148.
- 7 Thomas J, Parimalam S, Selvi GT, et al. Trigeminal trophic syndrome in Hansen's disease. *Int J Lepr Other Mycobact Dis* 1991; **59**: 479–480.
- 8 Woodruff PW, Higgins EM, du Vivier AW, Wessely S. Psychiatric illness in patients referred to a dermatology-psychiatry clinic. *Gen Hosp Psychiatry* 1997; **19**: 29–35.
- 9 Arasi R, McKay M, Grist WJ. Trigeminal trophic syndrome. *Laryngoscope* 1988; **98**: 1330–1333.
- 10 Ravetto C. Citologia della cute e degli annessi cutanei. In: Burlina A, editors. *Trattato Italiano di Medicina di Laboratorio*, Vol. VIII. Piccin, Padova, 1989: 425–434.
- 11 Ruocco V. Attendibilità della diagnosi citologica di basalioma. *G It Dermatol Venereol* 1992; **127**: 23–29.
- 12 Ruocco V, Ruocco E. Tzanck smear, an old test for the new millennium: when and how. *Int J Dermatol* 1999; **38**: 830–834.
- 13 Tatnall FM, Stearns M, Sarkani I. Trigeminal trophic syndrome. *Br J Dermatol* 1985; **113**(Suppl. 29): 86–87.
- 14 McKenzie KG. Observations on the operative treatment of trigeminal neuralgia. *Can Med Assoc* 1933; **29**: 492–496.
- 15 Westerhof W, Bos JD. Trigeminal trophic syndrome: a successful treatment with transcutaneous electrical stimulation. *Br J Dermatol* 1983; **108**: 601–604.
- 16 Grunfeld C. Diabetic foot ulcers: etiology, treatment, and prevention. *Adv Intern Med* 1991; **37**: 103–132.

**Visit the EADV website at: [www.eadv.org](http://www.eadv.org)**