
Eur Neurol 2001;46:101–103

Focal Hyperperfusion on ^{99m}Tc ECD SPECT in a Patient with Epileptic Aphasia

Dae Won Seo, Duk L. Na, Hyanghee Kim, Byung Jun Kim

Department of Neurology, Samsung Medical Center,
Sungkyunkwan University School of Medicine, Seoul, Korea

Aphasia is commonly associated with epilepsy, manifesting as an aura, ictal or postictal event [1, 2]. Although the diagnosis of ictal aphasia is based on EEG in most cases [3, 4], ictal scalp EEG often fails to demonstrate epileptiform discharges [5], especially in nonmotor simple partial seizures such as aphasic seizure [6]. The ictal aphasia can also be detected by SPECT as an ictal hyperperfusion [7]. We report a patient who presented with suddenly aggravated aphasia without epileptiform discharges on scalp EEG but demonstrated focal hyperperfusion on ^{99m}Tc ECD SPECT.

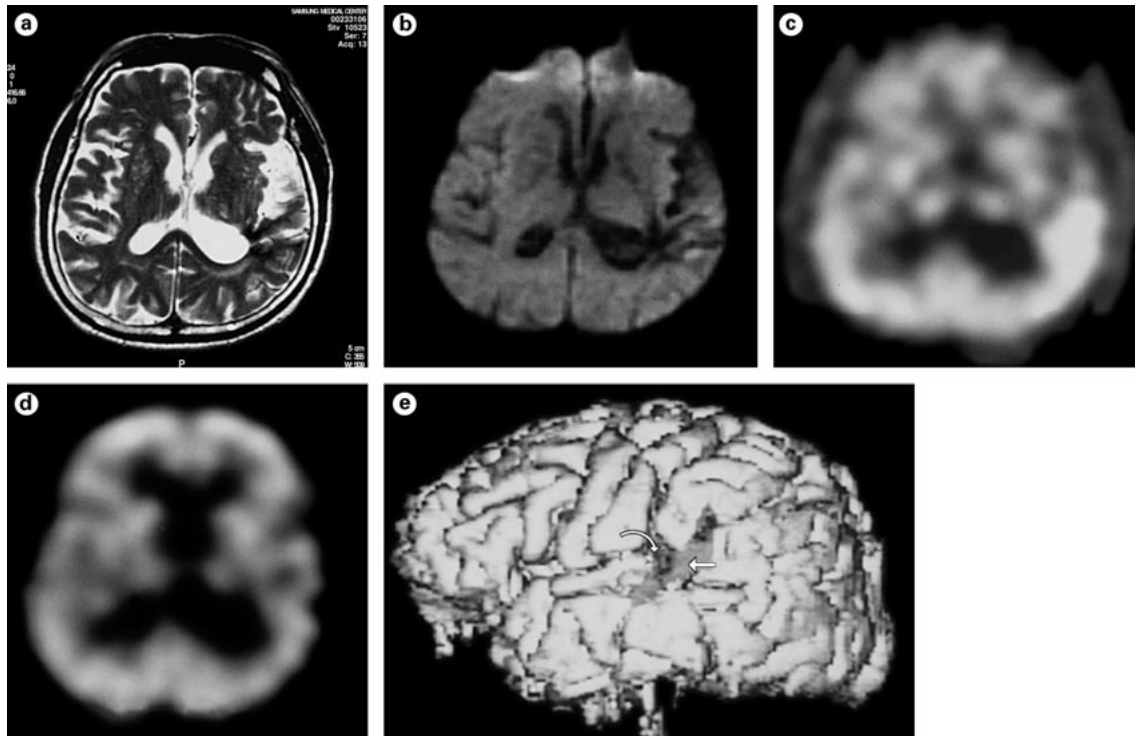


Fig. 1. Axial T2-weighted MRI (**a**) performed 30 h after the onset of Wernicke's aphasia demonstrates an old hemorrhagic lesion (low-signal lesion) in the left posterior temporal region. Diffusion-weighted MRI (**b**) demonstrates no recent infarction. Initial SPECT (**c**) during the aphasic state performed 3 days after onset shows a hyperperfusion in the posterior perisylvian region. On the follow-up SPECT (**d**) performed 2 months after onset, the hyperperfusion had disappeared as the aphasia improved with antiepileptic medication. Subtracted SPECT (initial ictal minus follow-up interictal SPECT) coregistered with MRI (**e**) shows that the hyperperfusion (straight arrow) is located in the posterior perisylvian area including the inferior part of the supragarginal gyrus, and the posterior part of the superior temporal gyrus just posterior to the old hemorrhagic lesion (curved arrow).

Case Report

A 79-year-old right-handed man was admitted because of suddenly aggravated language disturbance developed on the day of admission. Three years before admission, he had had a hypertensive hemorrhage in the left temporal region resulting in Wernicke's aphasia, which improved gradually to the point that he had little difficulty communicating with his family members.

On admission, 10 h after onset, he was alert and commanded fluent speech but he could not understand even one-step simple verbal commands. Other neurologic examinations and workups, including lumbar puncture, were within normal limits. His speech disturbance persisted and did not fluctuate until treatment was started on day 5. On the Korean version of the Western Aphasia Battery performed on the 3rd day, he showed fluent conversational speech consisting of up to 6- or 7-word sentences (score of spontaneous speech, 17/20), but demonstrated severe comprehension deficits (3.9/10) with impaired repetition (1.0/10) and naming (5.4/10), a result consistent with Wernicke's aphasia.

T2-weighted brain MRI performed 30 h after onset revealed a previous hemorrhagic lesion in the left posterior part of the superior temporal gyrus (fig. 1a), but a diffusion-weighted image demon-

strated no new infarction (fig. 1b). Three days after onset, ^{99m}Tc ECD SPECT unexpectedly showed regional hyperperfusion in the posterior perisylvian area (fig. 1c). On the next day, EEG revealed continuous slowing in the left temporal area (fig. 2a). We tried intravenous diazepam of 5 mg twice within 30 min but failed to modify the patient's aphasia. Under the working diagnosis of a focal seizure, however, phenytoin of 300 mg daily was started 5 days after onset.

At discharge 8 days after onset, the patient could understand one- or two-step verbal commands. One month after onset, his family reported that his speech gradually improved to the level at which he had been before admission. On the Western Aphasia Battery repeated 2 months after onset, he scored 17/20 in spontaneous speech, 6.8/10 in auditory comprehension, 3.7/10 in repetition and 7.5/10 in naming, showing improvement, especially in comprehension. Follow-up SPECT performed at that time no longer showed the hyperperfusion observed in the previous scan (fig. 1d). The subtraction of the second from the first SPECT images after coregistering to the patient's MRI using the Analyze program (Mayo Clinic Foundations, Minn., USA) showed the hyperperfused area located just posterior to the old lesion from the previous stroke (fig. 1e). The follow-up EEG showed no interval changes (fig. 2b).

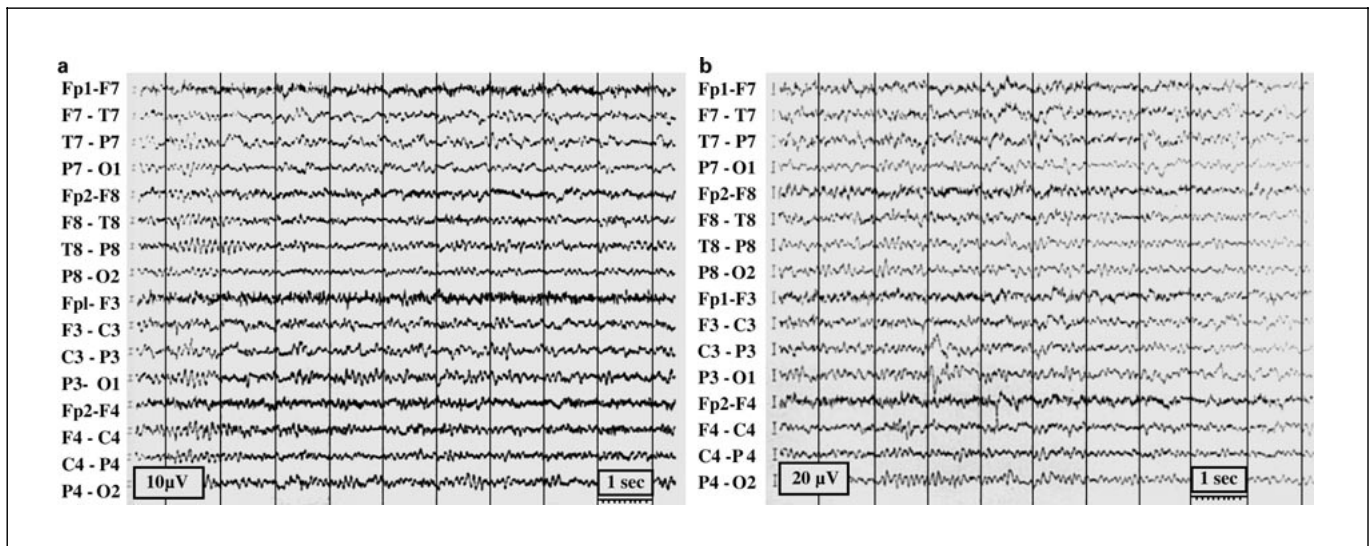


Fig. 2. The initial EEG (**a**) during the epileptic aphasia shows irregular delta waves continuously in the left hemisphere, most evident in the temporal region. On the follow-up EEG (**b**) performed 51 days later, the irregular delta waves are still seen in the same hemisphere.

Discussion

Hyperperfusion on SPECT has been reported in encephalitis, tumor, abscess, subacute infarction and epileptic seizures [8, 9]. Sudden onset, absence of fever and normal CSF findings in our patient make the diagnosis of encephalitis less likely. MRI revealed no structural lesion indicative of tumor or abscess. Therefore, sudden aggravation of aphasia in our patient may be due to either recurrence of stroke or epilepsy. The hyperfixation of SPECT tracers in ischemic stroke depends on tracers used and time period in which SPECT is taken. Previous studies showing hyperperfusion in acute or subacute stroke used ^{99m}Tc hexamethyl propyleneamine oxime or iodine-129 isopropyl iodoamphetamine as a tracer. However, our patient was imaged with ^{99m}Tc ECD and, to our knowledge, ^{99m}Tc ECD SPECT failed to demonstrate hyperperfusion in the acute and even in the subacute stroke. Therefore, it is unlikely that ischemic stroke caused the hyperperfusion SPECT abnormality in our patient. Furthermore, our patient did not demonstrate definite abnormality on diffusion-weighted MRI, which is known to be highly sensitive in detecting acute and hyperacute ischemic changes [10].

Given the clinical features and SPECT abnormality, aggravation of Wernicke's aphasia in our patient was most likely due to an epileptic phenomenon. Admittedly, there are several findings that are against the diagnosis of epilepsy: gradual recovery after antiepileptic treatment, no response to intravenous diazepam and failure to demonstrate epileptiform discharges on EEG. However, 8 of the 12 patients with aphasic status reported by Grimes and Guberman [1] showed gradual improvement over days and weeks like our patient. Earlier studies also suggested that scalp EEG has limitations in diagnosing epileptic aphasia [6]. Therefore, our case could be an example of electronegative aphasic status, the diagnosis of which was made by focal hyperperfusion abnormality on ^{99m}Tc ECD SPECT.

References

- 1 Grimes DA, Guberman A: De novo aphasic status epilepticus. *Epilepsia* 1997;38:945-949.
- 2 Kanemoto K, Janz D: The temporal sequence of aura-sensations in patients with complex focal seizures with particular attention to ictal aphasia. *J Neurol Neurosurg Psychiatry* 1989;52:52-56.
- 3 Primavera A, Bo GP, Venturi S: Aphasic status epilepticus. *Eur Neurol* 1988;28:255-257.
- 4 Wells CR, Labar DR, Solomon GE: Aphasia as the sole manifestation of simple partial status epilepticus. *Epilepsia* 1992;33:84-87.
- 5 Williamson PD, Spencer DD, Spencer SS, Novelly RA, Mattson RH: Complex partial seizures of frontal lobe origin. *Ann Neurol* 1985;18:497-504.
- 6 Devinsky O, Kelley K, Porter RJ, Theodore WH: Clinical and electroencephalographic features of simple partial seizures. *Neurology* 1988;38:1347-1352.
- 7 Lewis DH, Longstreth WT Jr, Wilkus R, Copass M: Hyperemic receptive aphasia on neuroSPECT. *Clin Nucl Med* 1993;18:409-412.
- 8 Launes J, Siren J, Valanne L, Salonen O, Nikkinen P, Seppäläinen AM, Liewendahl K: Unilateral hyperfusion in brain-perfusion SPECT predicts poor prognosis in acute encephalitis. *Neurology* 1997;48:1347-1351.
- 9 Lassen NA, Sperling B: ^{99m}Tc -bicisate reliably images CBF in chronic brain diseases but fails to show reflow hyperemia in subacute stroke: Report of a multicenter trial of 105 cases comparing ^{133}Xe and ^{99m}Tc -bicisate (ECD, neurolite) measured by SPECT on same day. *J Cereb Blood Flow Metab* 1994;14(suppl 1):S44-S48.
- 10 Fisher M, Prichard JW, Warach S: New magnetic resonance techniques for acute ischemic stroke. *JAMA* 1995;274:908-911.

Byung Jun Kim, MD
 Department of Neurology, Samsung Medical Center
 50 ILwon-dong, Kangnam-ku, Seoul 135-710 (Korea)
 Tel. +82 2 3410 3595, Fax +82 2 3410 0052
 E-Mail dwseo@smc.samsung.co.kr

Copyright: S. Karger AG, Basel 2001. Reproduced with the permission of S. Karger AG, Basel. Further reproduction or distribution (electronic or otherwise) is prohibited without permission from the copyright holder.

Copyright: S. Karger AG, Basel 2001. Reproduced with the permission of S. Karger AG, Basel. Further reproduction or distribution (electronic or otherwise) is prohibited without permission from the copyright holder.