



Case report

Acute bilateral cerebellar infarction in the territory of the medial branches of posterior inferior cerebellar arteries

Gunfer Gurer ^{a,*}, Gurdal Sahin ^a, Saruhan Cekirge ^b, Ersin Tan ^a, Okay Saribas ^a^a Department of Neurology, Hacettepe University Hospitals, Ankara, Turkey^b Department of Radiology, Hacettepe University Hospitals, Ankara, Turkey

Received 23 October 2000; accepted 14 May 2001

Abstract

The most frequent type of cerebellar infarcts involved the posterior inferior cerebellar artery (PICA) and superior cerebellar artery territories but bilateral involvement of lateral or medial branches of PICA is extremely rare. In this report, we present a 55-year-old male who admitted to hospital with vomiting, nausea and dizziness. On examination left-sided hemiparesia and ataxic gait were detected. Infarct on bilateral medial branch of PICA artery territories was found out with cranial magnetic resonance imaging (MRI) technique and 99% stenosis of the left vertebral artery was found out with digital subtraction arteriography. The patient was put on heparin treatment. After 3 weeks, his complaints and symptoms had disappeared except for mild gait ataxia. © 2001 Elsevier Science B.V. All rights reserved.

Keywords: Cerebellar infarction; Posterior inferior cerebellar artery; Magnetic resonance imaging

1. Introduction

Cerebellar infarctions usually occur in the territories of posterior inferior cerebellar artery (PICA) and superior cerebellar artery [1]. Among PICA infarctions occlusion of medial and lateral branches are rare and had good prognosis [2]. Occlusion of distal medullary branches of PICA, including the medial branch (mPICA) causes vertigo with or without ipsilateral axial lateropulsion and other types of cerebellar ataxias. Only a few clinicopathological and clinicoradiological studies of infarcts in territory of medial branches of PICA have been reported [3,4]. We describe a clinicoradiological study of a patient with bilateral mPICA infarction.

2. Case report

A 55-year-old man was admitted to our hospital with transient, sudden loss of consciousness. His past medical history revealed coronary by-pass grafting 2 weeks ago on left anterior descending coronary artery. On admission to hospital he was oriented. His blood pressure was 160/70 mmHg and pulse rate was 76 min⁻¹. No carotid bruit could be detected. On neurological examination, left-sided homonymous hemianopia, central facial palsy, hemiparesis and hemineglect were detected. Cranial computerised tomography (CT) scan was normal. The patient was anticoagulated with heparin as an embolic infarction could not be ruled out. His symptoms were fully recovered in 10 h. After 22 h, he woke up at night with sudden onset vertigo, nausea, vomiting and diplopia. On neurological examination only gait ataxia could be detected and no lesion was present on cranial CT which was performed 1 h after the onset of symptoms. After 6 h, his symptoms except vertigo were recovered. Gait ataxia and mild truncal ataxia were detected. Cranial magnetic resonance imag-

* Corresponding author. Tel.: +90-312-305-1806; fax: +90-312-309-3451.

E-mail address: gunfism@ada.net.tr (G. Gurer).

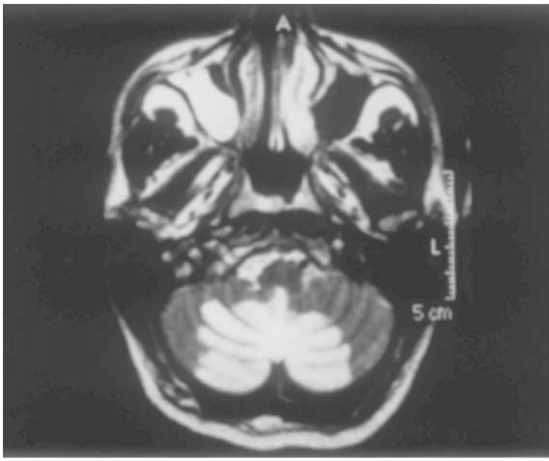


Fig. 1. MRG of the patient showed cerebellar infarct in the territory of both medial PICA.

ing (MRI) performed 16 h after the onset of symptoms revealed infarct on vermis and adjacent areas in the cerebellar hemispheres and infarcts on bilateral parietal subcortical areas (Fig. 1). This distribution on cerebellum was consistent with the territory of medial branch of PICA. Also an ill-defined high intensity lesion was detected on pontomesencephalic junction.

Laboratory examination on admission revealed normal blood count and chemistry. On electrocardiogram, Q waves on V1-6 were detected. Echocardiogram was normal. Digital subtraction angiography (DSA) performed 20 days later showed that both internal carotid arteries and basillary artery were patent (Fig. 2). Left vertebral artery was tortuous but patent. Left PICA was originating from left vertebral artery. There was 99% stenosis of the left vertebral artery, distal to left PICA and 1 cm proximal to vertebrobasilar junction, which showed post stenotic dilatation. Right vertebral artery was hypoplastic and showed retrograde filling with left vertebral artery injection. Right PICA originated from the right vertebral artery. Medial and lateral branches of both PICAs were visualised. Multiple atherosclerotic changes were seen in middle cerebral arteries, right anterior cerebral artery and right posterior cerebral artery. No surgical treatment was suggested for the stenosis of the vertebral artery. The patient received coumadine and amlodipine. He was discharged 5 weeks after admission and on his neurological examination he still had gait ataxia.

3. Discussion

Infarcts in the territory of bilateral medial branches of PICA are usually presented with vertigo, gait

ataxia and attacks of nausea, vomiting and vertigo [3,4]. Clinical and radiographic findings of our patient were consistent with bilateral medial PICA infarct. Several possibilities were considered regarding the pathogenesis of this cerebellar infarct, (1) two PICAs arising from an occluded basillary artery; (2) both medial branches of the PICAs arise from the PICA on one side; (3) two emboli occurred in the PICAs one on each side; (4) pressure effects caused by a large PICA infarct on one side compressing arteries in the cerebellar cistern and inducing a smaller infarct on the other side. Based on cranial MRI and DSA findings of our patient the first two possibilities were excluded. Although the patient had many risk factors like coronary artery by-pass grafting, hypertension and atherosclerotic changes in cerebral arteries it was unlikely that he had emboli at the same time to both medial PICAs. A cardiac origin for emboli could be present since he had many subcortical infarcts in addition to cerebellar infarct but also these infarcts could be secondary to atherosclerosis in small arteries.

Tada et al., reported a 65-year-old man with atrial fibrillation and hypertension who developed mPICA infarct [3]. He had haemorrhagic infarction and he developed acute hydrocephalus 3 days after admission. The authors speculated that the patient had initial transient occlusion of one of the vertebral arteries at the origin of PICA, which probably gave rise to both mPICAs.

Another case reported by Brusa et al., was a 57-year-old woman who had hypertension as a risk factor and developed bilateral mPICA infarct [4]. They could not show any anomalous artery but proposed that an anomalous common mPICA could cause this unusual infarct.

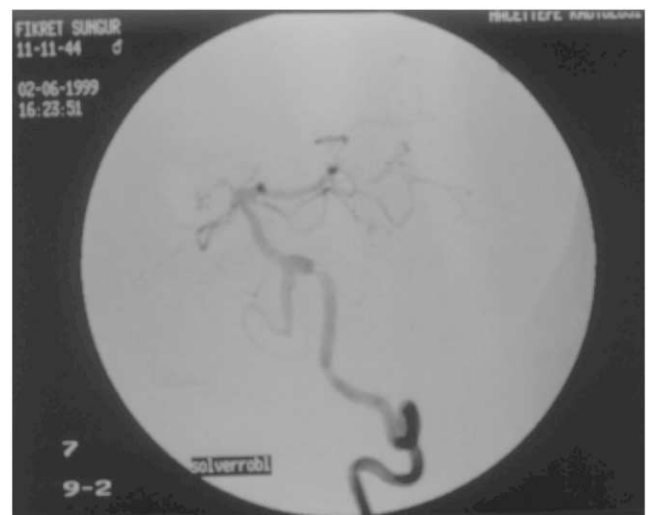

Fig. 2. Digital subtraction angiography of the patient showed stenosis of the left vertebral artery and patent left PICA.

We showed that the left vertebral artery was stenotic distal to the vertebrobasillary junction and right PICA was filled retrogradely. Possibly a thromboembolic occlusion of left vertebral artery could cause occlusion of right PICA but it is not clear how distal medial branches were occluded. Hemodynamic changes in the left vertebral artery may cause transient deficits in both PICAs and might have caused the infarct in the mPICA territory. Hydrocephalus was not detected in our patient and no brain stem signs were found. This unusual distribution and presentation made us consider a vascular anomaly but it could not be detected.

References

- [1] Amarenco P, Roullet E, Hommel M, Chaine P, Marteau R. Infarction in the territory of medial branch of the posterior inferior cerebellar artery. *J Neurol Neurosurg Psychiatr* 1990;53:731–5.
- [2] Kase CS, Norrving B, Levine SR, Babikian VL, Chodosh EH, et al. Cerebellar infarction. Clinical and anatomic observations in 66 cases. *Stroke* 1993;24:76–83.
- [3] Tada Y, Mizutani T, Nishimura T, Tamura M, Mori N. Acute bilateral infarction in the territory of the medial branches of posterior inferior cerebellar arteries. *Stroke* 1994;25:686–8.
- [4] Brusa L, Iannilli M, Bruno G, Di Biasi C, Gualdi GF, et al. Bilateral simultaneous cerebellar infarction in the medial branches of the posterior inferior cerebellar artery territories. *Ital J Neurol Sci* 1996;17:433–6.