

5. Flaherty JA, Bellur SN. Mental side effects of amantadine therapy: its spectrum and characteristics in a normal population. *J Clin Psychiatry* 1981; 42: 344–345.
6. Marshall RD, Douglas CJ. Phenylpropanolamine-induced psychosis: potential predisposing factors. *Gen Hosp Psychiatry* 1994; 16: 358–360.
7. Neppe VM. The psychology of déjà vu: have I been here before? Johannesburg: Witwaterstrand University Press, 1983.
8. Fish DR. Psychic seizures. In: Engel J, Pedley TA, eds. *Epilepsy: a comprehensive textbook*. Volume 1. Philadelphia: Lippincott-Raven, 1997; 543–548.
9. Ardila A, Nino CR, Pulido E, Rivera DB, Vanegas CJ. Episodic psychic symptoms in the general population. *Epilepsia* 1993; 34: 133–140.
10. Richardson TF, Winokur G. Déjà vu as related to diagnostic categories in psychiatric and neurosurgical patients. *J Nerv Ment Dis* 1968; 146: 161–164.
11. Sno HN, Linszen DH, De Jonghe F. Déjà vu experiences and reduplicative paramnesia. *Br J Psychiatry* 1992; 161: 565–568.
12. First MB, Spitzer RL, Gibbon M, Williams BW. *Structured Clinical Interview for DSM-IV Axis I Disorders – Patient Edition (SCID-I/P, Version 2.0, 4/97 revision)*. New York: Biometrics Research Department, New York State Psychiatric Institute, 1997.
13. First MB, Spitzer RL, Gibbon M, Williams BW, Benjamin L. *Structured Clinical Interview for DSM-IV Axis II Personality Disorders (SCID-II)*. New York: Biometrics Research Department, New York State Psychiatric Institute, 1997.
14. Bernstein EM, Putnam FW. Development, reliability, and validity of a dissociation scale. *J Nerv Ment Dis* 1986; 174: 727–735.
15. Stroe AE, Hall J, Amin F. Psychotic episode related to phenylpropanolamine and amantadine in a healthy female. *Gen Hosp Psychiatry* 1995; 17: 457–458 (letter).
16. Laakso A, Vilkinen H, Kajander J, Bergman J, Haaparanta M, Solin J, Hietala J. Prediction of detached personality in healthy subjects by low dopamine transporter binding. *Am J Psychiatry* 2000; 157: 290–292.
17. Wilkerson A, Levin ED. Ventral hippocampal dopamine D₁ and D₂ systems and spatial working memory in rats. *Neuroscience* 1999; 89: 743–749.

Intraaneurysmal embolization of an unruptured basilar tip aneurysm associated with moyamoya disease

Kenji Kagawa¹, Masayuki Ezura¹, Reizo Shirane², Akira Takahashi³, and Takashi Yoshimoto²

¹Department of Neuroendovascular Therapy, Kohnan Hospital, Sendai, Japan, ²Department of Neurosurgery, Tohoku University School of Medicine, Sendai, Japan, ³Department of Neuroendovascular Therapy, Tohoku University School of Medicine, Sendai, Japan

Summary We describe a patient with moyamoya disease associated with an unruptured basilar tip aneurysm which was treated by endovascular embolization using Guglielmi detachable coils (GDCs). A 53-year-old man presented with left hemiparesis persisting for 3 months before admission. Cerebral angiography revealed occlusion of the bilateral middle cerebral arteries and the left anterior cerebral artery, stenosis of the right anterior cerebral artery, and basal moyamoya vessels. In addition, a saccular small aneurysm was seen at the top of the basilar artery. The aneurysm was completely embolized by intraaneurysmal GDCs. Direct surgical clipping is often selected for the treatment of posterior fossa aneurysms in moyamoya disease. However, complete clipping is usually difficult due to the difficulties in operative technique associated with moyamoya disease. We suggest that the endovascular treatment using GDCs is comparatively safe and effective for the treatment of surgically difficult aneurysms in patients with moyamoya disease. © 2001 Harcourt Publishers Ltd

Journal of Clinical Neuroscience (2001) 8(5), 462–464 © 2001 Harcourt Publishers Ltd
DOI: 10.1054/jocn.2000.0806, available online at <http://www.idealibrary.com> on IDEAL[®]

Keywords: cerebral aneurysm, moyamoya disease, endovascular treatment, embolization, Guglielmi detachable coils

Received 1 November 1999

Accepted 9 June 2000

Correspondence to: Kenji Kagawa, Department of Neuroendovascular Therapy, Kohnan Hospital, 4-20-1, Nagamachi-Minami, Taihaku-ku, Sendai, 982-8523, Japan. Tel.: +81 22 248 2131; Fax: +81 22 304 1641

INTRODUCTION

Moyamoya disease is often associated with intracranial aneurysms, and reports of such cases increased in number recently. The incidence of intracranial aneurysms in patients with moyamoya disease was reported from 5% to 15%.^{1–4} With the recent increment of reports of such aneurysms treated surgically, developmental mechanisms and etiologies have gradually become obvious.⁵ Regarding sites of occurrence, two types of aneurysms are found in this disease.^{2–4,6–8} Cerebral aneurysms can be classified into the peripheral artery aneurysms in the moyamoya vessels or collateral circulation, and major artery aneurysms in the circle of Willis. Generally, peripheral artery aneurysms are considered to be pseudoaneurysms, occurring in the fragile moyamoya vessels in the basal ganglia, and rupture of pseudoaneurysms frequently causes intraventricular or intracerebral hemorrhage, but pseudoaneurysms can be gradually reduced and may completely disappear.^{1,2,6} Major artery aneurysms are true aneurysms, occurring in the posterior circulation in about 50–60% of those associated with moyamoya disease.^{2,9} Increased hemodynamic stress in the posterior circulation due to occlusion or stenosis of the internal carotid artery may contribute to the development of this type of aneurysm,^{1,10–12} and the resultant increased blood flow often causes enlargement and rupture of these aneurysms with time.^{3,12–14} Spontaneous disappearance of true aneurysms is extremely rare.^{8,12} Ruptured aneurysms associated with moyamoya disease contribute to the poor clinical outcome. Therefore, treatment to prevent rupture is very important. However, it is difficult to perform radical surgery on aneurysms around the circle of Willis associated with moyamoya disease. In recent years, intravascular procedures have been used to treat such directly inaccessible aneurysms.

We describe a case of unruptured basilar tip aneurysm associated with moyamoya disease manifesting as ischemic attack and treated with intraaneurysmal embolization using Guglielmi detachable coils (GDCs).

CASE REPORT

A 53-year-old man presented with left hemiparesis. The patient visited a nearby hospital. Cerebral angiography demonstrated moyamoya disease and an aneurysm at the top of the basilar artery. Three months later, the patient was referred to our hospital for the treatment of both moyamoya disease and unruptured aneurysm. The patient's parents and older brother had suffered from cerebral infarction. The patient's past history was not contributory.

On admission, the patient's consciousness was clear, but slight left hemiparesis including face was noted. Magnetic resonance imaging (MRI) revealed a dotted line-like watershed infarction in the deep white matter of the right cerebral hemisphere. Right carotid angiography demonstrated occlusion of the middle cerebral artery, stenosis of the anterior cerebral artery, and sparse moyamoya vessels in the base of the brain (Fig. 1). Left carotid angiography showed occlusion of the middle cerebral and anterior

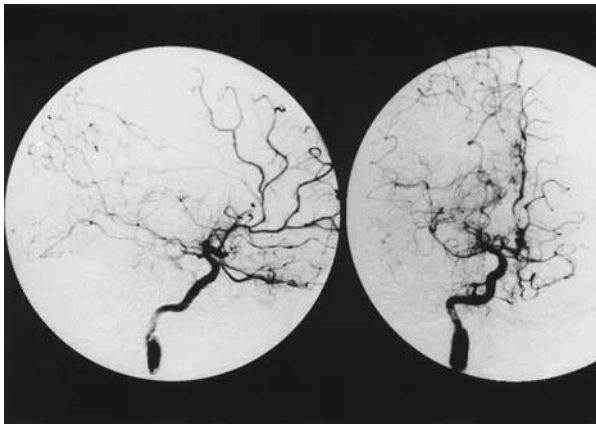


Fig. 1 Right carotid angiograms, lateral view (left) and antero-posterior view (right), showing occlusion at the origin of the middle cerebral artery and stenosis at the proximal segment of the anterior cerebral artery. Moyamoya vessels are seen in the base of the brain.

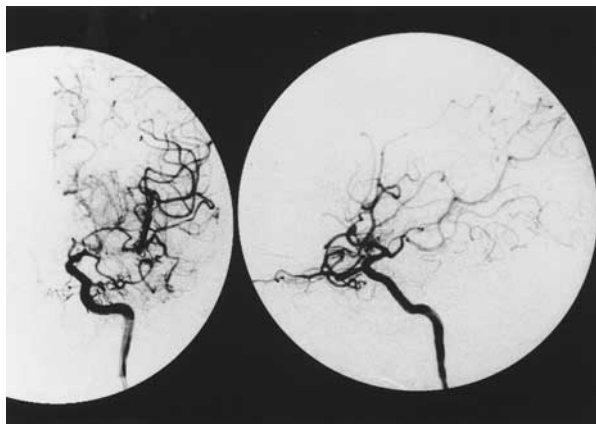


Fig. 2 Left carotid angiograms, antero-posterior view (left) and lateral view (right), showing occlusion of the middle cerebral artery, anterior cerebral artery and basal moyamoya vessels.

cerebral arteries and sparse moyamoya vessels in the base of the brain (Fig. 2). The left middle cerebral artery was occluded at its junction with the anterior temporal artery, but the distal segments of M2 were filled through the collateral circulation from the anterior temporal artery. Though the appearance of the left middle cerebral artery was atypical, we diagnosed these findings as moyamoya disease.^{15,16} Bilateral external carotid angiography showed no abnormality. Right vertebral angiography revealed a saccular aneurysm, 5 × 6 mm in diameter, extending posteriorly at the top of the basilar artery (Fig. 3). We decided to treat this unruptured aneurysm first.

Intraaneurysmal embolization was performed to treat the saccular aneurysm. Under local anesthesia, a 6F guiding catheter was introduced into the left vertebral artery through the left femoral artery. Following systemic heparinization, a microcatheter (Prowler 10; Cordis, Miami Lakes, FL) was guided into the aneurysm sac, and the aneurysm was completely occluded with 5GDCs (GDC-10; Boston Scientific, Boston, MA), 6 mm × 10 cm, 5 mm × 15 cm, soft 4 mm × 8 cm, soft 4 mm × 6 cm, and soft 3 mm × 8 cm (Fig. 4).

The patient had no new neurological deficits postoperatively, and was discharged on foot 8 days later when cerebral angiography confirmed complete occlusion of the aneurysm. Vascular reconstruction for moyamoya disease is planned for 6 months after discharge.

DISCUSSION

General consensus has not been achieved for the treatment of unruptured aneurysms associated with moyamoya disease, especially

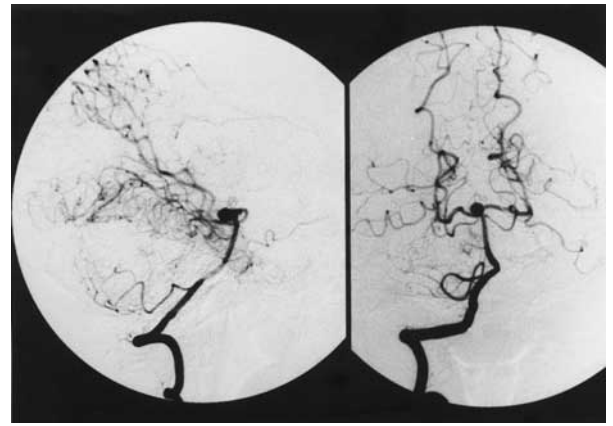


Fig. 3 Right vertebral angiograms, lateral view (left) and antero-posterior view (right), showing a saccular aneurysm at the top of the basilar artery.

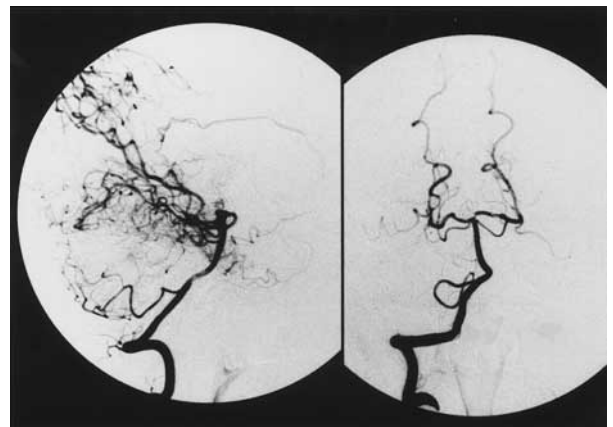


Fig. 4 Right vertebral angiograms after embolization, lateral view (left) and antero-posterior view (right), showing complete occlusion of the aneurysm.

aneurysms located in the posterior cranial fossa. The main problem in direct operation is the presence of moyamoya vessels around the aneurysm, which are important as collateral circulation in the brain with moyamoya disease and cannot be sacrificed. Therefore, the fragile moyamoya vessels could be the obstacle for the clipping procedure.³

Posterior fossa aneurysms are frequently associated with moyamoya disease. Surgical treatment of posterior fossa aneurysms are generally difficult, but more so when associated with moyamoya disease.⁸ The subtemporal approach,^{3,7} pterional approach,^{4,11,12,14,17} and orbitozygomatic approach¹³ have been used to approach basilar tip aneurysms associated with moyamoya disease. The approach should be selected to prevent retraction of the brain. The brain with moyamoya disease is under chronic hypoperfusion. Excessive brain retraction may cause cerebral blood flow disturbance, resulting in postoperative complications such as cerebral infarction or intracerebral hemorrhage, and may also damage the moyamoya vessels.¹⁴ Patients frequently present with subarachnoid hemorrhage caused by rupture of a cerebral aneurysm associated with moyamoya disease, and most are in poor clinical grades. The Hunt and Kosnik (H & K) grade of these cases were grade 3 in 32%, grade 4 in 35%, and grade 5 in 4%.⁹ Complete clipping is usually difficult because of the operative difficulties. About half of these patients were treated conservatively and successful neck clipping was achieved in only 20%.⁹ The initial clinical grade were important factor for the poor clinical outcome. Therefore, the treatment of an unruptured aneurysm associated with moyamoya disease is thought to be necessary.

Management of the anesthesia in moyamoya disease is also difficult.⁸ Direct surgery necessitates general anesthesia, which may cause postoperative aggravation of clinical symptoms or cerebral infarction due to hypocapnia induced by intraoperative hyperventilation.¹⁸ On the other hand, hypercapnia is thought to cause cerebral infarction due to the steal phenomenon.^{19,20} Therefore, careful management of anesthesia is important to prevent ischemia.

Endovascular treatment can overcome these problems of direct surgery. The greatest advantage is the avoidance of direct invasion to the brain such as retraction, and aneurysms can be approached without affecting the moyamoya vessels or brain. In addition, basilar tip aneurysms can be approached relatively easily in embolization compared to direct surgery. Endovascular treatment can be performed under local anesthesia, so complications caused by general anesthesia such as circulation disturbance can be prevented.

To our knowledge, endovascular treatment for cerebral aneurysms associated with moyamoya disease has only been performed in four reported cases,^{8,21} including only one case of unruptured cerebral aneurysm, in which the patient died of complications due to anesthesia and infection after embolization. Therefore, this is the first reported case of an unruptured aneurysm associated with moyamoya disease successfully treated with GDCs without postoperative complications.

Intraaneurysmal embolization with GDCs is a good choice for cases difficult to treat by direct surgery. However, the vertebro-basilar system is the only source of blood supply for the brain in most patients with moyamoya disease,^{3,12} so parent artery occlusion due to coil migration, mechanical spasm, thrombo-embolism or dissection due to catheter manipulation will cause serious problems.³ Therefore, endovascular treatment should be performed by skilled interventionalists, and long-term follow-up with cerebral angiography is also necessary because of the higher recurrence rate in embolization compared to complete clipping.

REFERENCES

- Borota L, Marinkovic S, Bajic R, Kovacevic M. Intracranial aneurysms associated with Moyamoya disease. *Neurol Med Chir (Tokyo)* 1996; 36: 860–864.
- Herreman F, Nathal E, Yasui N, Yonekawa Y. Intracranial aneurysms in Moyamoya disease: report of ten cases and review of the literature. *Cerebrovasc Dis* 1994; 4: 329–336.
- Iwama T, Todaka T, Hashimoto N. Direct surgery for major artery aneurysm associated with Moyamoya disease. *Clin Neurol Neurosurg* 1997; 99: 191–193.
- Yabumoto M, Funahashi K, Fujii T, Hayashi S, Komai N. Moyamoya disease associated with intracranial aneurysms. *Surg Neurol* 1983; 20: 20–24.
- Ohtoh T, Iwasaki Y, Namiki T et al. Hemodynamic characteristics of the vertebrobasilar system in Moyamoya disease: A histometric study. *Hum Pathol* 1988; 19: 465–470.
- Bucciero A, Carangelo B, Vizioli L. Giant basilar artery aneurysm associated with Moyamoya disease. Case report and review of the literature. *Acta Neurol (Napoli)* 1994; 16: 121–128.
- Kodama N, Sato M, Sasaki T. Treatment of ruptured cerebral aneurysm in Moyamoya disease. *Surg Neurol* 1996; 46: 62–66.
- Massoud TF, Guglielmi G, Viñuela F, Duckwiler GR. Saccular aneurysm in Moyamoya disease: Endovascular treatment using electrically detachable coils. *Surg Neurol* 1994; 41: 462–467.
- Kawaguchi T, Yokoyama H, Tsutsumi K, Ichikura A, Onituka M, Nakamura S. Surgical treatment of aneurysms at basilar artery and posterior cerebral artery associated with Moyamoya disease: A case report. *No Shinkei Geka* 1995; 23: 807–811 (Jpn, with Eng abstract).
- Hamada J, Hashimoto N, Tsukahara T. Moyamoya disease with repeated intraventricular hemorrhage due to aneurysm rupture: Report of two cases. *J Neurosurg* 1994; 80: 328–331.
- Kawaguchi S, Sakaki T, Morimoto, T, Kakizaki T, Kamada K. Characteristics of intracranial aneurysms associated with Moyamoya disease: a review of 111 cases. *Acta Neurochir (Wien)* 1996; 138: 1287–1294.
- Muizelaar JP. Early operation of ruptured basilar artery aneurysm associated with bilateral carotid occlusion (Moyamoya disease). *Clin Neurol Neurosurg* 1988; 90: 349–355.

- Kamada K, Imanishi M, Kawaguchi S, Koshimae N, Tokunaga H, Yong Su Park . Orbitozygomatic temporopolar approach for basilar aneurysm associated with Moyamoya disease. *Surg Cerebral Stroke* 1993; 21: 161–166 (Jpn, with Eng abstract).
- Nagamine Y, Takahashi S, Sonobe M . Multiple intracranial aneurysms associated with moyamoya disease. *J Neurosurg* 1981; 54: 673–676.
- Suzuki J, Takaku A. Cerebrovascular “Moyamoya” disease: disease showing abnormal net-like vessels in base of brain. *Arch Neurol* 1969; 20: 288–299.
- Suzuki J, Kodama N . Moyamoya disease – A review. *Stroke* 1983; 14: 104–109.
- Kawano T, Fukushima M, Mori K, Suyama K. Basilar aneurysm associated with Moyamoya disease – A case report and operative considerations. *Surg Cerebral Stroke* 1987; 15: 285–289 (Jpn, with Eng abstract).
- Yamagishi N, Hashizume K, Matsuzawa N et al. Anesthetic management of revascularization for Moyamoya disease. *Masui* 1991; 40: 1132–1137 (Jpn, with Eng abstract).
- Kuwabara Y, Ichiya Y, Sasaki M et al. Response to hypercapnia in Moyamoya disease. *Stroke* 1997; 28: 701–707.
- Yamada K, Miyamoto S, Nagata I et al. Reverse steal phenomenon in Moyamoya disease. *Jpn J Neurosurg (Tokyo)* 1995; 4: 145–150 (Jpn, with Eng abstract).
- Sugiura Y, Matuzawa Y. Endovascular treatment using platinum coil of a peripheral artery aneurysm associated with Moyamoya disease: case report. *No Shinkei Geka* 1998; 26: 73–77 (Jpn, with Eng abstract).

Pharyngeal perforation and spontaneous extrusion of the cervical graft with its fixation device: a late complication of C2-C3 fusion via anterior approach

Rewati Raman Sharma MS (NEUROSURGERY)
DNB (NEUROSURGERY), Arunachala U. Sethu MS (ORTHO) FRCS
FRCS(ED) (ORTH), Santosh D. Lad MS FRSH, Keki E. Turel MS
(NEUROSURGERY), Sanjay J. Pawar MS (GEN SURGERY) MCH
(NEUROSURGERY)

The National Neurosurgical Centre and Department of Orthopaedics, Khoula Hospital, PO Box 90, PC 116, Mina-Al-Fahal, Muscat, Sultanate of Oman

Summary Stabilisation of the fracture-dislocation of the cervical spine is achieved effectively by anterior or posterior or combined methods with attendant short and long term benefits, risks and complications associated with each procedure. Recently anterior methods have gained wider acceptance. A variety of preoperative and postoperative complications associated with anterior cervical fusion are well recognised. However, the delayed pharyngeal or oesophageal perforation is a rare, serious and life threatening complication of an anterior cervical internal fusion.

The authors report a case of delayed pharyngeal perforation and spontaneous extrusion of the C2-C3 graft with its fixation device. After coughing out the entire gamut of the graft with the fixation pin, the patient was relieved of excruciating pain and dysphagia and had no significant morbidity thereafter over a 12-year follow up period.

Relevant aspects are discussed with a review of the pertinent literature. © 2001 Harcourt Publishers Ltd

Journal of Clinical Neuroscience (2001) 8(5), 464–468 © 2001 Harcourt Publishers Ltd
DOI: 10.1054/jocn.2000.0826, available online at <http://www.idealibrary.com> on IDEAL[®]