

Popliteal Venous Aneurysm With Paradoxical Embolization in a Patient With Patent Foramen Ovale

W.A. Willinek, MD; H. Strunk, MD; M. Born, MD; J. Remig, MD; H. Becher, MD; H. Schild, MD

An 18-year-old woman was found in bed with right-sided hemiplegia and global aphasia. Acute ischemic lesions in the left basal ganglia, the left insula cortex, and the cortex of the left parietal lobe were found on diffusion-weighted MRI (Figure 1). The patient underwent contrast echocardiography, and a patent foramen ovale with right-to-left shunt was diagnosed (Figure 2). Systemic anticoagulation with heparin was initiated, and a regression of neurological signs and symptoms was observed. Comorbid diseases such as a coagulation disorder, a thrombus within a cardiac chamber, and

cerebral or carotid atherosclerosis were excluded. A duplex scan revealed a 3.5×4 cm saccular popliteal venous aneurysm (Figure 3), which was confirmed by MRI and was presumed to be the origin of paradoxical embolization. The patient underwent tangential aneurysmectomy and lateral venorrhaphy of a 4×3.5×2.5 cm saccular venous aneurysm. No thrombus was noted within the aneurysm. In a second session, transcatheter closure of the foramen ovale with an umbrella system was performed. The patient tolerated both procedures well and has remained symptom-free.

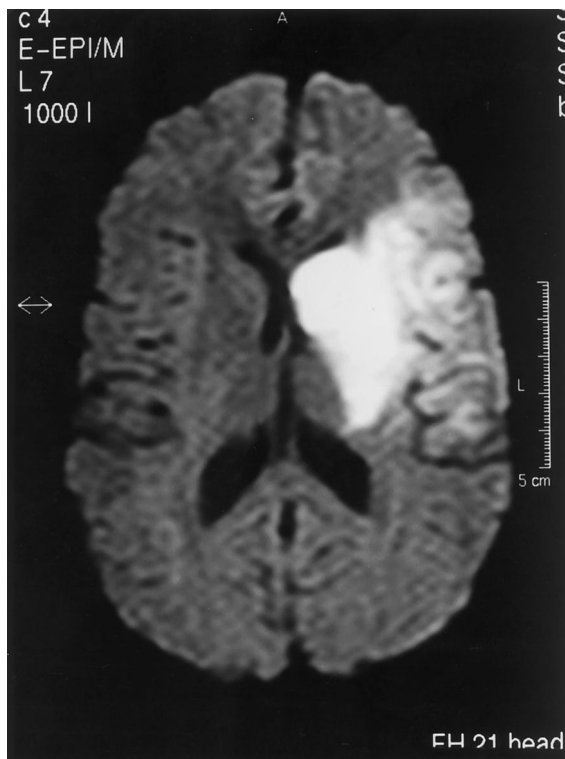


Figure 1. Axial diffusion-weighted MRI of the brain performed on the day of admission. Diffusion-weighted imaging showed fresh infarction of the left basal ganglia, left insula, and parietal lobe cortex.

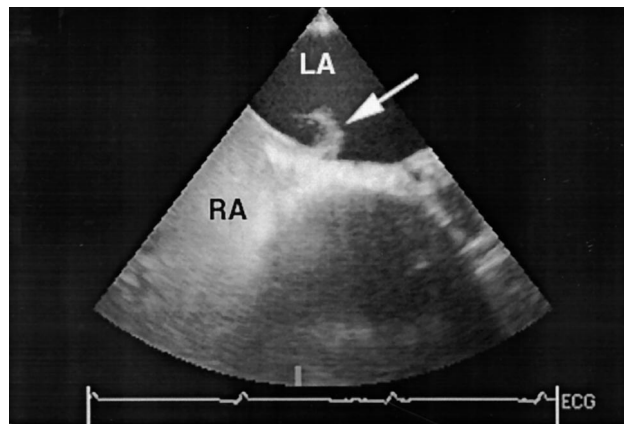


Figure 2. Contrast echocardiographic examination. Contrast material completely fills the right atrium and appears in the left atrium through a patent foramen ovale (arrow). RA indicates right atrium; LA, left atrium.

From the Departments of Radiology (W.A.W., H.S., M.B., H.S.), Surgery (J.R.), and Cardiology (H.B.), University of Bonn, Bonn, Germany. Correspondence to Dr W.A. Willinek, Department of Radiology, University of Bonn, Sigmund-Freud-Str 25, D-53105 Bonn, Germany. E-mail willinek@uni-bonn.de

The editor of Images in Cardiovascular Medicine is Hugh A. McAllister, Jr, MD, Chief, Department of Pathology, St Luke's Episcopal Hospital and Texas Heart Institute, and Clinical Professor of Pathology, University of Texas Medical School and Baylor College of Medicine.

Circulation encourages readers to submit cardiovascular images to the *Circulation* Editorial Office, St Luke's Episcopal Hospital/Texas Heart Institute, 6720 Bertner Ave, MC1-267, Houston, TX 77030.

(*Circulation*. 2001;104:e60-e61.)

© 2001 American Heart Association, Inc.

Circulation is available at <http://www.circulationaha.org>

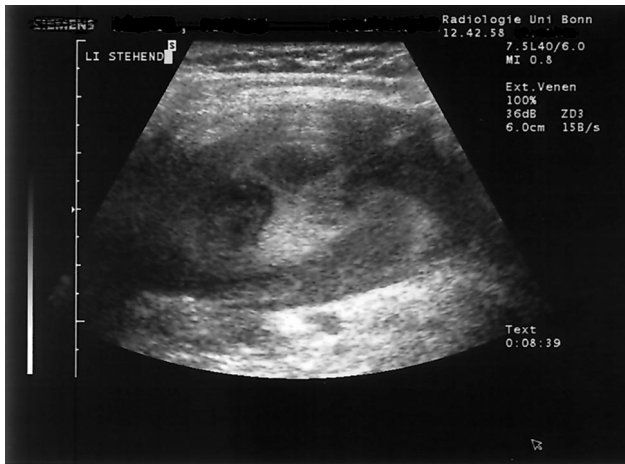

Figure 3. Duplex sonography of the left popliteal venous aneurysm with the patient in upright position. Extremely slow flow was demonstrated within the lumen of the aneurysm.