

HEMORRHAGE IN CEREBRAL METASTASIS FROM ANGIOSARCOMA OF THE HEART

Case report

Pasquale Gallo, Leandro Infantini Dini, Glauco André Saraiva, Ildo Sonda, Gustavo Isolan

ABSTRACT - The purpose of this article is to describe the clinical and pathological features of metastatic angiosarcoma in the central nervous system. Only a few cases of cerebral metastasis from angiosarcoma of the heart have been recorded in the literature; particularly related to intracerebral hemorrhage. A case of secondary cerebral angiosarcoma of the heart in a 33 years old man is presented. The initial symptoms were headache, vomiting, lethargy and aphasia. There was a mass in the left temporal lobe with hemorrhage and edema on the computerized tomography (CT). After 24 hours the neurological status worsened and another CT scan showed rebleeding on the tumor area. He underwent an emergency craniotomy but died two days after. Considering the longer survival of sarcoma patients with new modalities of treatment, the incidence of brain metastasis may increase, demanding a better preventive and more aggressive approach. Besides, due to the hemorrhagic nature of such lesions, we suggest the immediate surgery to prevent a fast and lethal evolution because rebleeding.

KEY WORDS: brain neoplasm, metastasis, angiosarcoma, heart tumor.

Hemorragia em metástase cerebral de angiossarcoma cardíaco: relato de caso

RESUMO - O propósito deste artigo é descrever os achados clínicos e patológicos das metástases de angiossarcoma no sistema nervoso central. Apenas poucos casos de metástases cerebrais de angiossarcoma cardíaco foram relatados na literatura, menos ainda relacionados a hemorragia intracerebral. Relatamos o caso de um tumor cerebral secundário a angiossarcoma cardíaco em um paciente masculino de 33 anos. Os sintomas iniciais foram: cefaléia, vômitos, letargia e afasia. A tomografia computadorizada mostrou massa no lobo temporal esquerdo associada a hemorragia e edema. Após 24 horas houve piora do estado neurológico e nova tomografia demonstrou ressangramento no leito tumoral. Foi submetido a uma craniotomia de urgência mas faleceu dois dias após. Considerando a longa sobrevivência dos pacientes com sarcoma devido às novas modalidades terapêuticas, poderá aumentar a incidência de metástases cerebrais, necessitando, assim, de melhores métodos preventivos e abordagens cirúrgicas agressivas.

PALAVRAS-CHAVES: neoplasia cerebral, metástase, angiossarcoma, tumor cardíaco.

Angiosarcoma are rare malignant tumors originating from the endothelial cells of arteries, veins or lymphatic channels^{1,2}. This tumor mainly occurs in the head and face, liver, skin and other soft tissues and comprises lower than 1% of all sarcomas³⁻⁶. Cases of primary or secondary angiosarcomas in the central nervous system (CNS) are exceedingly rare malignancies and have previously been reported only exceptionally^{1-4,7-9}.

We present a case of cerebral metastasis from angiosarcoma of the heart manifested by intracerebral hemorrhage.

CASE

A 33 years old male patient was admitted in the emergency room at Cristo Redentor Hospital (Porto Alegre - RS - Brasil) with headache, vomiting, lethargy and aphasia. Computed tomography (CT) revealed a mass in the left temporal lobe with hemorrhage and edema (Fig 1). Another CT scan obtained 1 day after admission, after deterioration of clinical course, showed a hematoma in the left temporal and occipital lobes (Fig 2). The patient underwent a left craniotomy with complete evacuation of the hematoma. Despite supportive therapy, his neurological condition worsened. He became hypotensive and died two days after surgery.

Neurosurgery Department of Cristo Redentor Hospital, Porto Alegre RS, Brazil.

Received 17 October 2000, received in final form 16 May 2001. Accepted 26 May 2001.

Dr. Pasquale Gallo - Rua Tobias da Silva 99/203 - 90570-020 Porto Alegre RS - Brasil.

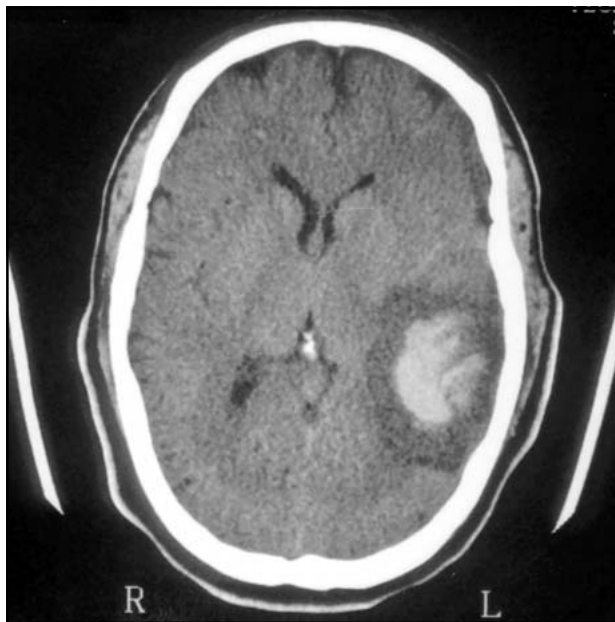


Fig 1. CT scan showing a mass in the left temporal lobe with hemorrhage and edema.

One year previously he had suffered a thoracotomy to resection of a right atrium tumor. The histological examination of the removed tissue showed an angiosarcoma and adjuvant treatment - radiotherapy of the mediastinum and chemotherapy (adriamycin, ifosfamin and DTIC) - was instituted at that time. Pathological study of the tumor disclosed prominent vascular channels of different sizes and shapes lined by tumor cells. Extensive areas of necrosis were present in the excised tissue. Immunohistochemical study revealed tumor cells reactive for Factor VIII - related antigen, confirming the endothelial origin of the tumor.

DISCUSSION

Although any brain tumor can bleed, tumoral intracerebral hemorrhage is usually associated with malignancies. Tumors can also produce subarachnoid hemorrhage or subdural hematomas. The malignant tumors most commonly associated with intracerebral hemorrhage are glioblastoma multiforme, lymphoma and metastatic tumor: melanoma, choriocarcinoma, renal cell carcinoma and bronchogenic carcinoma¹⁰.

Sarcomas involving the CNS can develop either in the parenchyma or in the adjacent structures or may originate in distant organs¹¹. The incidence of brain sarcomas varies from 0.5% to 2.7% with an average of 1.5% in 27487 intracranial neoplasms^{11,12}. The development of new treatment protocols has improved the period of survival in patients with sarcomas. The incidence of cerebral metastasis has increased, maybe as a result of more time for tumor spread.

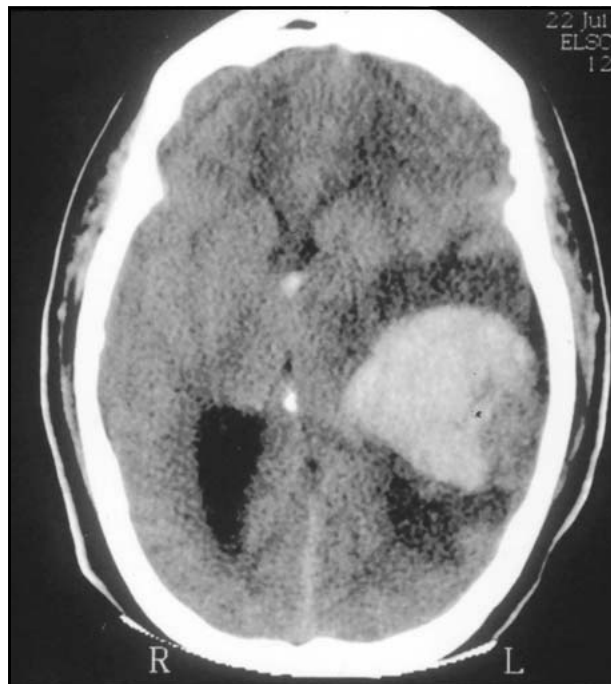

Fig 2. CT scan after neurological deterioration shows an increase in blood volume. Edema and mass effect can be seen.

Primary cardiac tumors are found in 0,007% of all autopsies¹³. Almost all primary malignant cardiac tumors are sarcomas, most frequently angiosarcomas, and usually originate in the right atrium or pericardium. Brain metastasis are generally considered to be a rare occurrence in patients with non-hematologic sarcomas, and most reviews of cerebral metastatic disease do not include metastatic sarcoma¹³⁻¹⁵.

Microscopically, angiosarcomas are endothelial neoplasms forming irregular vascular spaces^{3,4}. Immunocytochemistry and electron microscopy are always beneficial in differentiating angiosarcoma from meningeal hemangiopericytoma (angioblastic meningioma)^{3,13,17}. The specific pathological criterion used to characterize angiosarcoma is the diffuse positivity of tumor cells for Factor VIII and lectin ULEX^{2,9}, whereas in hemangiopericytoma, it is the endothelial cells that are positive for these factors^{3,5,18}.

Known risk factors for non-CNS angiosarcomas include longstanding lymphedema (following radical mastectomy)¹⁹, irradiation²⁰, chemotherapy²¹, arsenic exposure and the diagnostic use of thorium dioxide as a contrast dye for angiography⁵. Vinyl chloride is perhaps the best environmental agent documented as a cause of angiosarcoma. Workers exposed to this material, principally in its gaseous state, have a high incidence of hepatic fibrosis and angiosarcoma²², and also an increased risk for developing glioblastoma multiforme²³. In contrast to their rarity in nature, an-

giosarcomas are easily produced experimentally by several methods. Hamsters inoculated intracerebrally with brain tissue from a patient with progressive multifocal leukoencephalopathy (PML) developed angiosarcomas²⁴. As expected, the resulting angiosarcomas reacted with antisera to the SV-40T antigen, in keeping with the close relationship between the papovavirus causing PML and the oncogenic SV-40 virus. In addition, the Kirsten mouse sarcoma virus produces exclusively angiosarcomas when inoculated into rat brain²⁵. It is of interest that another vascular sarcoma associated with a viral infection, Kaposi's sarcoma, has become much more frequent since the beginning of the acquired immune deficiency syndrome epidemic. Although non-CNS Kaposi's sarcoma are relatively frequent, only a few cases of cerebral involvement with Kaposi's sarcoma have been reported^{26,27}. Molecular analysis showed that the ability of these viruses to cause angiosarcoma correlated with specific deletions or truncations in the C-terminal region of the viral erb-B oncogenes²⁸.

The biological behavior of angiosarcomas is not well known because these tumors are among the rarest of human neoplasms^{1,2}. The clinical course of primary angiosarcoma of the brain is characterized by the rapid onset of symptoms^{2,9}. The diagnosis is usually established by CT scan or magnetic resonance imaging that show well circumscribed tumors with hemorrhage and surrounding edema^{2,7}.

The clinical course of brain angiosarcoma is characterized by the rapid onset of symptoms. The initial approach in patients with brain angiosarcomas should always be the surgical removal of the tumors³. During the surgery the blood loss can be substantial, and early recurrence after surgery with or without radiation therapy can occur. These characteristics argue for aggressive multimodal therapy, as described by Antoniadis et al.³. Given the vascularity of the tumor, intraoperative blood loss might be diminished by circumferentially dissecting around the tumor, dividing the traversing vascular supply, rather than intratumorally debulking³. Vaquero et al.¹ report the first case of cerebral metastasis from angiosarcoma after heart transplantation and question the long-term usefulness of transplantation as treatment for malignant heart tumors. In that case, it could be considered that the immunosuppressors can facilitate the occurrence of metastasis.

The role of adjuvant treatment on the survival of patients with brain angiosarcoma is not well defined. Adjuvant chemotherapy for primary, specially high-grade, soft tissue sarcoma continues to be experi-

mental³. Most of the prospective randomized studies completed to date have failed to demonstrate a clear benefit for treated patients (6). Obviously, there is a lack of information regarding the relationship between adjuvant chemotherapy and survival of patients with brain angiosarcoma because of the rarity of the disease³. It was reported an occurrence of 10 % of brain metastasis in 114 inoperable sarcoma patients, no one with angiosarcoma diagnosis²⁶. This percentage is relatively high considering that metastasis of sarcoma to the CNS is reported as rare. In the review by Haar²⁹, the incidence of brain metastasis from sarcoma was 3%. The increased incidence of brain metastasis may be related to longer survival of sarcoma patients and to the inability of drugs used in the treatment of sarcomas to cross the blood-brain barrier. Preventive treatment of brain metastasis with drugs active in the CNS or with radiotherapy following the diagnosis of pulmonary metastasis could be useful^{26,30}.

The drugs currently in use for treatment of sarcomas, such as adriamycin, do not effectively penetrate the CNS. Nitrosoureas, which penetrate the blood-brain barrier and have been reported active in brain tumors, do not have significant activity against sarcomas³¹. However, the combination of adriamycin, dactinomycin, cyclophosphamid, or vincristine (drugs most active in sarcomas) with BCNU, CCNU, or MeCCNU (most active in brain tumors) could be theoretically useful for prevention of brain metastasis. The combination of brain and lung radiation therapy and chemotherapy following the initial diagnosis seems unadvisable considering the high incidence of bone marrow toxicity¹¹.

España et al.²⁶ suggest that, given the relatively long interval between pulmonary metastasis and the development of brain metastasis (32 weeks in their cases), prophylactic adjuvant radiotherapy of the whole brain once the diagnosis of pulmonary metastasis has been done could be an interesting approach to the control of CNS malignancy.

In conclusion, by the occurrence of the hemorrhage on the histological descriptions of that pathology, and by the fast and lethal evolution, due to the tumoral apoplexy in this present case, we suggest immediate surgery after the probable diagnostic of metastatic brain tumor.

REFERENCES

1. Vaquero J, Martinez R, Coca S, et al. Cerebral metastasis from angiosarcoma of the heart. *J Neurosurg* 1990;73:633-635.
2. Charman HP, Lowenstein DH, Cho KG, et al. Primary cerebral angiosarcoma. *J Neurosurg* 1988;68:806-810.

3. Antoniadis C, Selviaridis P, Zaramboukas T, Fountzilas G. Primary angiosarcoma of the brain: case report. *J Neurosurg* 1996;38:583-586.
4. Cookston M, Cotter GW, Schlitt M, Bastian FO. Primary angiosarcoma of the brain. *South Med J* 1991;84:517-520.
5. Enzinger FM, Weiss SW. Malignant vascular tumors. In *Soft tissue tumors*. St. Louis: CV Mosby, 1988:545-561.
6. Naka N, Ohsawa M, Tomita Y, Kanno H, Uchida A, Aozasa K. Angiosarcoma in Japan: a review of 99 cases. *Cancer* 1995;75:989-996.
7. Kristoferitsch W, Jellinger K. Multifocal spinal angiosarcoma after chordotomy. *Acta Neurochir* 1975;79:145-153.
8. Zeigler JW. Primary angiosarcoma of the brain: report of a case. *J Am Osteopath Assoc* 1975;74:957-960.
9. Mena H, Ribas JL, Enzinger FM, Parisi JE. Primary angiosarcoma of the central nervous system: eight cases and review of the literature. *J Neurosurg* 1991;75:73-76.
10. Greenberg MS. Intracerebral hemorrhage in adults. In *Handbook of Neurosurgery*. 4.Ed. Greenberg Graphics, 1997:883-884.
11. Mena H, Garcia JH. Primary brain sarcomas: light and electron microscopic features. *Cancer* 1973;42:1298-1307.
12. Berger MS, Kros JM. Sarcomas and neoplasms of blood vessels. In *Youmans JR. Neurological surgery*. 5.Ed. Philadelphia: W.B. Saunders, 1996:2700-2714.
13. Barber F, Rosen P, Okin T. Atrial myxoma presenting as stroke. *An Emergency Med* 1982;11:316-318.
14. Hare CC, Schwartz GA. Intracerebral carcinomatous metastasis. *Arch Intern Med* 1939;64:542-565.
15. Rupp C. Metastatic tumors of the central nervous system. *Arch Neurol* 1948;59:635-645.
16. Wilson G, Rupp C. Metastatic tumors of the central nervous system. *Am Pract* 1949;3:350-352.
17. Pena CE. Meningioma and intracranial hemangiopericytoma: a comparative electron microscopic study. *Acta Neuropathol (Berl)* 1977; 39:69-74.
18. Böhling T, Paetau A, Ekblom P, Haltia M. Distribution of endothelial and basement membrane markers in angiogenic tumors of the nervous system. *Acta Neuropathol (Berl)* 1983;62:67-72.
19. Stewart FW, Treves W. Lymphangiosarcoma in postmastectomy lymphedema: a report of six cases of elephantiasis chirurgica. *Cancer* 1948; 1:64-81.
20. Chen KTK, Hoffman KD, Hendricks EJ. Angiosarcoma following therapeutic irradiation. *Cancer* 1979;44:2044-2048.
21. Zwi LJ, Evans DJ, Wechsler AL, et al. Splenic angiosarcoma following chemotherapy for follicular lymphoma. *Hum Pathol* 1986;17:528-530.
22. Abrenga DP. Primary angiosarcoma of the liver: review article. *Int Surg* 1975;60:198-203.
23. Infant PF, Wagner JK, Waxweiler RJ. Carcinogenic, metagenic and teratogenic risks associated with vinyl chloride. *Mutat Res* 1976;41:131-142.
24. Brun A, Johnsson HW. Angiosarcoma in hamsters after inoculation of brain tissue from a case of progressive multifocal leukoencephalopathy. *Cancer* 1984;53:1714-1717.
25. Pitts OM, Powers JM, Hoffman PM. Vascular neoplasms induced in rodent central nervous system by murine sarcoma viruses. *Lab Invest* 1983;49:171-182.
26. España P, Chang P, Wiernik PH. Increased incidence of brain metastasis in sarcoma patients. *Cancer* 1980;45:377-380.
27. Gorin FA, Bale JF Jr, Halks-Miller M, et al. Kaposi's sarcoma metastatic to the CNS. *Arch Neurol* 1985;42:162-165.
28. Tracy SE, Woda BA, Robinson H. Induction of angiosarcoma by a c-erbB transducing virus. *J Virol* 1985;54: 304-310.
29. Haar F, Patterson RH. Surgery for metastatic intracranial neoplasm. *Cancer* 1972;30:1241-1245.
30. Gercovich FG, Luna MA, Gottlieb JA. Increased incidence of cerebral metastasis in sarcoma patients with prolonged survival from chemotherapy. Report of cases of leiomyosarcoma and chondrosarcoma. *Cancer* 1975;36:399-419.
31. Slavik M, Soper WT, Carter SK. Tabular analysis of the clinical chemotherapy of solid tumors. *Cancer Chemother Rep* 1975;6:399-419.