

Basilar Artery Vasculitis Secondary to Sphenoid Sinusitis

—Case Report—

Takatoshi SORIMACHI, Kenichi KAMADA*, Tsunenori OZAWA**,
and Shigekazu TAKEUCHI**

Department of Neurosurgery, Nishiogi Central Hospital, Tokyo; *Department of Neurosurgery,
Sannocho Hospital, Niigata; **Department of Neurosurgery,
Brain Research Institute, Niigata University, Niigata

Abstract

A 35-year-old male presented with basilar artery vasculitis secondary to sphenoid sinusitis manifesting as rapidly deteriorating symptoms including consciousness disturbance and right hemiparesis. Computed tomography (CT) on admission showed sphenoid sinusitis without intracranial lesion. Emergency angiography demonstrated basilar artery stenosis. The neurological deterioration was considered to be caused by ischemia of the perforating arteries branching from the stenotic portion of the basilar artery. The patient was treated with urokinase infusion through a microcatheter just proximal to the stenosis 3 hours after the onset of the symptoms. His consciousness level and right hemiparesis markedly improved immediately after the procedure. Magnetic resonance (MR) imaging on day 5 revealed that extension of the sphenoid sinusitis into the prepontine cistern had formed an abscess which was attached to the clivus. The basilar artery was embedded in the abscess at the angiographic stenosis. Cerebrospinal fluid (CSF) analysis showed white blood cell count of 601/mm³ with 82% neutrophils, 89.2 mg/dl protein, and 31 mg/dl glucose. No causative organism in the CSF could be identified by smear or culture. Early MR imaging and CSF examination are recommended when patients present with both ischemic symptoms involving the basilar artery and opacification of the sphenoid sinus on CT to identify basilar artery vasculitis secondary to sphenoid sinusitis.

Key words: abscess, cerebral infarction, sphenoid sinusitis, vasculitis

Introduction

Cerebral vasculitis is a rare complication of sphenoid sinusitis.^{2,7,8,12,16,17)} Most of the reported cases of vasculitis secondary to sphenoid sinusitis were associated with cavernous carotid artery aneurysms.^{2,12,16,17)} Cerebral ischemic complications of sphenoid sinusitis have occurred in only a few cases.^{7,8)} Furthermore, angiographic changes in the cerebral arteries causing ischemia have never been detected. We present a case of vasculitis secondary to sphenoid sinusitis with angiographically demonstrated basilar artery stenosis.

Case Report

A 35-year-old male presented with progressive consciousness impairment and right hemiparesis fol-

lowed by fever and mild occipitalgia presenting for 2 days. He had a 3-year history of nasal discharge. On admission, the patient was lethargic with left abducens nerve palsy, severe right hemiparesis, left ataxia, and no sign of meningismus. Computed tomography (CT) revealed sphenoid sinusitis with opacification, but no intracranial lesion (Fig. 1A). CT found no bony defect of the clivus (Fig. 1B). Emergency angiography showed stenosis in the middle portion of the basilar artery (Fig. 2).

A microcatheter was introduced into the basilar artery just proximal to the stenosis via a transfemoral approach and urokinase (300,000 U) was infused 3 hours after the onset of the symptoms. Although post-treatment angiography showed no apparent change in the basilar artery stenosis, the patient became alert and almost completely recovered from right hemiparesis immediately after the procedure with residual left abducens nerve palsy and left ataxia. The patient was treated with fosfomycin for persistent mild fever considered to be

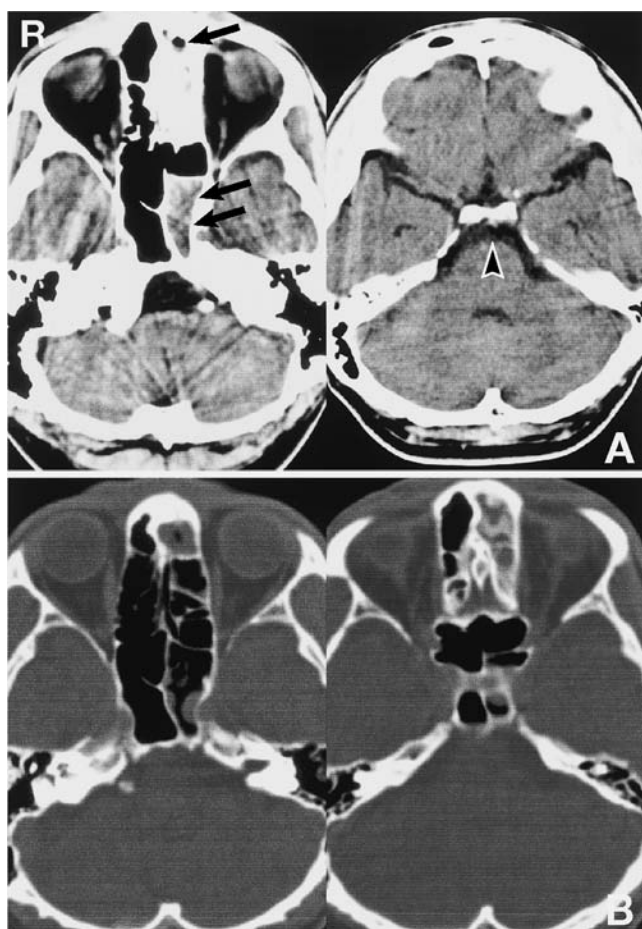


Fig. 1 A: Computed tomography scans on admission showing opacification of both the left sphenoid sinus (double arrow) and part of the frontal sinus (arrow). No intracranial abnormality is demonstrated especially around the basilar artery (arrowhead). B: Computed tomography scans showing no bony defect of the clivus.

caused by the sinusitis. Magnetic resonance (MR) imaging on day 5 revealed an enhanced mass surrounding the basilar artery at the angiographic stenosis in the prepontine cistern (Fig. 3). The mass was attached to the clivus, and the adjacent sphenoid sinus was also enhanced. There was an infarction in the left pons. Lumbar puncture found an opening pressure of 180 mmH₂O. Cerebrospinal fluid (CSF) analysis showed white blood cell count of 601/mm³ with 82% neutrophils, 89.2 mg/dl protein, and 31 mg/dl glucose. No causative organism in the CSF could be identified by smear or culture.

Continued improvement was observed during treatment with cefoperazone/sulbactam. Follow-up CT at 6 weeks revealed complete disappearance of

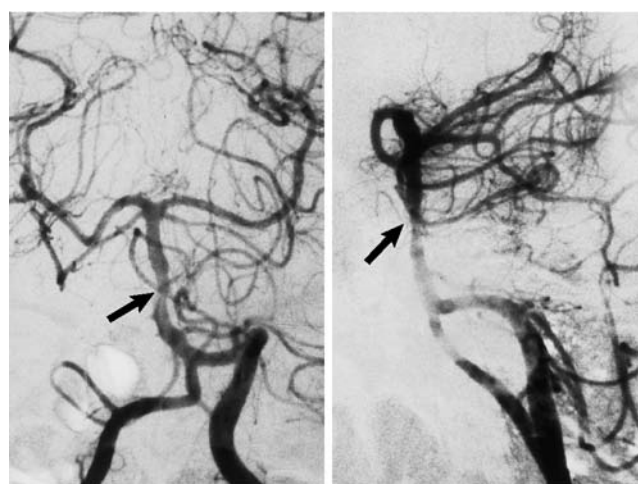


Fig. 2 Anteroposterior (left) and lateral (right) left vertebral angiograms revealing an eccentric stenosis at the middle portion of the basilar artery (arrow).

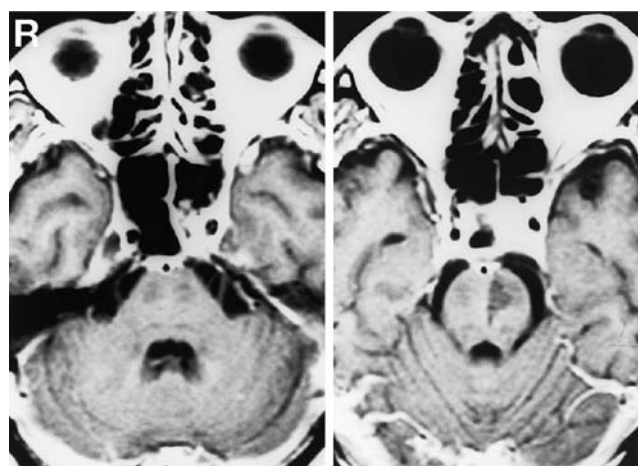


Fig. 3 Axial T₁-weighted magnetic resonance images with gadolinium on day 5 showing (left) an enhanced mass attached to the clivus in the prepontine cistern and embedding the basilar artery, with partial opacification of the left sphenoid sinus, and (right) a hypointense area consistent with ischemic infarction in the left pons.

the opacified sphenoid sinus. The patient's left abducens nerve palsy and left ataxia resolved by 8 weeks after the onset of the symptoms. The mass surrounding the basilar artery was still present in the prepontine cistern but MR imaging 6 months after the onset showed remarkable decrease in size (Fig. 4). The patient, who returned to work, was also followed up by the otolaryngologist for sphenoid sinusitis.

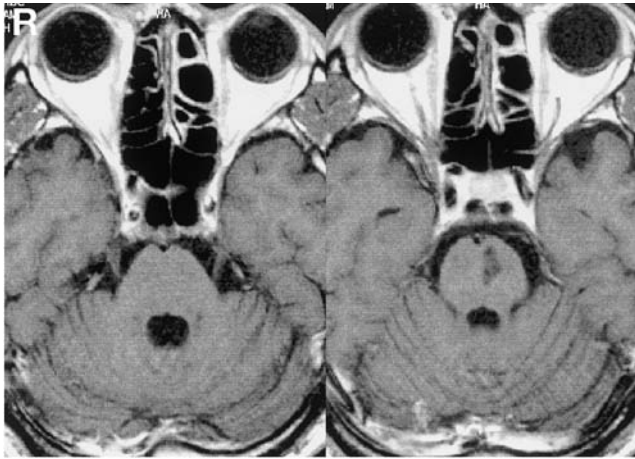


Fig. 4 Axial T₁-weighted magnetic resonance images with gadolinium 6 months after the onset showing the remarkably decreased mass surrounding the basilar artery.

Discussion

Meningitis is frequently found in patients with sphenoid sinusitis,^{3,6)} and cerebral ischemia is a common complication of bacterial meningitis.^{4,5,9-11,14,15)} A review of sphenoid sinusitis found that six of 15 patients with acute infection presented with meningitis.⁶⁾ Angiography showed vascular involvement in nine (33%) of 27 patients with bacterial meningitis presenting with complicated symptoms.¹⁴⁾ Transcranial Doppler sonography demonstrated significantly increased flow velocities in 23 (56%) of 41 patients with bacterial meningitis.⁴⁾ Hemodynamic disturbances associated with bacterial meningitis are less frequent and less severe in the posterior circulation than in the anterior circulation.¹¹⁾

In our case, CT showed sphenoid sinusitis at admission. However, the marked improvement of neurological deficits immediately after urokinase infusion without apparent meningeal sign initially obscured the correct diagnosis of basilar artery vasculitis until MR imaging demonstrated the mass embedding the basilar artery. No causative organism was identified in this case, but MR imaging indicated the pathogenesis of the initial neurological disturbance. Direct spread of infection through venous channels, osteomyelitic foci, or deficiencies in the sphenoid sinus wall into the adjacent preponine cistern is likely to lead to mass formation,^{1,3)} which may cause basilar artery stenosis and compromise perfusion through the perforating arteries. The absence of CT evidence of destruction of the clivus appeared to exclude deficiencies in the sphenoid sinus wall. The mass in the preponine cistern was most

likely an abscess based on the inflammatory findings in the CSF. Although our patient recovered completely, the correct diagnosis of meningitis and vasculitis should have been made in the early stage because the prognosis for sphenoid sinusitis with intracranial complications is poor.^{3,6)} Needle aspiration or open drainage of the sphenoid sinus is necessary if sinusitis does not respond to appropriate antibiotic therapy.^{3,6,8)} Early MR imaging and CSF examination are highly recommended when ischemic symptoms involving the basilar artery and opacification of the sphenoid sinus on CT are both present.

Our patient showed marked improvement of both progressive consciousness disturbance and right hemiparesis just after intra-arterial local infusion of urokinase. His consciousness disturbance and hemiparesis were attributed to brainstem ischemia, whereas the left abducens nerve palsy persisting after the procedure was considered to be caused by either brainstem ischemia or inflammation of the nerve over the clivus. Pontine infarction was previously found as an early manifestation of bacterial meningitis, and organizing thrombi were identified occluding the perforating branches of the basilar artery at autopsy.¹³⁾ We could not verify the presence of thrombi in the perforating arteries in our case. Vascular spasm caused by reaction in the vascular wall to the inflammatory response might have caused the ischemic symptoms. Therefore, the action of the urokinase infusion in the improvement of our case could not be determined. Recanalization of the perforating arteries^{18,19)} induced by local intra-arterial infusion of urokinase may have induced the marked improvement of neurological impairment, but the simultaneous fluid resuscitation may also have been responsible. Further investigations are required to clarify the efficacy and safety of intra-arterial thrombolytic therapy for acute ischemia without major artery occlusion.

References

- 1) Adams RD, Petersdorf RG: Pyogenic infections of the central nervous system, in Petersdorf RG, Adams RD, Braunwald E (eds): *Harrison's Principles of Internal Medicine*, ed 10. New York, NY, McGraw-Hill, 1983, pp 2084-2085
- 2) Devadiga KV, Mathai KV, Chandy J: Case reports and technical notes: Spontaneous cure of intracavernous aneurysm of the internal carotid artery in a 14-month-old child. *J Neurosurg* 30: 165-168, 1969
- 3) Dolan RW, Chowdhury K: Diagnosis and treatment of intracranial complications of paranasal sinus infections. *J Oral Maxillofac Surg* 53: 1080-1087, 1995
- 4) Haring HP, Rötzer HK, Reindle H, Berek K, Kampfl

- A, Pfausler B, Schmutzhard E: Time course of cerebral blood flow velocity in central nervous system infections. A transcranial Doppler sonography study. *Arch Neurol* 50: 98-101, 1993
- 5) Igarashi M, Gilmartin RC, Gerald B, Wilburn F, Jabbour JT: Cerebral arteritis and bacterial meningitis. *Arch Neurol* 41: 531-535, 1984
 - 6) Lew D, Southwich FS, Montgomery WW, Weber AL, Baker AS: Sphenoid sinusitis. A review of 30 cases. *N Engl J Med* 309: 1149-1154, 1983
 - 7) Macdonald RL, Findlay JM, Tator CH: Sphenothmoidal sinusitis complicated by cavernous sinus thrombosis and pontocerebellar infarction. *Can J Neurol Sci* 15: 310-313, 1988
 - 8) Miyazato M, Ohi T, Sugimoto S, Nagata N, Matsukura S: [Two cases of severe bacterial meningitis with paranasal sinusitis followed by cerebrovascular disease: Pathophysiology and treatment of cerebrovascular disease]. *Rinsho Shinkei* 36: 1083-1088, 1996 (Jpn)
 - 9) Müller M, Merkelbach S, Hermes M, König H, Schimrigk K: Relationship between short-term outcome and occurrence of cerebral artery stenosis in survivors of bacterial meningitis. *J Neurol* 245: 87-92, 1998
 - 10) Müller M, Merkelbach S, Huss GP, Schimrigk K: Clinical relevance and frequency of transient stenosis of the middle and anterior cerebral arteries in bacterial meningitis. *Stroke* 26: 1399-1403, 1995
 - 11) Müller M, Merkelbach S, Schimrigk K: Cerebral hemodynamics in the posterior circulation of patients with bacterial meningitis. *Acta Neurol Scand* 93: 443-449, 1996
 - 12) Nawashiro H, Shimizu A, Shima K, Chigasaki H, Kaji T, Doumoto E, Fuse Y: Fatal subarachnoid hemorrhage from an inflammatory cavernous carotid artery aneurysm: Failure of conservative treatment after early diagnosis. Case report. *Neurol Med Chir (Tokyo)* 36: 808-811, 1996
 - 13) Perry JR, Bilbao JM, Gray T: Fatal basilar vasculopathy complicating bacterial meningitis. *Stroke* 23: 1175-1178, 1992
 - 14) Pfister HW, Borasio GD, Dirnagl U, Bauer M, Einhäupl KM: Cerebrovascular complications of bacterial meningitis in adults. *Neurology* 42: 1497-1504, 1992
 - 15) Ries S, Schminke U, Fassbender K, Daffertshofer M, Steinke W, Hennerici M: Cerebrovascular involvement in the acute phase of bacterial meningitis. *J Neurol* 244: 51-55, 1997
 - 16) Robert WH, Choi IS, Persky M, Kupersmith M: Mycotic aneurysms of the intracavernous carotid artery: A case report and review of the literature. *Surg Neurol* 37: 142-146, 1992
 - 17) Rout D, McAnn PK, Rao VRK: Bacterial aneurysms of the intracavernous carotid artery: Case report. *J Neurosurg* 60: 1236-1242, 1984
 - 18) Sáez-Llorens X, Ramilo O, Mustafa MM: Molecular pathophysiology of bacterial meningitis: current concepts and therapeutic implications. *J Pediatr* 116: 671-684, 1990
 - 19) Tunkel AR, Wispelwey B, Scheld WM: Bacterial meningitis: recent advances in pathophysiology and treatment. *Ann Intern Med* 112: 610-623, 1990
-
- Address reprint requests to: T. Sorimachi, M.D., Department of Neurosurgery, Nishiogi Central Hospital, 2-5-5 Nishiogi-kita, Suginami-ku, Tokyo 167-0042, Japan.