

# Calcified Cysticerci Provoke Perilesional Edema and Seizures

Theodore E. Nash,<sup>1</sup> Javier Pretell,<sup>2</sup> and Hector H. Garcia<sup>3</sup>

<sup>1</sup>Laboratory of Parasitic Diseases, National Institutes of Allergy and Infectious Diseases, National Institutes of Health, Bethesda, Maryland; and <sup>2</sup>Cysticercosis Unit, Instituto de Ciencias Neurológicas and <sup>3</sup>Departments of Microbiology and Pathology, Universidad Peruana Cayetano Heredia and Cysticercosis Unit, Instituto de Ciencias Neurológicas, Lima, Peru

**In cases of cysticercosis, seizures and other symptoms occur in persons with only calcified brain lesions. The presence of perilesional edema has been documented in association with calcified lesions in symptomatic patients, but the frequency of this complication and characteristics of the patients who develop it are not known. Patients in Peru and the United States with neurocysticercosis, documented by positive results of serological testing and with only calcified lesions as shown using computerized tomography, were studied using magnetic resonance imaging. Perilesional edema was observed in slightly more than one-third of the patients, and some patients had frequent, severely disabling episodes. Those with an increased proportion of enhancing calcified lesions were more likely to show perilesional edema. Edema around calcified lesions is common in this population and is associated with seizures and neurological morbidity.**

Cysticercosis, an infection of the larval form of the tapeworm *Taenia solium*, is a major cause of seizures in much of the developing world [1]. Seizures due to cysticercosis usually occur in 1 of 3 circumstances. In the first, dying cysts incite an inflammatory response [2]. MRI and CT imaging characteristically show  $\geq 1$  cystic lesions with edema and enhancement [1]. Pathologic examination reveals varying degrees of acute and chronic inflammation and microabscess formation [3–5]. The second instance has only recently been recognized. MRI and CT imaging reveal  $\geq 1$  calcified degenerated cysticerci with perilesional edema and enhancement surrounding  $\geq 1$  foci [6–11]. A handful of

patients with perilesional edema around calcified lesions have been fully described. However, from the initial description, it is evident that clinical symptoms commonly correlate with the locus of edema [2, 11] and the process is intermittent and recurring [7, 11]. There is anecdotal evidence that it responds to treatment with corticosteroids but also regresses spontaneously. In the third instance, imaging studies that use commonly employed techniques do not show either enhancement or edema. In a number of instances in which subtle changes are noted, such as minor increases in edema or enhancement, it is impossible to decide whether changes were caused by technical factors or subtle pathological changes.

The clinical significance of recurring perilesional edema associated with calcified lesions is not known, but it could be significant. First, because these patients have only dead lesions, they would not be expected to benefit from antiparasitic treatment; nevertheless, cysticercosis refractory to medical therapy is frequently diagnosed, and the patients undergo multiple unnecessary courses of therapy. Second, most, if not all, of the viable cysticerci become calcified, and these lesions will likely persist for the life of the patient. Third, in endemic populations, cerebral calcifications due to cys-

Received 9 April 2001; revised 25 May 2001; electronically published 5 October 2001.

Appropriate informed consent was obtained, and research was conducted in accordance with guidelines for human experimentation as specified by the United States Department of Health and Human Services.

This study was funded by National Institutes of Allergy and Infectious Diseases intramural funds (grant FDR001107) from the United States.

Reprints or correspondence: Dr. Theodore E. Nash, National Institutes of Health, 9000 Rockville Pike, Bldg. 4, Rm. B1-06, Bethesda, MD 20892 (Tnash@niaid.nih.gov).

**Clinical Infectious Diseases** 2001;33:1649–53

© 2001 by the Infectious Diseases Society of America. All rights reserved.  
1058-4838/2001/3310-0005\$03.00

ticercosis are the most common radiological findings [12–16]. Thus, it is possible that a significant proportion of seizures that occur in cysticercosis are because of this phenomenon.

To document the frequency of perilesional edema associated with calcifications and to characterize the patients affected, patients in Peru and the United States with only calcified lesions (as determined by CT examination and positive results of serological testing for cysticercosis) underwent MRI either as a baseline examination or at the time symptoms recurred. We found that this phenomenon is common and sometimes profoundly disabling.

## MATERIALS AND METHODS

Patients in Peru were studied at the Infectious Disease Unit of the Instituto de Ciencias Neurológicas (Lima). We included patients with known cysticercosis who showed only calcified cysticerci on CT examinations, no viable or degenerating cysts on subsequent MRI examinations, and positive results of serological examinations. Patients were brought to the attention of the authors in a number of ways. Some patients were prospectively followed-up after a trial of medical treatment for cysticercosis or were being managed for seizures due to cysticercosis. Others were referred by physicians and neurologists who were aware of the expertise and interest of the Infectious Disease Unit. In Peru, most patients had previously undergone CT examinations; MRI studies were performed in the present context for a variety of symptoms, but most were performed for seizures and headaches. MRI examinations in Peru and the United States included standard T1-weighted spin echo without contrast, T2-weighted (fast spin echo), fast fluid attenuated inversion recovery (FLAIR), T1-weighted with contrast, spoiled gradient-recalled echo with contrast, and magnetization transfer. The FLAIR technique was the most sensitive for the detection of the presence of edema; we considered perilesional edema to be present if the size of the signal when the FLAIR technique was used was  $\geq 2$  times the diameter of the calcified focus. A single CT examination had usually been performed earlier as part of the patient's initial evaluation. In the United States, patients were referred for refractory cysticercosis unresponsive to medical therapy. After baseline MRI and CT examinations, they were followed-up prospectively and reevaluated at the time symptoms reoccurred.

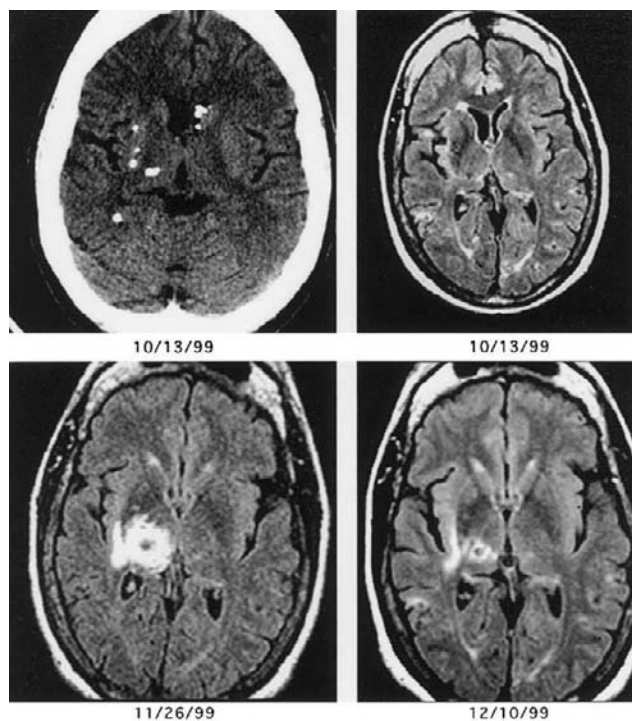
For statistical evaluations, we used Fisher's exact test and the Mann-Whitney *U* test.

## RESULTS

**Case 1.** A 48-year-old woman who was born in the United States was referred to the National Institutes of Health (NIH; Bethesda, Maryland) for cysticercosis refractory to medical

therapy. The patient was in India from 1955 to 1956 and again from 1968 to 1970. She experienced her first generalized seizure in 1969. Around this time, both she and her boyfriend were found to have taeniasis due to *T. solium*. She continued to have seizures in the early 1970s, and she had 1 episode of dysesthesia on the left side in 1976.

The patient was healthy until 1986, when she developed fever, multifocal seizures, and bilateral dysesthesias. CT examination revealed multiple calcified and cystic lesions that suggested the diagnosis of cysticercosis. The results of serological tests were positive for cysticercosis, and she was treated with praziquantel for 4 weeks. By 1987, no cystic lesions remained, but 55 residual calcified cysticerci were seen scattered throughout the brain. From then until September 1999, the patient's course was one of varying neurological signs and symptoms, including seizures evaluated with multiple MRI examinations that demonstrated perilesional edema associated with 1–5 calcified lesions. Because of this, she was treated with multiple courses of anticysticidal therapy. She was first seen at the NIH in October 1999. Neurological examination revealed a flattened, right facial labial fold and dysmetria of the right arm. Baseline MRI showed no perilesional edema (figure 1; 13 October 1999). In November 1999, she complained of new-onset left-side coldness and decreased sensation. An MRI showed a large area of perilesional edema in the right thalamus (figure 1; 26 November 1999) and



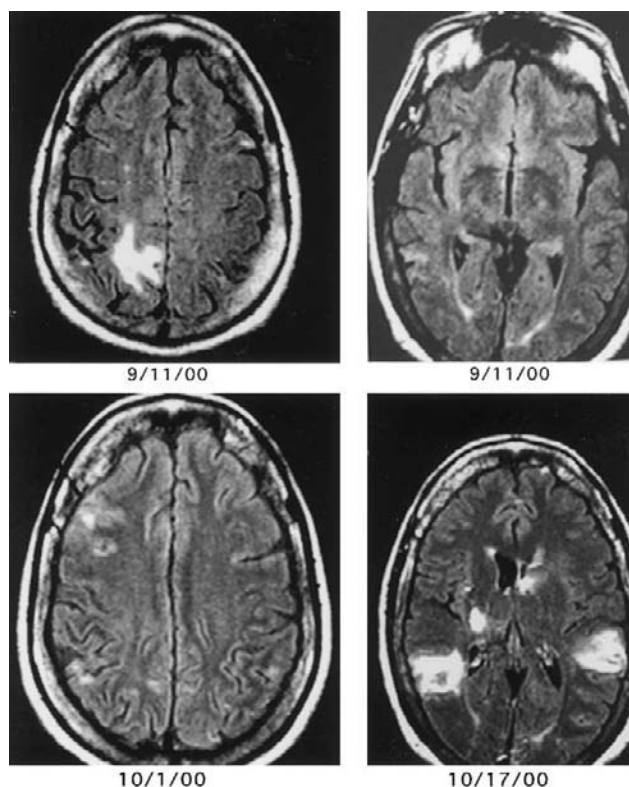
**Figure 1.** Baseline CT scan demonstrating a dense calcification in the right thalamus as well as other calcification (left upper panel) and MRI images that used fast fluid attenuated inversion recovery (other panels).

a smaller area in the right frontal lobe, both of which regressed after 2 weeks of therapy with 16 mg of dexamethasone per day (figure 1; 10 December 1999). The same symptoms had occurred before, and in retrospect, they correlated with edema in the right thalamus.

In April 2000, the patient presented with a burning sensation of the left lateral foot, and a new MRI showed a moderate area of perilesional edema in the right parietal area. The edema associated with the focus in the thalamus resolved. Symptoms improved without specific therapy. She was healthy until August, when she complained of an episode of aphasia. An MRI showed a large area of perilesional edema around a focus in the left Wernicke's area. The symptoms gradually improved. A follow-up MRI performed ~3 weeks later unexpectedly revealed that the edema in the left side of the brain had resolved, but a new region of edema associated with 2 calcifications in the right parietal area was now present (figure 2; 11 September 2000). At this time, the patient experienced spatial disorientation, and a course of iv steroids was administered at another hospital. On 1 October 2000, she had a grand mal seizure temporally related to a change in antiseizure medication. MRI at another facility showed no significant regions of edema (figure 2; 1 October 2000), but a 1-week course of iv corticosteroids was administered. Approximately 2.5 weeks later, the patient was not able to write legibly and her gait was unsteady. MRI examination now showed 6 new large areas of perilesional edema (figure 2; 17 October 2000) that dramatically improved by early November while the patient was receiving oral dexamethasone.

In late December, the patient experienced a generalized seizure after an episode of aphasia. MRI showed recurrence of the edema in left Wernicke's area, prompting one more course of albendazole at another hospital. Dexamethasone, which had been slowly tapered, was increased with normalization of the edema during the subsequent weeks and symptomatic improvement. As of October 2001, the patient is no longer taking corticosteroids; she has had no neurological complaints while receiving adequate levels of antiseizure medications and oxcarbamazine as of May 2001.

Twenty-nine patients were evaluated in Peru (table 1) during a period of 15 months. The mean patient age ( $\pm$ SD) was  $39.6 \pm 15.7$  years (range, 17–72 years), and there were 21 female and 8 male patients. Of these 29 patients, 10 (34.5%) showed perilesional edema around 1–4 calcified foci on  $\geq 1$  occasion. Those with perilesional edema had a greater proportion of lesions with enhancement (mean proportion of lesions with enhancement  $\pm$  SD,  $65.9\% \pm 28.6\%$  vs.  $11.7\% \pm 22.9\%$ ;  $P < 0.003$ ); 9 of 9 patients with perilesional edema showed enhancement, versus 7 of 18 patients who did not show perilesional edema ( $P = 0.003$ ). Patients with a history of seizures ( $P = 0.068$ ),  $>20$  calcifications ( $P = 0.083$ ), male sex ( $P = 0.083$ ), seizure as a presenting symptom that provoked



**Figure 2.** MRI images at the indicated dates that used fast fluid attenuated inversion recovery

an MRI examination ( $P = 0.096$ ), and an MRI examination  $<2$  weeks after the presenting symptom ( $P = 0.2870$ ) were more likely to show perilesional edema, but not significantly so. There were no associations with age or duration of disease and perilesional edema.

The presence of contrast enhancement was strongly associated with the number of calcifications ( $P = 0.003$ ) and a history of seizures ( $P = 0.004$ ), but it was not strongly associated with seizures as the presenting episode or the patient having been studied within 2 weeks of the presenting symptom. There was a significant association between a longer duration of illness and the presence of enhancement ( $P = 0.048$ ). Contrast enhancement was not associated with age or sex.

Of 8 patients with neurocysticercosis seen at the NIH during a 15-month period, 2 (25%) had perilesional edema associated with calcified lesions exclusively. Another patient had recurring seizures associated with a barely calcified, enhancing lesion that demonstrated perilesional edema at the time of seizure activity. During a 15-month period, the lesion became densely calcified with minimal enhancement. The course is suggestive of a resolving granuloma that was in the process of calcification.

Three patients in Peru and 1 patient at the NIH were studied on multiple occasions. Three demonstrated perilesional edema that regressed and the appearance of other lesions associated with

**Table 1. Characteristics of patients with calcified cysticerci.**

Patient number	Age, years	Sex	Symptoms (duration, months)	Symptom provoking study	Time before MRI, days	Date of MRI	No. of calcifications	No. (%) of CE	No. with edema
1	72	F	Seizures and headaches (120)	Headache	Chronic	27 Nov 1999	11	7 (64)	3
2	19	M	Seizures (24)	Seizure	5	25 Apr 2000	5	5 (100)	1–2
3	31	F	Seizures (108)	Seizure	5	11 May 2000	9	3 (33)	1–2
4	18	M	Seizures (48)	Seizure	12	17 Oct 2000	4	1 (25)	2
5	38	M	Seizures (216)	Seizure	1	25 Nov 2000	35	15 (43)	4
6	65	M	Seizures (36)	Seizure	60	7 Feb 2001	21	17 (81)	3
7	46	F	Seizures (264)	Seizure	9	10 Mar 2001	4	4 (100)	2
8	35	M	Seizures (121)	Seizure	9	16 Mar 2001	28	ND	2
9	27	F	Seizures (60)	Seizure	18	13 Mar 2001	60	60 (100)	1
10	54	F	Seizures (168)	No current seizure	270	16 Oct 2000	53	25 (47)	1
11	24	F	Seizures (72)	Seizure	5	10 Jan 2000	14	11 (79)	0
12	39	F	Seizures (7)	Headache	Chronic	11 Jan 2000	83	44 (53)	0
13	32	M	Seizures (48)	Seizure	5	31 Jan 2000	14	1 (7)	0
14	47	F	Dizziness (36)	Headache	Chronic	2 May 2000	5	0 (0)	0
15	52	F	Seizures and headaches (300)	Seizure	7	7 Sep 2000	99	1 (1)	0
16	17	F	Seizures (24)	Seizure	5	19 Oct 2000	12	0 (0)	0
17	40	F	Seizures (396)	Seizure	30	9 Nov 2000	25	1 (4)	0
18	41	F	Seizures (168)	Headache	Chronic	17 Nov 2000	6	1 (17)	0
19	64	F	Dizziness (33)	Dizziness	Chronic	11 Dec 2000	10	0 (0)	0
20	21	F	Seizures (72)	Pseudoseizure	1	3 Jan 2000	5	0 (0)	0
21	22	M	Seizures (20)	Seizure	700	5 Jan 2001	2	0 (0)	0
22	38	F	Seizures (120)	Headache	Chronic	12 Jan 2001	2	1 (50)	0
23	35	F	Headaches (Ind)	Headache	Chronic	24 Feb 2001	2	ND	0
24	35	F	Migraine (108)	Migraine	1	13 Mar 2001	4	0 (0)	0
25	64	F	Seizures (84)	Seizure	16	16 Mar 2001	1	0 (0)	0
26	43	F	Seizures (168)	Seizure	30	19 Mar 2001	4	0 (0)	0
27	46	F	Headaches (36)	Headache	Chronic	28 Mar 2001	1	0 (0)	0
28	62	M	Headaches (9)	Headache	Chronic	13 Feb 2000	5	0 (0)	0
29	21	F	Seizures (60)	Seizure	8	21 Mar 2001	1	0 (0)	0

**NOTE.** CE, calcifications with enhancing; Chronic, long-lasting or recurring; Ind, indeterminate.

new symptoms. Three patients, on at least 1 occasion, showed regression of perilesional edema without use of corticosteroids.

## DISCUSSION

This report is the first to focus on the presence and frequency of perilesional edema around calcified cysticerci and the characteristics of those patients who present with this complication. Perilesional edema around degenerated calcified cysticerci has been noted elsewhere in a few case reports and has been briefly commented on in reported series [6–11]. However, the frequency and importance of this finding in populations are unclear. The ease of identifying patients both in Peru and the United States suggests that this is a relatively common phenomenon and that it is a significant cause of morbidity in endemic populations. We evaluated persons with and without current symptoms who had  $\geq 1$  calcified lesion and positive

results of serological testing who came to our attention in Peru during a 15-month period, and we found that 10 (34.5%) of these 29 patients had perilesional edema. In addition, 2 (25%) of 8 patients who had been referred to the NIH with any type of cysticercosis also had this complication. However, 34.5% is probably an underestimation for a number of reasons. Approximately half of the patients were studied either for chronic symptoms or at a time relatively distant from their precipitating complaint. These patients were less likely to show perilesional edema. Also, patients who demonstrated calcified lesions with perilesional edema who also had any cystic lesions were excluded. Finally, patients for whom the results of serological testing were negative for cysticercosis, but who had calcified lesions and perilesional edema, were also excluded, although these patients would probably have cysticercosis diagnosed. Because of the manner in which these patients came to our attention, this is only an approximate estimate for all persons

with only calcified lesions or calcified lesions and seizures who develop this complication. A prospective study is in progress.

Why only certain patients and only certain lesions in these patients are prone to this complication is not known. Patients with perilesional edema had a higher proportion of enhancing lesions. Contrast enhancement is relatively common around calcified cysticerci and almost always present with perilesional edema. Many lesions with enhancement do not demonstrate perilesional edema; thus, it appears that enhancement is a necessary but not a sufficient requirement at the time of presentation. This may suggest that certain hosts and/or particular lesions are more prone to perilesional edema. In the present study, patients have not been followed-up prospectively to know whether prior enhancement of a particular lesion is always present before an episode of perilesional edema. However, in the few patients followed-up prospectively, this appears to be the case.

Studies in India suggested that patients with single lesions, including calcified lesions, who had seizures refractory to treatment were more likely to have “gliosis” as shown by MRI magnetization transfer [17, 18]. None of our patients showed signals comparable to those described by these authors. In another report, 6 of 16 patients with calcified lesions showed enhancing calcified lesions, and 3 of these continued to have seizures [19]. In contrast, in our study, only 3 of 10 patients without enhancing lesions had continued seizure activity. Although perilesional edema was not mentioned in that report, the findings in that report are consistent with our observation that patients with enhancing lesions have an increased tendency to experience seizures and perilesional edema.

Four patients showed perilesional edema apparently unrelated to their complaints. One patient complained of longstanding headaches without current exacerbation, and the other 3 were studied from 18 days to 9 months after their last seizures. We observed 2 instances in which large regions of edema were found in asymptomatic patients [7] (and case 1). Therefore, a certain number of silent edematous lesions are to be expected, as illustrated from these examples.

Case 1 and 2 patients from Peru were studied on multiple occasions [11]. These, as well as other reported cases [7, 11], illustrate that patients can experience frequent episodes in which  $\geq 1$  of the calcified foci may be associated with disabling seizure activity or other symptoms. These may be difficult to control, and they may be prolonged and severely disabling. Corticosteroids have been used with apparent success, but recurrent perilesional edema and/or seizures have occurred when the dose was lowered. Although it is speculated that edema results from an inflammatory process directed at sequestered parasitic antigens [7, 10], exactly what causes this is unknown. Indeed, if the pathophysiology is due to inflammation, then

specific measures to limit the inflammatory process may be used to treat or prevent this complication.

## Acknowledgments

We thank Dr. Marianne Schuelein for shared care and referral of a patient, Dr. William Theodore for advice in seizure management, and Dr. Nicholas J. Patronas for interpretation of radiological examinations. We also thank Sheryl Rathke for editorial advice.

## References

1. White AC. Neurocysticercosis: updates on epidemiology, pathogenesis, diagnosis, and management. *Annu Rev Med* **2000**; 51:187–206.
2. Nash TE, Neva FA. Recent advances in the diagnosis and treatment of cerebral cysticercosis. *N Engl J Med* **1984**; 311:1492–6.
3. Henneberg R. Die Tierischen Parasiten des Zentralnerven-Systems. In: Lewandowsky M, ed. *Handbuch Der Neurologie*. Berlin: Verlag Von Julius Springer, **1912**:643–712.
4. de Aluja AS, Gonzalez D, Rodriguez Carbajal J, et al. Histological description of tomographic images of *Taenia solium* cysticerci in pig brains [see comments]. *Clin Imaging* **1989**; 13:292–8.
5. Trelles OJ, Palomino L. Histopathology of cerebral cysticercosis. In: Bogaert LV, Kafer JP, Poch GF, eds. *Tropical neurology*. Buenos Aires: Libreros Editores, **1961**:162–81.
6. Nash TN. Issues and controversies in cysticercosis. In: Peterson PK, Remington JS, eds. *Defense of the brain*. Malden, MA: Blackwell Science, **1997**:205–17.
7. Nash TE, Patronas NJ. Edema associated with calcified lesions in neurocysticercosis. *Neurology* **1999**; 53:777–81.
8. Del Brutto OH. Prognostic factors for seizure recurrence after withdrawal of antiepileptic drugs in patients with neurocysticercosis. *Neurology* **1994**; 44:1706–9.
9. Garg RK, Karak B, Mohan Kar A. Neuroimaging abnormalities in Indian patients with uncontrolled partial seizures. *Seizure* **1998**; 7:497–500.
10. Sheth TN, Lee C, Kucharczyk W, et al. Reactivation of neurocysticercosis: case report. *Am J Trop Med Hyg* **1999**; 60:664–7.
11. Park SY, Barkovich AJ, Weintraub PS. Clinical implications of calcified lesions of neurocysticercosis. *Pediatr Infect Dis J* **2000**; 19:581–3.
12. Cruz ME, Schantz PM, Cruz I, et al. Epilepsy and neurocysticercosis in an Andean community. *Int J Epidemiol* **1999**; 28:799–803.
13. Sanchez AL, Lindback J, Schantz PM, et al. A population-based, case-control study of *Taenia solium* taeniasis and cysticercosis. *Ann Trop Med Parasitol* **1999**; 93:247–58.
14. Palacio LG, Jimenez I, Garcia HH, et al. Neurocysticercosis in persons with epilepsy in Medellin, Colombia. The Neuroepidemiological Research Group of Antioquia. *Epilepsia* **1998**; 39:1334–9.
15. Sarti E, Schantz PM, Avila G, et al. Mass treatment against human taeniasis for the control of cysticercosis: a population-based intervention study. *Trans R Soc Trop Med Hyg* **2000**; 94:85–9.
16. Garcia-Noval J, Allan JC, Fletes C, et al. Epidemiology of *Taenia solium* taeniasis and cysticercosis in two rural Guatemalan communities. *Am J Trop Med Hyg* **1996**; 55:282–9.
17. Gupta RK, Kathuria MK, Pradhan S. Magnetization transfer magnetic resonance imaging demonstration of perilesional gliosis-relation with epilepsy in treated or healed neurocysticercosis. *Lancet* **1999**; 354:44–5.
18. Pradhan S, Kathuria MK, Gupta RK. Perilesional gliosis and seizure outcome: a study based on magnetization transfer magnetic resonance imaging in patients with neurocysticercosis. *Ann Neurol* **2000**; 48:181–7.
19. Sheth TN, Pilon L, Keystone J, et al. Persistent MR contrast enhancement of calcified neurocysticercosis lesions. *Am J Neuroradiol* **1998**; 19:79–82.