

Radiosurgery-induced brain tumor

Case report

TAKANOBU KAIDO, M.D., TOHRU HOSHIDA, M.D., RYUNOSUKE URANISHI, M.D., NOBUHISA AKITA, M.D., AKIHIRA KOTANI, M.D., NORIYUKI NISHI, M.D., AND TOSHISUKE SAKAKI, M.D.

Department of Neurosurgery, Nara Medical University, Nara, Japan

✓ The authors describe a case of glioblastoma multiforme (GBM) associated with previous gamma knife radiosurgery for a cerebral arteriovenous malformation (AVM). A 14-year-old boy had undergone radiosurgery for an AVM, which was performed using a 201-source ⁶⁰Co gamma knife system at another institution. The maximum and margin radiation doses used in the procedure were 40 and 20 Gy, respectively. One year after radiosurgery, the patient noticed onset of mild left hemiparesis due to radiation necrosis.

Six and one-half years after radiosurgery, at the age of 20 years, the patient experienced an attack of generalized tonic-clonic seizure. Magnetic resonance (MR) imaging revealed the existence of a brain tumor in the right parietal lobe. The patient underwent an operation and the histological diagnosis of the lesion was GBM. Ten months following the operation, that is, 99 months postradiosurgery, this patient died.

To the best of the authors' knowledge, this is the first reported case of a neoplasm induced by radiosurgery for an AVM and the second case in which it occurred following radiosurgery for intracranial disease.

KEY WORDS • gamma knife surgery • radiosurgery • arteriovenous malformation • tumor induction • glioblastoma multiforme

RADIOSURGERY, or stereotactically focused irradiation, was initially used for intractable pain by Leksell⁸ in 1968. In 1970, Steiner and associates²¹ introduced the gamma knife for treatment of cerebral AVMs. Recently, radiosurgery has been widely used not only to treat AVMs, but also to treat brain tumors, intractable pain, neuralgia, Parkinson disease, and epilepsy. It is considered to be a relatively safe procedure, but there is still a risk of radiation necrosis as well as incomplete obliteration and bleeding before complete obliteration of the nidus of the AVM.^{4,24} In addition, Yu, and colleagues²⁵ recently reported the first case of GBM induction following radiosurgery for a meningioma. These authors suggested there would be further reports of tumor induced by radiosurgery. In the present report, we relate a fatal case of GBM that was induced by radiosurgery for an AVM.

Case Report

History. This 4-year-old boy came to our institution in May 1982 suffering from occipitalgia and vomiting. A computerized tomography scan revealed intraventricular hemorrhage in both lateral ventricles and acute hydrocephalus; a ventricular drain was placed. Angiography performed after this operation revealed an AVM in the right parietal lobe. The AVM involved the posterior rim of the right internal capsule and drained into the internal cerebral vein. The largest diameter of the nidus was 29 mm.

Abbreviations used in this paper: AVM = arteriovenous malformation; GBM = glioblastoma multiforme; GFAP = glial fibrillary acidic protein; MR = magnetic resonance.

Surgery was recommended, but his parents refused. Three weeks later, he underwent ventriculoperitoneal shunt placement for hydrocephalus and was discharged from our facility with no adverse effect, without undergoing surgery for his AVM.

During the time of follow up in this case radiosurgical therapy was introduced to Japan. In accordance with our recommendation that such a method could provide a less invasive therapy, in 1992, when the patient was 14 years of age, he underwent radiosurgery for his AVM (Fig. 1 *upper* and *center*). The procedure was performed at another institution by using a 201-source ⁶⁰Co gamma knife system. The maximum and margin radiation doses were 40 and 20 Gy, respectively. One year following radiosurgery, the patient experienced onset of mild left hemiparesis due to radiation necrosis in the right cerebral white matter. After conservative therapy, he was followed up at an outpatient clinic. Angiography performed 2 years after radiosurgery revealed complete occlusion of the AVM (Fig. 1 *lower*).

The patient experienced a gradual onset of headaches, vomiting, and worsening of his left hemiparesis 75 months postradiosurgery. Four months later, at the age of 20 years, he experienced an attack of generalized tonic convulsion.

Examination and Treatment. Magnetic resonance imaging revealed brain swelling and a small intracerebral hematoma in the patient's right parietal lobe. Angiography demonstrated a small faint vascular stain. Based on these findings, the lesion was diagnosed as radiation necrosis and hemorrhage from the residual nidus of the AVM. The patient underwent conservative therapy. In January 1999, more than 4 months later, he noted onset of headache and vomiting again. Cranial MR imaging revealed significant

Radiosurgery-induced tumor

brain swelling and hemorrhage compared with those noted on images obtained just before the radiation treatment (Fig. 2 *left and center*). Moreover, he experienced tonic-clonic seizures. His consciousness level gradually worsened and he fell into a semicomatose state. After undergoing emergency angiography, which revealed tumor staining, the patient underwent an operation for removal of the hematoma and tumor.

In spite of postoperative chemotherapy, which consisted of 1-[4-amino-2-methyl-5-pyrimidinyl]-methyl-3-[2-chloroethyl]-3-nitrosourea hydrochloride and interferon β , the residual tumor continued to grow and the general condition of the patient gradually worsened. Ten months after the operation (Fig. 2 *right*), that is, 99 months postradiosurgery, the patient died.

Pathological Findings

The histological diagnosis of the tumor was GBM. The tumor displayed high cellularity and focal necrosis (Fig. 3 *upper left and right*). There was also thickening of the wall of the vessels that had constituted the AVM (Fig. 3 *upper and lower left*). Immunohistochemical investigation yielded a positive response to anti-GFAP within the cytoplasm of the cells (Fig. 3 *lower right*).

Discussion

To our knowledge, we report the first case in which a neoplasm was induced by radiosurgery for AVM, and the second case in which this occurred after radiosurgery for intracranial disease.

The underlying goal of treatment of AVMs by using radiation is to induce an inflammatory response in the vessel walls of the malformation that will result in a permanent thickening of the pathological vascular channels, ultimately leading to thrombosis.¹³ In this case, the complete obliteration of the AVM was confirmed on angiography. Furthermore, thickening of the walls of the abnormal vessels was shown by histological analysis. Nevertheless, GBM was also found around these abnormal vessels.

Brain tumor induced by radiotherapy has been reported to occur in response to both low and high radiation doses.^{2,5,6,9-12,15,17,19,20} In previous cases, the presence of various primary diseases before conventional radiotherapy have been reported, such as brain tumor (meningioma, pituitary adenoma, craniopharyngioma, medulloblastoma, metastatic tumor, and teratoma), retinoblastoma, tinea capitis, glomus jugulare tumor, and leukemia. Various types of induced tumors have also been reported, such as astrocytoma, GBM, sarcoma, ependymoma, and meningioma. Since the introduction of radiosurgery, however, no tumors have been observed to have been induced by the treatment. One may speculate that ionizing beams delivered over a long period are more likely to induce tumors than single high doses given over a short period.²²

The following criteria for radiation-induced neoplasms^{1,12,18,21} have been previously described: 1) a second tumor occurs within the field of irradiation used to treat the primary disease; 2) the tumor is not present prior to irradiation, and there has been a reasonable interval between radiotherapy and the detection of the second tumor (usually several years); 3) a histological difference exists between

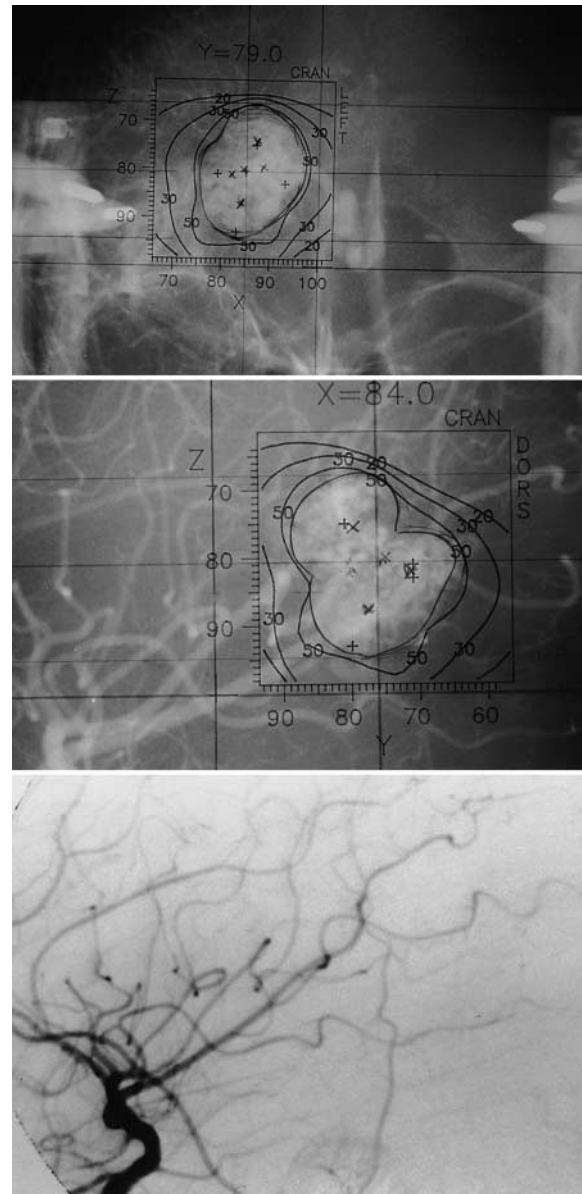


FIG. 1. Anteroposterior (*upper*) and lateral (*center and lower*) angiograms. *Upper and Center*: Angiograms obtained at the time of radiosurgery. *Lower*: Angiogram obtained 24 months after radiosurgery demonstrating that the AVM has been obliterated.

the primary and subsequent tumor; and 4) no known genetic or predisposing conditions to secondary malignancy are observed. Our case fulfills these criteria. There is no possibility that there was a change in tumor type or that induction was caused by chemotherapy with any anticancer agent that may have exerted a carcinogenic effect, because AVM is not a kind of neoplasm.

Radiation-induced gliomas seemed to differ from spontaneous gliomas.^{6,20} First, the pathological nature of radiation-associated gliomas is generally malignant. Second, these tumors tend to occur in young patients, despite the fact that the majority of gliomas are located in the cerebral hemisphere. Kitanaka and associates⁶ reviewed 35 cases of radiation-induced gliomas. The tumor dose ranged from 4

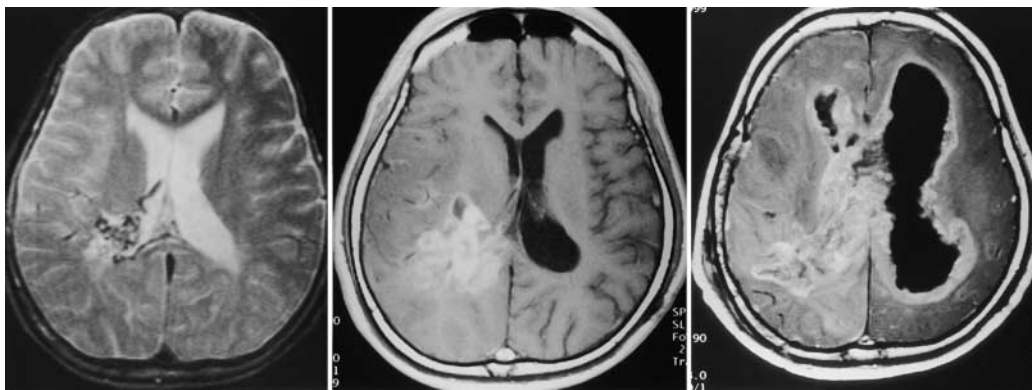


FIG. 2. Axial T₂-weighted (*left*) and gadolinium-enhanced T₁-weighted (*center and right*) MR images. *Left*: Preradiosurgery MR image revealing an AVM in the right parietal lobe. *Center*: An MR image obtained 81 months after radiosurgery, demonstrating an enhanced mass lesion in the right parietal lobe. *Right*: An MR image obtained 99 months after radiosurgery (9 months after removal of the tumor) and 6 days before the death of the patient, demonstrating severe invasion and dissemination of tumor.

to 60 Gy (mean 39 Gy). The age of the patients at the time of radiotherapy ranged from 2 weeks to 52 years (mean 15 years), and the latency periods extended from 1 to 26 years (mean 11 years). The patients' mean age at the onset of the second tumor was 26 years. Shapiro, et al.,¹⁹ suggested that

the skewed age distribution toward youth for tumor induction was due to the fact that young patients underwent cranial radiation treatment for a variety of reasons.

In the present case, the patient displayed an onset of radiosurgery-induced glioma at the age of 20 years. The

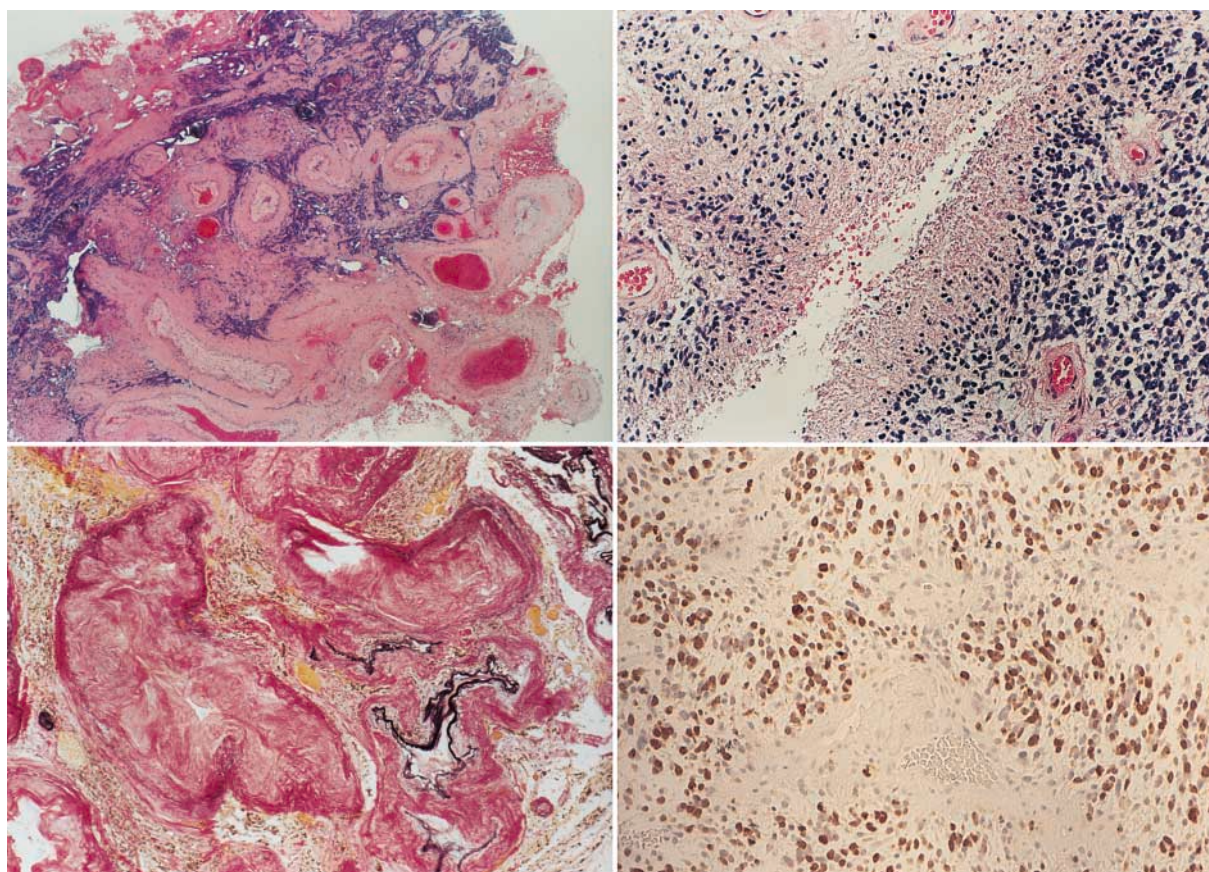


FIG. 3. Photomicrographs of tumor sections showing histopathological and immunohistochemical findings. *Upper and Lower Left*: Significant intimal hypertrophy is observed in the abnormal vessel wall. Original magnification $\times 100$. *Upper Right*: There is focal necrosis with pseudopalisading. Original magnification $\times 200$. *Lower Right*: Tumor cells stain positively in response to anti-GFAP antibody. Original magnification $\times 400$. H & E (*upper left and right*); elastic van Gieson (*lower left*); and immunohistochemical testing for GFAP (*lower right*).

Radiosurgery-induced tumor

latency period was 6.5 years. Moreover, this tumor was malignant and the characteristics of the tumor closely resembled the previously mentioned criteria for radiation-induced gliomas.

It is hardly a consideration that the GBM in this case was a natural comorbidity associated with the AVM. In a previous report¹⁴ the authors mentioned rare cases in which there has been simultaneous occurrence of an AVM and a glioma, assigning the term "angioglioma." In the present case, however, there was a long interval of 16 years between the first diagnosis of the AVM and the second diagnosis of GBM. Moreover, this case fulfilled the criteria for radiation-induced neoplasms described earlier.

Yu and colleagues²⁵ reported the first documented case, that of a 70-year-old woman, of GBM induced by radiosurgery. In that case, the GBM occurred 7 years after radiosurgery in the same area as the previous meningioma. On the other hand, authors of another study⁷ reported that there have been many cases with comorbidity of multiple primary brain tumors of different histological types not associated with von Recklinghausen disease or a history of radiation treatment. The most frequent combinations were meningioma and glioma. We do not deny that the lesion reported by Yu and colleagues was a neoplasm induced by radiosurgery, because their case also completely fulfilled the criteria for radiation-induced neoplasms described earlier. Nevertheless, there is some possibility that the second neoplasm in that case was not induced by radiosurgery, but occurred as an incidental comorbidity.

Stieg, et al.,²³ mentioned several potential complications that occur after stereotactic radiosurgery for AVMs such as hemorrhage prior to lesion obliteration, temporary radiation effects, radiation necrosis, and predicted secondary tumors. Our patient experienced radiation necrosis 1 year after undergoing radiosurgery. Friedman and associates³ and Pollock, et al.,¹⁶ reported that the incidence (and latency) of radiation necrosis following radiosurgery for AVMs was 3.3% (11–15 months postradiosurgery) and 10% (11–22 months postradiosurgery), respectively. Therefore, this complication in the present case is not unusual for its latency period.

Patients undergoing radiosurgery not only for AVMs but also for other diseases face the possibility of tumor induction, even though it may be a small possibility. Various types of tumors, such as gliomas, meningiomas, and sarcomas, also may occur. Further studies and careful observation after radiosurgery will be needed. In the future, we may mention this rare complication on the patient informed consent form for radiosurgery. We predict that cases of this rare but clinically very important complication will increase in number hereafter as follow-up periods become longer.

References

1. Cahan WG, Woodard HQ, Higonbotham NL, et al: Sarcoma arising in irradiated bone. Report of eleven cases. **Cancer** **1**: 3–29, 1948
2. Forsyth PA, Kelly PJ, Cascino TL, et al: Radiation necrosis or glioma recurrence: is computer-assisted stereotactic biopsy useful? **J Neurosurg** **82**:436–444, 1995
3. Friedman WA, Blatt DL, Bova FJ, et al: The risk of hemorrhage after radiosurgery for arteriovenous malformations. **J Neurosurg** **84**:912–919, 1996
4. Itoyama Y, Uemura S, Ushio Y, et al: Natural course of unoperated intracranial arteriovenous malformations: study of 50 cases. **J Neurosurg** **71**:805–809, 1989
5. Kaschten B, Flandroy P, Reznik M, et al: Radiation-induced gliosarcoma. Case report and review of the literature. **J Neurosurg** **83**:154–162, 1995
6. Kitanaka C, Shitara N, Nakagomi T, et al: Postradiation astrocytoma. Report of two cases. **J Neurosurg** **70**:469–474, 1989
7. Kuroiwa T, Ohta T, Kobata H, et al: Coexistence of intracranial meningioma and primary malignant lymphoma—case report. **Neurol Med Chir** **30**:268–271, 1990
8. Leksell L: Cerebral radiosurgery. I. Gammathalamotomy in two cases of intractable pain. **Acta Chir Scand** **134**:585–595, 1968
9. Mack EE, Wilson CB: Meningiomas induced by high-dose cranial irradiation. **J Neurosurg** **79**:28–31, 1993
10. Marus G, Levin CV, Rutherford GS: Malignant glioma following radiotherapy for unrelated primary tumors. **Cancer** **58**: 886–894, 1986
11. Matsumura H, Takimoto H, Shimada N, et al: Glioblastoma following radiotherapy in a patient with tuberous sclerosis. **Neurol Med Chir** **38**:287–291, 1998
12. Nishio S, Morioka T, Inamura T, et al: Radiation-induced brain tumours: potential late complications of radiation therapy for brain tumours. **Acta Neurochir** **140**:763–770, 1998
13. Ogilvy CS: Radiation therapy for arteriovenous malformations: a review. **Neurosurgery** **26**:725–735, 1990
14. Palma L, Mastronardi L, Celli P, et al: Cavernous angioma associated with oligo-astrocytoma-like proliferation. Report of two cases and review of the literature with a reappraisal of the term "angioglioma". **Acta Neurochir** **133**:169–173, 1995
15. Piatt JH Jr, Blue JM, Schold SC Jr, et al: Glioblastoma multiforme after radiotherapy for acromegaly. **Neurosurgery** **13**: 85–89, 1983
16. Pollock BE, Garces YI, Stafford SL, et al: Stereotactic radiosurgery for cavernous malformations. **J Neurosurg** **93**:987–991, 2000
17. Rusyniak WG, Marchese MJ, Nelson CN: Benign meningioma with a short latency period following irradiation. **Surg Neurol** **38**:261–264, 1992
18. Schrantz JL, Araoz CA: Radiation induced meningeal fibrosarcoma. **Arch Pathol** **93**:26–31, 1972
19. Shapiro S, Mealey J Jr, Sartorius C: Radiation-induced intracranial malignant gliomas. **J Neurosurg** **71**:77–82, 1989
20. Simmons NE, Laws ER Jr: Glioma occurrence after sellar irradiation: case report and review. **Neurosurgery** **42**:172–178, 1998
21. Steiner L, Leksell L, Greitz T, et al: Stereotaxic radiosurgery for cerebral arteriovenous malformations. Report of a case. **Acta Chir Scand** **138**:459–464, 1972
22. Steiner L, Lindquist C, Cail W, et al: Microsurgery and radiosurgery in brain arteriovenous malformations. **J Neurosurg** **79**: 647–652, 1993
23. Stieg PE, Friedlander RM, Loeffler JS, et al: Arteriovenous malformations: indications for stereotactic radiosurgery. **Clin Neurosurg** **47**:242–248, 2000
24. Yamamoto M, Jimbo M, Hara M, et al: Gamma knife radiosurgery for arteriovenous malformations: long-term follow-up results focusing on complications occurring more than 5 years after irradiation. **Neurosurgery** **38**:906–914, 1996
25. Yu JS, Yong WH, Wilson D, et al: Glioblastoma induction after radiosurgery for meningioma. **Lancet** **356**:1576–1577, 2000

Manuscript received August 25, 1999.

Accepted in final form June 26, 2001.

Address reprint requests to: Toshisuke Sakaki, M.D., Department of Neurosurgery, Nara Medical University, 840 Shijocho, Kashihara, Nara, 634–8522, Japan. email: neurosrg@nmu-gw.naramed-u.ac.jp.