

Moyamoya Disease Initially Presenting Visual Field Defect

Min-Kyung Chu¹, Il-Hyung Lee², Dong-Ik Kim³, and Seung-Min Kim¹

¹Department of Neurology, Yonsei University College of Medicine, Seoul, Korea;

²Department of Neurology, Yonsei University Wonju College of Medicine, Wonju Christian Hospital, Wonju, Korea;

³Department of Diagnostic Radiology, Yonsei University College of Medicine, Seoul, Korea.

Progressive narrowing of distal carotid arteries and the development of compensatory fine networks are the characteristic findings of moyamoya disease. Cerebral infarction in moyamoya disease is due to a decreased blood flow and shows an uneven distribution in the distal bed of the anterior and middle cerebral arteries. The progression of disease in the posterior circulation follows that in the anterior circulation. Posterior circulation symptoms due to cerebral infarction usually occur in the advanced stage of the disease and follow the anterior circulation symptoms. We encountered an unusual case of moyamoya disease which initially presented with a transient visual field defect. One month later our patient developed blindness and her cerebral angiography showed advanced moyamoya disease.

Key Words: Moyamoya disease, posterior circulation, visual disturbance, cerebral infarction

INTRODUCTION

First reported by Suzuki in 1963,¹ moyamoya disease is a progressive occlusive cerebrovascular disease. Characteristic angiographic findings in moyamoya disease are stenosis or occlusion of the bilateral distal internal carotid arteries and the proximal portion of the anterior and middle cerebral arteries with a compensatory development of fine vascular networks.²⁻⁴ The compensatory lesions, moyamoya vessels, are seen as abnormal net-like vessels at the base of the brain and at the cerebral surface. These arteries form

complex channels that connect the carotid arteries to the distal portion of the anterior and middle cerebral arteries.^{2,5,6}

The diagnosis of moyamoya disease is made on the basis of typical angiographic findings and exclusion of other disease.⁶⁻⁸ At early stages of the disease, only slow and progressive occlusions at the proximal portion of bilateral internal carotid arteries are observed. Proportionally to decreased flow due to this stenosis, the collateral vessels develop in order of ease of their development. With an initial insufficiency of distal carotid system, collateral vessels at base of brain and leptomeningeal collateral vessels from posterior circulation become prominent. After an interval, collateral vessels from the external carotid system become more prominent. They replace the intra-axial collateral vessels. Finally the brain becomes nourished mainly by the collateral vessels.⁵⁻⁷ Any failure in compensation is expressed as an ischemic episode which is common finding in patients with moyamoya disease. Small cortical or subcortical lesions in the distal beds of the anterior and middle cerebral arteries and often in the border zone are observed in infarction patients with moyamoya disease. The clinical symptoms of these patients are impaired consciousness, focal motor sign, speech disturbances, seizure and sensory changes.⁸⁻¹¹

The involvement of the posterior circulation in moyamoya disease occurs in the later stage of the disease after defection of anterior and middle cerebral arteries.^{5,12,13} Posterior circulation symptoms in cerebral infarction patients with moyamoya disease are not common and usually occurs after anterior circulation symptoms.^{7,8} We encountered an unusual case of moyamoya disease with

Received March 16, 2001

Accepted May 28, 2001

Reprint address: requests to Dr. Seung-Min Kim, Department of Neurology, Yonsei University College of Medicine, C.P.O. Box 8044, Seoul 120-752, Korea. Tel: 82-2-361- 5461, 6413, Fax: 82-2-393-0705, E-mail: kimsn@yumc.yonsei.ac.kr

adult onset initially manifesting as a transient visual field defect.

CASE REPORT

A 30-year-old right handed women was admitted to the Department of Neurology of the Severance hospital via the Emergency Center at April 28, 2000. She graduated from high school and worked for a survey company as a field worker. She was healthy until March 2000 and she did not take oral contraceptives. In mid March 2000, she could not see objects in her right or left half visual field and had severe headaches, lasting for about 5 minutes. During the transient visual field defect, her visual field defect persisted even after closing one eye. Such visual field defects occurred 4 times more until March 15. She intermittently could not read the letters in signboards for 1 to 5 minutes in the street even though she could see the signboards. One week before the onset of blindness, she experienced daily continuous severe headaches at the occipital area. She also underwent a right or left one-half visual field defect that lasted 3 to 5 minutes, once or twice in a day. After admission, a neurological examination disclosed acalculia, right-left disorientation, finger agnosia and pronator drift in the right arm. Due to the onset of blindness, we could not determine higher visual dysfunctions. Magnetic resonance imaging (diffusion and FLAIR) was performed on the second day of admission using a 1.5 T signa horizon echospeed system (GE medical system, Milwaukee, Wisconsin, U.S.A). Diffusion MR image showed a high signal intensity in the right occipital lobe and less high signal intensity in the left temporal, occipital, parietal and occipital lobe cortex and subcortex. In FLAIR MR, a high signal intensity was noted in the same area as diffusion MR and multiple collateral channels were observed to be as signal void structures in basal ganglia (Fig. 1). Tc-99m-ECD brain single proton emission computed tomography (SPECT) was done on the second day of admission. The Tc-99m-ECD brain SEPCT was performed using the CERASPECT system (Digital Scintigraphics, Waltham, Massachusetts, U.S.A). Brain SPECT showed a perfusion defect at the

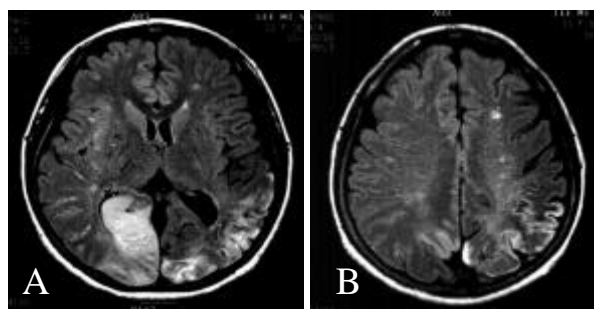


Fig. 1. FLAIR axial image at transthalamic level (A). A cerebral infarction was found in the bilateral posterior cerebral artery territories. FRAIR MRI also showed a cerebral infarction at left parietal lobe (B). This lesion might be relevant to the patient s acalculia, finger agnosia, left-right disorientation and right pronator drift.

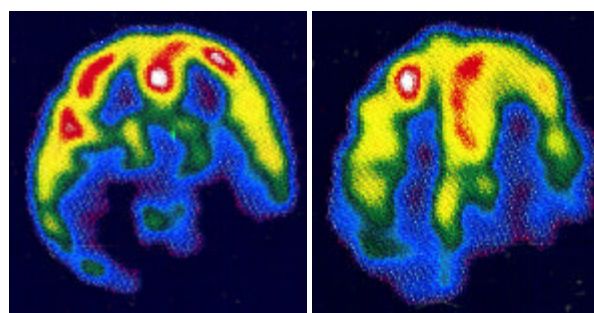


Fig. 2. Brain SPECT showed perfusion defects in the bilateral temporal, occipital and parietal lobes.

bilateral temporal, and occipital lobes and the left parietal area. Decreased perfusion was observed at the right parietal lobe (Fig. 2).

Cerebral angiography was performed on the fourth day of admission. A right common carotid artery angiogram showed an occlusion at the supraclinoid portion of the internal carotid artery which had basal and transdural collaterals. In a left common carotid artery angiogram, the internal carotid artery was totally occluded. The right vertebralbasilar artery angiogram showed a stenosis at the P1 portion of posterior cerebral artery and multiple collateral channels. Development of collateral vessels from the external carotid arteries was seen bilaterally (Fig. 3). Biochemical analyses including fibrinogen, d-dimer, protein C, protein S, lupus anticoagulant, anti-cardiolipin antibody and VDRL were done. All the tests were within the normal range. Fundus photography was taken on the second day of admission and showed normal findings. Heparinization was

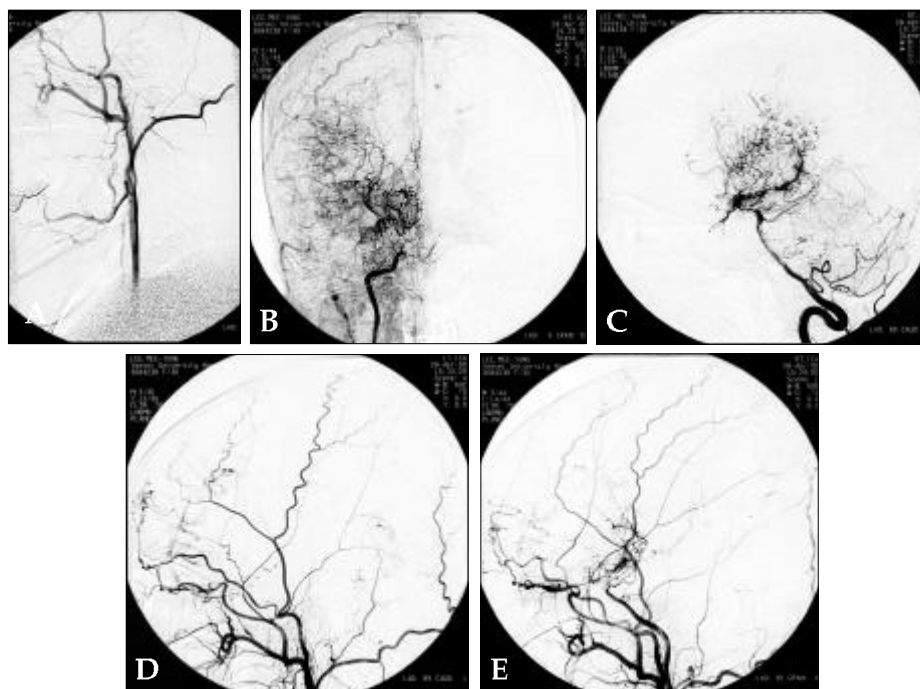


Fig. 3. The left internal carotid artery was totally obstructed (A). A right common carotid artery angiogram revealed an occlusion at the supraclinoid portion of internal carotid artery (single arrow) and basal (double arrows) and transdural collaterals (triple arrows) (B). A right vertebral artery angiogram showed stenosis from the P1 portion of posterior cerebral arteries (single arrow) and multiple collateral channels were seen (double arrows) (C). A left carotid artery angiogram showed the development of collaterals from the external carotid artery (D). Development of collaterals from the external carotid artery into anterior circulation area was greater than those in posterior circulation area. Similar findings were observed in a right carotid angiogram (E).

administered for 5 days after admission. She took an anti-platelet drug (triflusal 300 mg twice in a day) after tapering of heparinization. She was discharged with no change in symptom on the seventh day of admission and was followed at out patient clinic in the Department of Neurology for 9 months without showing a further neurological change.

DISCUSSION

Although some what different findings of moyamoya disease were observed in the right and left carotid arteries, the left internal carotid artery showed an occlusion at the carotid bifurcation and the right internal carotid artery showed an occlusion at the supraclinoid portion and the development of moyamoya vessels. The moyamoya disease involved bilateral carotid arteries. These findings were in accordance with advanced moyamoya disease and fulfilled the diagnostic criteria

for moyamoya disease. Involvement of the posterior circulation was in accordance with a diagnosis of advanced moyamoya disease. According to Suzuki and Takaku's classification, angiographic staging was Stage IV in the right side and Stage V in left side.⁵ We were unable to obtain positive evidence for the following etiologic factors that may have caused occlusion of the cerebral arteries: meningitis, trauma, neurocutaneous syndrome, fibromuscular dysplasia, dissecting aneurysm, or angitis. A diagnosis of moyamoya disease for our patient was therefore made.

The most prominent features of infarctions in moyamoya disease are their distribution. They are seen to be unevenly distributed in the cortical or subcortical areas in the distal bed of the anterior or middle cerebral arteries or borderline zone. The size and number of infarctions vary from being small to large and usually depend upon the degree of collateral vessels development.⁹⁻¹¹ These findings are also congruent in that the disease progression in the anterior circulation precedes

that of the posterior circulation, therefore the mechanism of cerebral infarction in moyamoya disease is hypoperfusion due to narrowing of the basal major vessels and the inability of collateral vessels to maintain blood flow.

Miyamoto et al. noted that the posterior circulation was involved in 43 patients of 178 moyamoya disease patients.^{12,13} The clinical symptoms of these patients included a visual field defect, decreased visual acuity, an episode of transient blindness, scintillating scotoma and cortical blindness. Cortical blindness was found in only one patient. The chronological relationship between the initial onset of symptoms and visual symptoms was not mentioned. Kim et al. reported two cases of moyamoya disease manifested as a visual disturbance.¹⁴ One of them (a 45 years old female) suffered a transient motor weakness 15 years before the onset of the cortical blindness. The other patient (a 13 years old male) showed a right side homonymous hemianopsia. He suffered from recurrent seizure attacks since 3 years of age.

There could be several mechanisms for the initial visual disturbance or posterior circulation symptoms in moyamoya disease. First, the disease progression in the posterior circulation is similar to or more rapid than in the anterior circulation. In our case, cerebral angiography showed that the anterior circulation was obliterated and stenosis in posterior circulation was progressive. We could assume that the disease progression was more severe in the anterior circulation than in the posterior circulation. Extended progression of the posterior circulation, more than in the anterior circulation, is less likely in our patient.

Second, even as the disease progressed, it could be symptomless as a result of a compensatory mechanism i.e., the development of collateral vessels. A subtle hemodynamic change in the collateral vessels i.e., disease progression in small collateral vessels, could induce an initial cerebral infarction in the posterior circulation. Our patient showed a recurrent transient visual field defect, headache, and a reading difficulty before the onset of blindness. These transient symptoms would have indicated an unstable hemodynamic state and even the development of collateral vessels in the anterior and posterior circulations. This mechanism could be operating in our patient.

The degree of significance of either could not be determined.

Third, collaterals from external carotid system develop after minimization of collateral vessels at the brain base and come to the main blood supply in the terminal stage of the disease. A lack of external carotid collateral and a decreased blood flow in the posterior circulation would have caused the initial posterior circulation symptoms. Our patient's angiography showed external carotid artery collateral development in the anterior circulation areas but fewer external carotid artery collaterals in the posterior circulation supply areas (Fig. 3). An unequal blood supply due to differences in development of collaterals from external carotid artery, would have caused the initial posterior circulation symptoms. This mechanism may be operative in our case.

Neurological examination at admission revealed acalcuria, right-left disorientation, finger agnosia and right pronator drift. These findings may be indicative of a lesion in the left inferior parietal lobule.^{15,16} A recent infarction was shown in this area by brain MRI. The vascular supply to this area is normally the middle cerebral artery.^{16,17} In advanced moyamoya disease the normal vascular supply system is obliterated and the precise vascular supply could not be determined. For these left inferior parietal lobe symptoms co-occurred with cortical blindness and the left inferior parietal lobule is adjoin to posterior circulation supply territory, the left inferior parietal lobule in this patient was supposed to be supplied by the posterior circulation.

During initial transient visual field defect, this symptom appeared in the right or left half visual field and continued after closing either eye. This symptom would be indicative of a homonymous hemianopsia and the relevant lesion would have a post-chiasmatic location. After the onset of blindness, a fundus photo examination showed normal findings and pupillary light reflexes were normal bilaterally. We could determine that the blindness had a cortical origin. The brain MRI also showed a recent infarction in the relevant areas, bilateral occipital lobes.

Our case thought to be the first reported case of moyamoya disease which initially appeared as a visual disturbance or a posterior circulatory

disturbance. Our patient showed advanced angiographic findings of moyamoya disease bilaterally and we could find no evidence for a different disease. Even though most cerebral infarctions in moyamoya disease show anterior circulation symptoms, a posterior circulation symptom or a visual disturbance could be an initial symptom of this disease.

REFERENCES

1. Suzuki J. A study on disease showing singular-cerebroangiographical findings which seem to be new collateral circulation. Proceedings of 22nd meeting of japan neurological society, 1963.
2. Suzuki J, Kodama N. Moyamoya disease-a review. *Stroke* 1983;14:104-9.
3. Choi JU, Kim DS, Kim EY, Lee KC. Natural history of moyamoya disease: comparison of activity of daily living in surgery and non surgery groups. *Clin Neurol Neurosurg* 1997;99 Suppl 2:S11-8.
4. Park EM, Yoon BW, Jang JH, Kim HJ, Roh JK. Adult-onset moyamoya disease: clinical features and prognosis. *J Korean Neurol Assoc* 2000;18:1-7.
5. Suzuki J, Takaku A. Cerebrovascular "moyamoya" disease. Disease showing abnormal net-like vessels in base of brain. *Arch Neurol* 1969;20:288-99.
6. Matsushima Y. Moyamoya disease. In: Youmans JR, chief, editor. *Youmans neurological surgery*. Fourth ed. Philadelphia: W.B. Saunders Company; 1996. p.1202-23.
7. Yamada I, Himeno Y, Suzuki S, Matsushima Y. Posterior circulation in moyamoya disease: angiographic study. *Radiology* 1995;197:239-46.
8. Hasuo K, Mihara F, Matsushima T. MRI and MR angiography in moyamoya disease. *J Magn Reson Imaging* 1998;8:762-6.
9. Bruno A, Yuh WT, Biller J, Adams HP, Cornell SH. Magnetic resonance imaging in young adults with cerebral infarction due to moyamoya. *Arch Neurol* 1988;45:303-6.
10. Bruno A, Adams HP, Biller J, Rezai K, Cornell S, Aschenbrener CA. Cerebral infarction due to moyamoya disease in young adults. *Stroke* 1988;19:826-33.
11. Adams HP, Davis P. Moyamoya syndrome. In: Bogousslavsky J, Caplan L, editors. *Stroke syndrome*. New York: Cambridge University Press; 1995. p.405-11.
12. Miyamoto S, Kikuchi H, Karasawa J, Nagata I, Ikota T, Takeuchi S. Study of the posterior circulation in moyamoya disease. Clinical and neuroradiological evaluation. *J Neurosurg* 1984;61:1032-7.
13. Miyamoto S, Kikuchi H, Karasawa J, Nagata I, Ihara I, Yamagata S. Study of the posterior circulation in moyamoya disease. Part 2: Visual disturbances and surgical treatment. *J Neurosurg* 1986;65:454-60.
14. Kim SH, Kim SY, Hong SB, Yoon BW, Roh JK, Lee BK, et al. Two cases of moyamoya disease showing visual disturbance and complete occlusion of proximal internal carotid artery. *J Korean Neurol Assoc* 1988;8:325-33.
15. Moore MR, Saver JL, Johnson KA, Romero JA. Right parietal stroke with Gerstmann's syndrome. Appearance on computed tomography, magnetic resonance imaging, and single-photon emission computed tomography. *Arch Neurol* 1991;48:432-5.
16. Saver JL, Biller J. Superficial middle cerebral artery. In: Bogousslavsky J, Caplan L, editors. *Stroke syndrome*. New York: Cambridge University Press; 1995. p.247-58.
17. Tatu L, Moulin T, Bogousslavsky J, Duvernoy H. Arterial territories of the human brain: cerebral hemispheres. *Neurology* 1998;50:1699-708.