

# Bilateral Occipital Infarcts in a Hemodialysis Patient

Yahya H. Al-Falki

Division of Ophthalmology, King Khalid University, Abha, Kingdom of Saudi Arabia

## Key Words

Cortical blindness · Hemodialysis · Occipital infarct · Visual loss

## Abstract

Cortical blindness as a complication of hemodialysis is not widely known, though visual disturbances related to uremia have been known for a long time. We recently observed cortical blindness caused by bilateral occipital infarcts in a patient after hemodialysis.

Copyright © 2001 S. Karger AG, Basel

## Introduction

Cerebral (cortical or geniculocalcarine) blindness refers to subnormal visual acuity caused by bilateral retrogeniculate lesions. Bilateral involvement of the occipital cortices can reduce visual acuity to any level. Uremic amaurosis and ischemic optic neuropathy are two important causes of sudden visual loss in hemodialysis patients [1-3], but cortical blindness as a complication of hemodialysis is covered only briefly in the literature. Herein a hemodialysis patient who had bilateral occipital infarcts with persistent bilateral visual loss is reported.

## Case Report

A 60-year-old Saudi male patient with unknown primary renal disease had been on regular dialysis (three times/week, 4 h each session) for 5 years. His dialysis dose as estimated by the urea reduction ratio was about 67%. He was not diabetic but hypertensive with an average predialysis blood pressure of 160/90 mm Hg. His medications were nifedipine 20 mg twice daily, calcium carbonate 600 mg three times daily (with meals), 1 $\alpha$ -hydroxyvitamin D<sub>3</sub> 0.25  $\mu$ g every other day, iron 200 mg three times daily, folic acid 5 mg every other day, and intravenously administered heparin 2,000 U (40  $\mu$ g/kg) during each dialysis session. After stable routine hemodialysis using a polysulfone membrane, bicarbonate buffer, and the usual dose of heparin, the patient suddenly complained of loss of vision in both eyes. His vital signs were normal. His neurological examination revealed a normal level of consciousness, hypotonia, wasting of muscles distally, and deep tendon hyperreflexia in all limbs, and there were no signs of meningeal irritation. No bruit was detected over the carotid arteries. Echocardiography revealed only left ventricular hypertrophy.

Ophthalmic examination revealed light perception with poor projections in both eyes. The pupils were reactive to light, and there were no afferent pupillary defect and normal extraocular motility. Clear media and normal intraocular pressure in both eyes were present. Fundus examination revealed normal fundi.

The ophthalmic clinical impression was bilateral acute visual loss following hemodialysis, either hysterical or cortical. A computerized axial tomography scan revealed bilateral occipital infarcts (fig. 1). His vision remained permanently lost.

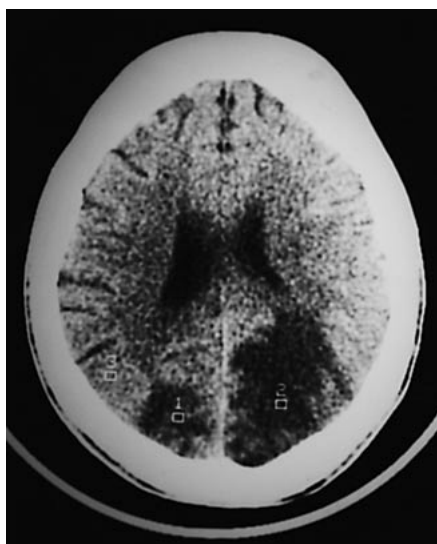
## KARGER

Fax +41 61 306 12 34  
E-Mail karger@karger.ch  
www.karger.com

© 2001 S. Karger AG, Basel  
0250-8095/01/0215-0413\$17.50/0

Accessible online at:  
www.karger.com/journals/ajn

Yahya H. Al-Falki  
Division of Ophthalmology  
King Khalid University, PO Box 641  
Abha (Kingdom of Saudi Arabia)  
Tel./Fax +966 7 228 2805, E-Mail abozakrya@hotmail



**Fig. 1.** Computerized tomogram showing bilateral occipital infarcts.

## Discussion

The occipital cortex is supplied by three main cortical branches of the posterior cerebral artery: the posterior temporal, calcarine, and parietooccipital arteries. The blood supply of the visual cortex is usually primarily by the calcarine artery. The terminal branches of the middle cerebral artery also supply the posterior aspect of the occipital lobe.

The visual cortex is highly susceptible to damage by hypoxia. In case of bilateral occipital infarcts, there will be bilateral homonymous hemianopia, and the visual acuity will be reduced to any level. Vascular disease of the occipital lobes is the most common cause of homonymous field defects in the middle-aged and elderly population. Cerebrally blind patients have binocular and symmetrical

visual acuity and field impairment, normal fundi, and normal pupillary reactions.

The clinical picture of this patient in the form of severely affected acuity (light perception only), preserved pupillary reflexes, and normal fundi is very suggestive of cortical blindness. The computerized tomographic scan findings of bilateral occipital infarcts confirmed the diagnosis. Cortical blindness as a complication of hemodialysis has been reported in the pediatric age group [4] and also has been reported following cardiac arrest [5] and vertebral angiography [6].

One of the major risk factors for ischemia during hemodialysis is hypotension (systolic blood pressure <100 mm Hg) which is considered the most frequent systemic complication of hemodialysis, occurring in ~25% of the cases, and its origin is generally multifactorial. Serious visual complications related to hypotension-induced ischemic insults to vital structures like optic nerves and occipital cortex can occur during hemodialysis. Hypotension-induced ischemic optic neuropathy is well documented in the literature [3, 7, 8].

In this patient hypotension was not encountered during his hemodialysis sessions, but he was anaemic (hemoglobin 6.5 g/dl). The possible causes of occipital infarcts in this patient are preexisting atherosclerosis and anemia which are known complications of end-stage renal disease. No angiographic studies have been performed in this patient, and he did not receive medications that might have affected his vision.

The natural history of cortical blindness of vascular origin is not well defined. The spontaneous recovery is possible, it may take several months, and the degree of recovery is not predictable. The vision of this patient remained permanently lost after 6 months of follow-up. With increasing reports of visual complications related to uremia and hemodialysis, nephrologists as well as ophthalmologists should pay more attention to these rare but catastrophic ophthalmic complications of dialysis.

## References

- 1 Osler W Sir, McCrae T: Modern Medicine. Philadelphia, Lea & Febiger, 1914, vol 3, p 910.
- 2 Tyler HR, Tyler KL: Neurologic complications; in Eknayan G, Knochel I (eds): The Systemic Consequences of Renal Failure. Philadelphia, Grune & Stratton, 1986, p 311.
- 3 Servilla KS, Groffell GC: Anterior ischemic optic neuropathy as a complication of hemodialysis. *Am J Kidney Dis* 1986;8:61.
- 4 Donald I, Moel Y, Kwun A: Cortical blindness as a complication of hemodialysis. *J Pediatr* 1978;93:890-891.
- 5 Sabah AH: Blindness after cardiac arrest. *Postgrad Med J* 1968;44:513.
- 6 Hortwitz NH, Wener L: Temporary cortical blindness following angiography. *J Neurosurg* 1974;40:583.
- 7 Connolly SE, Gordon KB, Horton JC: Salvage of vision after hypotension-induced ischaemic optic neuropathy. *Am J Ophthalmol* 1994;117:235-242.
- 8 Sabeel A, Al-Hazzaa SA, Alfurayh O, Mikkonen P: The dialysed patient who turned blind during a haemodialysis session. *Nephrol Dial Transplant* 1998;29:57-2958.