

M. Takasawa
M. Watanabe
S. Yamamoto
T. Hoshi
K. Kajimoto
N. Kinoshita

“Schistotaxis” in cerebral blood flow on ^{99m}Tc -HMPAO single-photon emission computed tomography during a seizure following a stroke

Received: 13 January 2001
Accepted: 26 February 2001

M. Takasawa (✉)
Division of Stroke Studies,
Department of Internal Medicine and
Therapeutics, Osaka University Graduate
School of Medicine, 2–2, Yamadaoka,
Suita City, Osaka, 565–0871, Japan
e-mail tkswm@medone.med.osaka-u.ac.jp
Tel.: + 81-6-68 79 36 34
Fax: + 81-6-68 78 65 74

M. Takasawa · M. Watanabe · S. Yamamoto
· T. Hoshi · K. Kajimoto · N. Kinoshita
Division of Stroke Studies,
Departments of Cardiovascular Medicine
and Clinical Research,
Osaka-Minami National Hospital, 2–1,
Kidohigashi-cho, Kawachinagano City,
Osaka, 586–8521, Japan

Abstract We describe a patient with seizures following a stroke in whom on ictal ^{99m}Tc -HMPAO single-photon emission computed tomography demonstrated cerebral blood flow “schistotaxis”, i. e., focal hyperaemia corresponding to an epileptogenic focus together with an extensive hypoperfused area in the same hemisphere. This phenomenon may have been caused by haemodynamic alternation and a remote transneuronal effect during the seizures.

Keywords Stroke · Seizure · Single-photon emission computed tomography · Crossed cerebellar diaschisis

Introduction

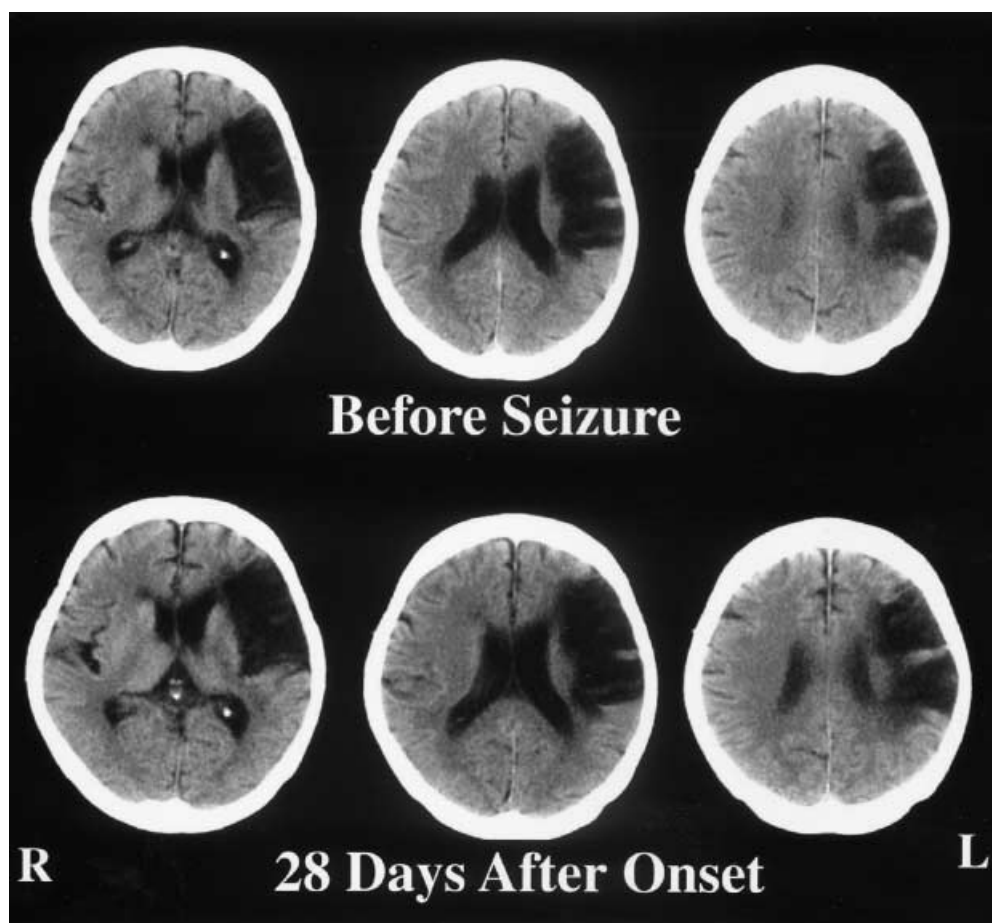
Rapid conversion from the lipophilic to the hypolipophilic form which deposits technetium-99m-hexamethyl-propyleneamine oxime (^{99m}Tc -HMPAO) in the brain [1, 2] produces a “snapshot” of cerebral perfusion at the moment of administration of the radiopharmaceutical. ^{99m}Tc -HMPAO single photon emission computed tomography (SPECT) can therefore be useful for localising an epileptogenic focus during an seizure, but there have been few cases in which a focus has been demonstrated during seizures following a stroke [3], and there have been no detailed reports on the haemodynamic aspects of this type of seizure. We describe a patient with seizures following a stroke in whom ictal ^{99m}Tc -HMPAO SPECT demonstrated cerebral blood

flow (CBF) “schistotaxis”, by which we mean focal hyperaemia corresponding to the epileptogenic focus, together with an extensive area of hypoperfusion area in the same cerebral hemisphere.

Case report

A 74-year-old right-handed woman with a history of a cardiogenic cerebral embolism to the left cerebral 4 months previously suddenly had focal convulsions involving the right side of her face. Immediately after intravenous injection of ^{99m}Tc -HMPAO for a SPECT scan, clonic convulsions spread to the proximal part of the right arm and leg, without loss of consciousness. Before anticonvulsants could be given, the convulsions gradually resolved over a 5-min period. Her consciousness was clear and the blood pressure, heart rate, and body temperature were stable during the study. After

Fig. 1 CT 30 days before the onset of the seizure (*top*) shows a large infarct in the left hemisphere; 28 days after the seizure (*bottom*) no new ischaemic or haemorrhagic lesion is seen



the SPECT, the patient recovered fully to her neurological state before admission, and there was no recurrence of stroke or seizure during the next month. CT 1 and 28 days after the resolution of the seizures showed no new ischaemic or haemorrhagic lesions (Fig. 1).

^{99m}Tc -HMPAO SPECT was acquired on a dual-headed camera with fan-beam collimators 20 min after intravenous injection of 740 MBq ^{99m}Tc -HMPAO. The transaxial slices were reconstructed by filtered backprojection with a Butterworth filter. Each reconstructed slice was corrected for tissue absorption by Chang's method. The ictal images revealed the presumed epileptogenic focus as an area of focal hyperaemia adjacent to the infarct, and a frontal and posterior cortical area of low perfusion in the left hemisphere which was more extensive than on postictal images the following day (Fig. 2). The ictal study also showed hypoperfusion of the right cerebellar hemisphere, which had also resolved the next day.

Discussion

The pattern of CBF we describe suggests that the changes in ipsilateral regional CBF were caused by the hyperaemic epileptogenic focus during the seizure. However, the blood flow to the left parietal ictal area was in the territory of a posterior branch of the middle cerebral artery, and the reduction in perfusion in the

frontal lobe cannot therefore be easily explained by haemodynamic steal, since this territory is supplied by cross-filling via the anterior cerebral communicating artery or by residual left internal carotid artery perfusion. The reduction in posterior CBF could theoretically be produced by steal. The reduction in posterior CBF as a result of local steal due to the focal hyperemia might have caused a reduction in ipsilateral anterior circulation through the superior longitudinal or occipitofrontal fasciculi.

Crossed cerebellar hyperperfusion in patients with seizures has been described on ictal SPECT [4]. In our case, severe hypoperfusion of the contralateral cerebellar hemisphere, crossed cerebellar diaschisis, on ictal SPECT may have been caused by the extensive area of low perfusion in the left hemisphere through the corticopontine pathway [5]. Its disappearance on postictal SPECT could also be explained by the restoration of blood flow in the supratentorial hypoperfused area after the seizure. These observations may be useful in understanding the pathogenesis of seizures following strokes.

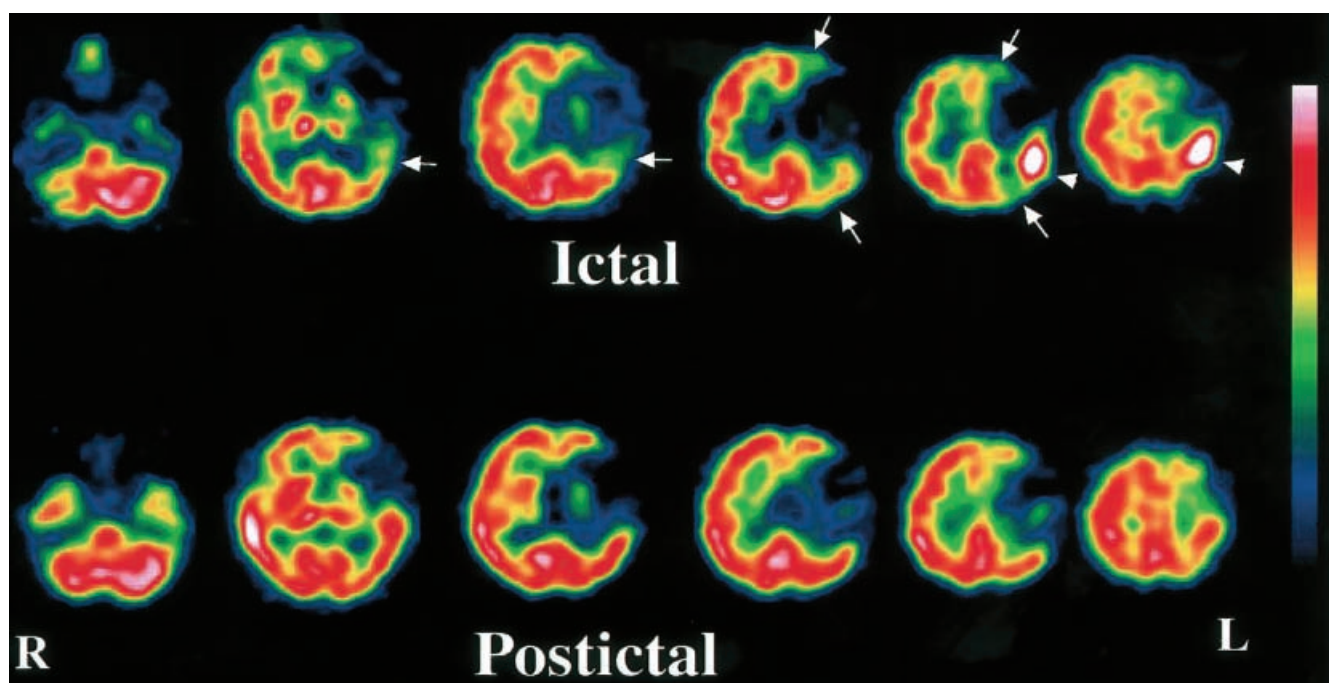


Fig.2 Single-photon emission computed tomography (SPECT) during the seizure (*top*) shows focal hyperemia in the left cortex (*arrowheads*) adjacent to the infarcted area. A larger area of low perfusion in the frontal and posterior cortex (*arrows*) is more extensive than on the second SPECT study the next day (*bottom*). Severe crossed cerebellar diaschisis on the ictal SPECT is no longer evident on the second study

References

1. Nowotnik DK, Canning LR, Cumming SA (1985) Technetium-99m-HMPAO: a new radiopharmaceutical for imaging regional cerebral blood flow. *J Nucl Med Allied Sci* 29: 208
2. Neirinckx RD, Canning LR, Piper IM, et al (1987). Technetium-99m d,l-HMPAO: a new radiopharmaceutical for SPECT imaging of regional cerebral flow perfusion. *J Nucl Med* 28: 191–202
3. Marks DA, Katz A, Hoffer P, Spencer SS (1992) Localization of extratemporal epileptic foci during ictal single photon emission computed tomography. *Ann Neurol* 31: 250–255
4. Duncan R, Patterson J, Bone I, Wyper DJ (1987) Reversible cerebellar diaschisis in focal epilepsy. *Lancet* ii: 625–626
5. Baron JC, Bousser MG, Comar D, Castaigne P (1980) “Crossed cerebellar diaschisis” in human supratentorial brain infarction. *Trans Am Neurol Assoc* 105: 459–461