

CASE REPORT

Low-dose stereotactic radiosurgery is inadequate for medically intractable mesial temporal lobe epilepsy: a case report*

ANTHONY J. CMELAK[†], BASSEL ABOU-KHALIL[‡], PETER E. KONRAD[§], DENNIS DUGGAN[†] & ROBERT J. MACIUNAS[§]

[†] Departments of Radiation Oncology; [‡] Neurology; [§] Neurosurgery, Vanderbilt Medical Center, Nashville, TN 37232, USA

Correspondence to: Anthony J. Cmela, Department of Radiation Oncology, B-902 TVC, 22nd Avenue at Pierce, Vanderbilt Medical Center, Nashville, TN 37232-5671, USA. E-mail: anthony.cmela@mcmail.vanderbilt.edu

The successful surgical treatment of medically refractory epilepsy is based on one of three different principles: (1) elimination of the epileptic focus, (2) interruption of the pathways of neural propagation, and (3) increasing the seizure threshold through cerebral lesions or electrical stimulation. Temporal lobe epilepsy, being the most common focal epilepsy, may ultimately require temporal lobectomy. This is a case report of a 36-year-old male with drug-resistant right mesial temporal lobe epilepsy who failed to obtain seizure control after stereotactic radiosurgery to the seizure focus.

Complex-partial seizures occurred 6–7 times monthly, and consisted of a loss of awareness followed by involuntary movements of the right arm. EEG/CC TV monitoring indicated a right mesial temporal lobe focus, which was corroborated by decreased uptake in the right temporal lobe by FDG-PET and by MRI findings of right hippocampal sclerosis. Stereotactic radiosurgery was performed with a 4MV linac, utilizing three isocenters with collimator sizes of 10, 10, and 7 mm respectively. A dose of 1500 cGy (max dose 2535 cGy) was delivered in a single fraction to the patient's right amygdala and hippocampus.

There were no acute complications. Following radiosurgery the patient's seizures were improved in both frequency and intensity for approximately 3 months. Antiepileptic medications were continued. Thereafter, seizures increased in both frequency and intensity, occurring 10–20 times monthly. At 1 year post radiosurgery, standard right temporal lobectomy including amygdalohippocampectomy was performed with subsequent resolution of complex-partial seizures. Histopathology of the resected temporal lobe revealed hippocampal cell loss and fibrillary astrocytosis, consistent with hippocampal sclerosis. No radiation-induced histopathologic changes were seen.

We conclude that low-dose radiosurgery doses temporarily changed the intensity and character of seizure activity, but actually increased seizure activity long-term. If radiosurgery is to be an effective alternative to temporal lobectomy for medically intractable temporal lobe epilepsy, higher radiosurgery doses will be required. The toxicity and efficacy of higher-dose radiosurgery is currently under investigation.

© 2001 BEA Trading Ltd

Key words: radiosurgery; epilepsy; temporal lobe.

INTRODUCTION

The epilepsies have been classified into the 'generalized' and 'partial' categories based on localization and propagation. This classification not only helps pre-

dict which medical therapy is likely to be effective but also helps predict responsiveness to invasive therapy¹. Standardized surgical techniques for epilepsy date back to Penfield and Jasper². Partial epilepsy commonly originates in the temporal lobe. Since the

*Presented in part at the 85th Assembly of the Radiological Society of North America on November 30, 1999.

discovery that the mesiobasal limbic structures play an important role in the origin and maintenance of most temporal lobe seizures, a common surgical treatment for medically intractable temporal lobe epilepsy is selective amygdalohippocampectomy employing a microsurgical technique³. The concept of using ionizing radiation in the treatment of epilepsy was first addressed in 1905⁴. Since then a number of anecdotal and retrospective reports have described beneficial effects of radiotherapy on seizure frequency and intensity. The majority of these reports have been serendipitous observations that seizure activity can decrease after radiation of low-grade gliomas and arteriovenous malformations^{5,6}, even if the irritant focus failed to respond to treatment. More recently, stereotactic radiosurgery has emerged as a method of treatment for medically intractable mesial temporal lobe epilepsy as an alternative to selective amygdalohippocampectomy. Regis and colleagues reported results on seven patients with drug-resistant seizures who underwent ⁶⁰Co radiosurgery. All seven has cessation of seizures by 15 months post-treatment, and all but one remain seizure-free after follow-up of 24–61 months⁷. A follow-up report in 16 patients corroborates their initial efficacy results⁸. In this case report we will discuss the use of a linac-based radiosurgery technique on a patient with medically intractable mesial temporal lobe epilepsy enrolled in a pilot institutional trial and give recommendations for further clinical studies.

CASE HISTORY AND METHODS

The patient is a 36-year-old right handed male with a history of infantile febrile seizures which spontaneously resolved at the age of 4. Partial complex seizures, sometimes with secondary generalization, started following trauma to his occipital skull at age 18. The current seizure episodes were refractory to vigorous pharmacologic treatment, occurred 6–7 times monthly, and were initiated by a loss of awareness followed by hitting or beating of his abdomen with his right hand, stiffening of his left arm, and occasional turning of his head to the right. Episodes lasted 30–60 seconds, followed by a postictal period of 1–2 hours. A variety of anti-epileptic drugs and combinations were used before determining his seizures were medically refractory, including phenytoin, carbamazepine, Phenobarbital, clonazepam, and gabapentin.

Gadolinium-enhanced MRI using sagittal T1, axial and coronal proton density and T2 images, as well as axial T1 and coronal MP RAGE images showed a focal area of asymmetric thinning and sclerosis of the right amygdala and hippocampal parenchyma with associated increased T2 signal (Fig. 1). The left

hippocampus appeared normal, as did the remaining cerebral parenchyma. Of note, slight wasting of the cerebellar folia was observed, consistent with chronic phenytoin therapy. EEG from scalp and sphenoid electrodes combined with closed-circuit TV monitoring recorded eight complex partial seizures arising from the right temporal region at the right sphenoid electrode. In addition, right temporal slowing was observed, consistent with focal cerebral dysfunction in this region. 18F-fluorodeoxyglucose (FDG) positron emission tomography showed decreased uptake in the right temporal lobe compared to the left, particularly mesially (asymmetry index of 20%). Cerebral angiography using a digital subtraction technique showed no evidence of aneurisms, arteriovenous malformations, or evidence of fetal connections between the anterior and posterior circulation.

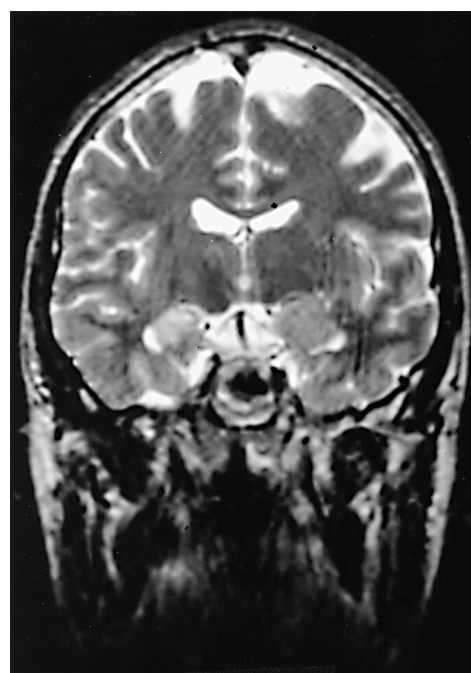


Fig. 1: Axial magnetic resonance image of patient pre-radiosurgery. Note right medial temporal lobe sclerosis with increased T2 signal, typical of long-term epilepsy.

The patient elected to be enrolled on an IRB approved institutional randomized trial comparing stereotactic radiosurgery with standard temporal lobectomy, and was randomized to radiosurgery after informed consent was obtained. Stereotactic radiosurgery was performed using a 4MV linac (Varian Clinac 4/100, Palo Alto, CA) using a Brown–Roberts–Wells stereotactic head frame, Philips SRS Isocentric subsystem, and X-Knife[®] 3.0 (Radionics, Burlington, MA) planning software. Both CT and MRI imaging were used to determine the target structures (right amygdala and hippocampus) as well as sensitive non-target structures (Fig. 2). The target region was treated in a single fraction to a dose of 1500 cGy at the 57%

isodose line (2535 cGy maximum) using three separate isocenters using collimator diameters of either 7 or 10 mm (Fig. 3). The decision to use this isodose line ensured no more than 900 cGy was delivered to the brainstem. We used 960–990 arc degrees within 8–9 non-coplanar arcs for each isocenter.

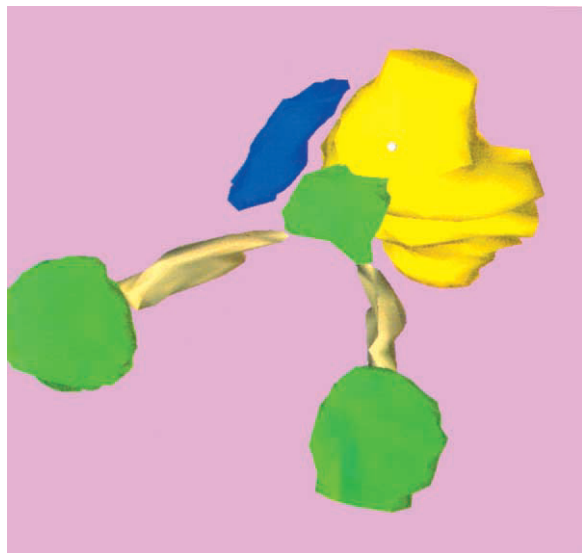


Fig. 2: 3-Dimensional reconstruction of patient's anatomy during stereotactic radiosurgery using both CT and MRI, showing amygdala and hippocampus (dark blue), brainstem (yellow), optic chiasm (green), optic nerves (gold), and eyes (green).

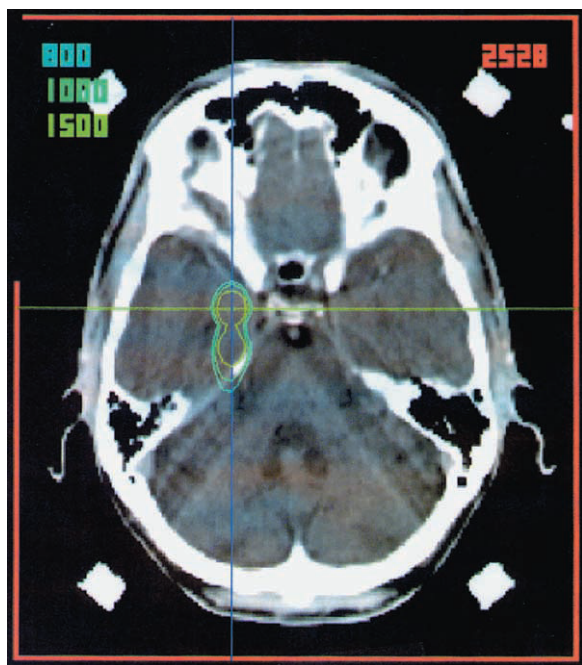

Fig. 3: Axial CT image with overlay of isodose distribution using three separate isocenters with collimator diameters of 7, 10, and 10 mm respectively. The prescription isodose line of 1500 cGy covered the target region (amygdala and hippocampus) at 57% of maximum dose. Isodose lines for 1000 cGy and 800 cGy are also shown.

RESULTS

Following radiosurgery, the patient had no acute or subacute complications. The patient was maintained on double anti-seizure medications following treatment. During the first 30 days he experienced no seizures, and during months 2 and 3 he recorded a total of four seizures. Seizures were milder, but otherwise their character did not change following radiosurgery, and after month 3 his episodes began to increase back to baseline (approx. 6–8 monthly). After 3 months, seizure frequency increased above pre-treatment levels to 15–20 each month, and seizures became longer and more severe. Post-irradiation MRI obtained at 6 months again showed unchanged cerebellar atrophy and subtle asymmetry of the medial temporal lobes, and no abnormal enhancement or edema to suggest radiation injury.

The patient continued to be followed for 1 year without significant intervention or change in seizure frequency or intensity. The patient's neurologic examinations remained unchanged from his pre-treatment status. EEG at 14 months showed continued right centro-temporal slowing in the 2–4 Hz range, and MRI at 12 months again showed no significant change. It was, therefore, decided that radiosurgery treatment had failed to improve seizure frequency, intensity, or produce any radiographic evidence of necrosis. At the recommendation of the epilepsy committee (epileptologist, neurosurgeon, and others) the patient underwent right temporal craniotomy and standard right temporal lobectomy. Intraoperative electrocorticography using surface and depth electrodes were performed which showed that all epileptiform activity was within the hippocampus, which corroborated previous EEGs. Thereafter, the parahippocampal gyrus, amygdala, and 2–2.5 cm of hippocampus and uncus were removed along with 5.5 cm of lateral temporal cortex. Repeat electrocorticography showed residual epileptiform activity behind the line of the excision. Postoperatively he was continued on Tegretol and Neurontin. Histopathology of the resected specimen revealed hippocampal cell loss and fibrillary astrocytosis, consistent with epilepsy-related sclerosis. No radiation-induced histopathologic changes were seen (Fig. 4).

At initial 6-week follow-up, the patient had noted no further complex-partial seizure activity, but he did have residual auras. He has continued to be seen by the epileptologist for 18 months on a regular basis and has remained free of complex-partial seizures. However, he continues to have isolated auras and he continues on antiepileptic drugs.

DISCUSSION

The reported yearly incidence of new onset epilepsy is approximately 20–50 per 100 000 population and the prevalence is between 2 and 10 per 1000 population⁹. An extensive review of multiple large series of adult patients with seizures reported that 67% were focal (partial) in onset, 20% generalized, and 13% unclassified¹⁰. It is worth emphasizing that all of the partial epilepsies can become secondarily generalized, and that the focal onset may be obscured. If localized therapy is to be effective in controlling seizure activity, by definition it must be in those patients who have the partial variety. In addition, effective localized therapy must eliminate the epileptic focus, interrupt the pathways of neural propagation, or increase the epileptogenic threshold through cerebral lesions or electrical stimulation.

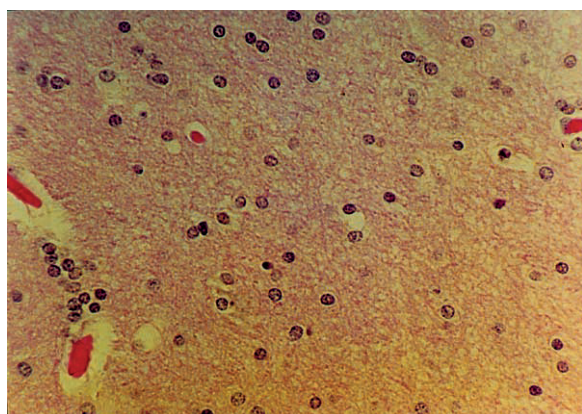


Fig. 4: Histopathology of resected temporal lobe specimen. Neuronal cell loss with fibrillary astrocytosis (gliosis) are commonly seen with epilepsy. The normal appearing vasculature without significant fibrosis of the media and adventitia indicate no significant radiation effect one year after treatment. Perivascular edema is consistent with enhancement seen on T2-weighted MRI images.

The clinical use of radiosurgery in the treatment of medically refractory epilepsy has been derived coincidentally from beneficial effects of ionizing radiation (brachytherapy, fractionated radiation therapy, or radiosurgery) observed in patients with arteriovenous malformations and brain tumors experiencing secondary seizures. Seizures often subside in these patients even if the seizure focus resided outside the mass lesion and received considerably less dose, and before any radiographic evidence of response within the target lesion¹¹.

Considering published data, particularly from European centers, showing the efficacy of moderate-dose radiosurgery in controlling medically resistant epilepsy, there are a number of possible explanations why treatment failed in this particular case. The first is that a radiation dose of 15 Gy to the periphery of the target (25.35 Gy maximum dose) is insufficient to

either ablate tissue within the seizure focus or cause enough neuronal damage to a large enough area to hinder propagation of electrical activity. Although previous reports using radiosurgery consistently document doses as low as 10–20 Gy¹² as effective in controlling seizures, histopathology of our patient's resected temporal lobe specimen showed no evidence of radiation effect. We would therefore advocate the use of doses greater than 2500 cGy in future patients. A second possibility is that the epileptogenic zone may not have been within the high-dose radiation volume or extended beyond that volume. It has been reported that the target point for radiosurgery using MRI or CT-based treatment planning is unsuccessful in many cases; the epileptogenic area is not located at the lesion area or sclerosis, but around it. This stresses the importance of obtaining good electrophysiological localization¹³. It may be that extracranial EEG was too imprecise to accurately target anatomy responsible for this patient's seizure genesis. This is in contrast to resective surgery, where *in situ* electrocorticographic localization of the epileptogenic focus (or foci) is routinely performed the moment before resection. In addition, previous reports using radiosurgery have commonly used large collimator diameters (20–35 mm), which may provide assurance of including the focus¹⁴. This volume of tissue is similar to what would be resected during a standard temporal lobectomy. However, we used only 7–10 mm collimators in an attempt to avoid edema and brainstem injury. Dose–volume histogram analysis of the patient's radiosurgery treatment indicate that the 1500 cGy volume encompassed 2.4 cm³. This volume of tissue is somewhat smaller than would typically be resected during selective amygdalohippocampectomy, and therefore may be too small to have adequately obliterated the entire neuronal pathway for seizure propagation.

Until further scientifically controlled prospective studies are available, the use of radiosurgery for medically intractable seizures must be performed only in controlled clinical settings. We have discontinued enrollment on this randomized trial, and are now utilizing selective amygdalohippocampectomy as our standard surgical procedure. We will be enrolling future patients in a single arm pilot study to better determine the optimal volumes and doses necessary for seizure control. Patients that might benefit from enrollment include those patients ineligible for surgery for medical reasons, patients simply not wanting to consider surgery despite being excellent candidates, or patients who have symptomatic seizures secondarily produced by mass-occupying lesions that require radiosurgery as standard treatment (AVMs, gliomas, meningiomas, etc.). We would advocate radiosurgery in this case only after a clearly defined focus is determined by MRI, FDG-PET, and electrocorticographic studies.

Optimal doses appear to be greater than 2500 cGy and radiation volumes should treat 25–30 mm of amygdala and anterior hippocampus in order to treat tissue volumes comparable to what is typically removed by surgical amygdalohippocampectomy.

REFERENCES

1. Kitchen, N. Experimental and clinical studies on the putative therapeutic efficacy of cerebral (radiotherapy) in epilepsy. *Epilepsy Research* 1995; **20**: 1–10.
2. Penfield, W. and Jasper, H. *Epilepsy and the Functional Anatomy of the Human Brain*. Boston, Little Brown, 1954: p. 896.
3. Weiser, H. G. and Yasergil, M. G. Selective amygdalohippocampectomy as a surgical treatment of mesiobasal limbic epilepsy. *Surgical Neurology* 1982; **17**: 445–457.
4. Tracy, S. G. High-frequency, high-potential currents, and X-radiations in the treatment of epilepsy. *New York Medical Journal* 1905; 422–424.
5. Rossi, G. F. Epileptogenic cerebral low grade tumours: effect of interstitial stereotactic irradiation on seizures. *Applied Neurophysiology* 1985; **48**: 127–132.
6. Kjelberg, R. N., Davis, K. R., Lyon, S., Butler, W. and Adams, R. Bragg peak proton beam therapy for arteriovenous malformations of the brain. *Clinical Neurosurgery* 1983; **31**: 248–290.
7. Regis, J. et al. Gamma knife surgery for mesial temporal lobe epilepsy. *Epilepsia* 1999; **40**: 1551–1556.
8. Regis, J. et al. Radiosurgery for trigeminal neuralgia and epilepsy. *Neurosurgery Clinics of North America* 1999; **10**: 359–377.
9. Zielinsky, J. J. Epidemiology. In: *A Textbook of Epilepsy*. Vol. 1082 (Eds J. Laidlaw and A. Richens). New York, Churchill Livingstone, p. 16.
10. Treiman, D. M. Seizure types and causes of epilepsy. *Seminars in Neurology* 1981; **1**: 65.
11. Heikkinen, E. R. and Heikkinen, M. I. New diagnostic and therapeutic tools in stereotaxy. *Applied Neurophysiology* 1987; **50**: 136–142.
12. Barcia, J. A., Barcia-Salorio, J. L., Lopez-Gomez, I. and Hernandez, G. Stereotactic radiosurgery may be effective in the treatment of idiopathic epilepsy: Report on the methods and results in a series of eleven cases. *Stereotactic and Functional Neurosurgery* 1994; **63**: 271–279.
13. Barcia-Salorio, J. L. and Barcia, J. A. The role of radiosurgery in the treatment of epilepsy. In: *Textbook of Stereotactic and Functional Neurosurgery* (Eds P. L. Gildenberg and R. R. Tasker). New York, McGraw-Hill, 1998: pp. 1925–1932.
14. Alexander, E. III and Lindquist, C. Special indications: radiosurgery for functional neurosurgery and epilepsy. In: *Stereotactic Radiosurgery* (Eds E. Alexander III, J. Loeffler and L. D. Lundsford). New York, McGraw-Hill, 1993: pp. 221–225.