

Jargonagraphia in a Case of Frontotemporal Dementia

Per Östberg, Nenad Bogdanovic, Sven-Erik Fernaeus, and Lars-Olof Wahlund

*Division of Geriatric Medicine, Huddinge University Hospital, and NEUROTEC,
Karolinska Institutet, Stockholm, Sweden*

Published online August 14, 2001

Jargonagraphia is known to occur after discrete brain lesions but not in primary degenerative dementia. We report a patient with frontotemporal dementia who developed jargonagraphia and nonfluent aphasia. Written output was graphically preserved but consisted of short words intermingled with abstruse neologisms. MRI showed predominant right frontotemporal cortical atrophy accompanied by white matter hyperintensities in the right anterior subcallosal periventricular region. Diagnosis and MRI were corroborated by extensive neuropathological findings obtained 8 months later. The agraphia in this case is discussed with reference to both specific macroscopic and microscopic pathoanatomical lesions. We suggest that jargonagraphia can appear in frontotemporal dementia depending on the localization of lesions. © 2001 Academic Press

Key Words: agraphia; crossed aphasia; frontotemporal dementia; jargon.

INTRODUCTION

Jargonagraphia is a rare acquired writing disorder. It is characterized by preserved graphetics and profuse spelling errors that make the patient's written output incomprehensible. It may occur together with Wernicke's jargonaphasia, i.e., Wernicke's aphasia with highly paraphasic speech. Curiously, it seems that no unquestionable case of jargonagraphia has been reported in primary degenerative dementia. A survey of 1076 aphasics disclosed six jargonagraphics, none of whom had a degenerative etiology; left retrorolandic lesions were found in four cases, a left frontotemporal lesion in one case, and multiple lesions (left frontal + left occipital) in one (Cappa, Cavalotti, & Vignolo, 1986). Gustafson, Hagberg, and Ingvar (1978) noted "fluent perseverative partly neologistic writing" in one of their subjects (case 8). This patient had a clinical diagnosis of "probable Pick's disease," but neuropathology was not presented.

Pick's disease is now generally but not universally replaced as a clinical label by the term frontotemporal lobar degeneration (Neary, Snowden, Gustafson, Passant, Stuss, Black, Freedman, Kertesz, Robert, Albert, Boone, Miller, Cummings, & Benson, 1998; for a comprehensive review of focal cortical atrophies, see Black, 1996). This entity includes three syndromes: frontotemporal dementia (FTD), semantic de-

Address correspondence and reprint requests to Per Östberg, Geriatriska kliniken, B56, Huddinge Universitetssjukhus, SE-141 86 Stockholm, Sweden. Fax: + 46 8 585 854 82. E-mail: per.ostberg@ger.hs.sll.se.

mentia, and progressive nonfluent aphasia. FTD is a progressive disorder of social conduct and executive function.¹ There is little information on writing in FTD. Spelling is said to be surprisingly accurate in some patients, while others show omission and telescoping errors on dictation (Snowden, Neary, & Mann, 1996). Holland, McBurney, Moosy, and Reinmuth (1985) documented the language decline in a case of Pick's disease with neurofibrillary tangles, using, *inter alia*, the patient's own written records. Spelling was preserved even at a late stage of the disease while syntactic production was strongly impaired. However, Holland et al.'s case does not fit the description of FTD *sensu stricto*, since speech-language impairment existed without disordered social conduct for several years. Rather, it agrees with that of progressive nonfluent aphasia in current clinical terminology (this holds also for the agrammatic written output; see Neary et al., 1998, p. 1551). Here we report on jargonagraphia in an autopsy-verified case of frontotemporal lobar degeneration with a clinical course consistent with FTD.

CLINICAL COURSE

LEA was a right-handed monolingual Swedish house painter. From age 61 he became emotionally unstable. His spontaneous speech decreased gradually. He spent more time reading tragic lyrics and painting. At age 62 he was referred to the Dementia Unit at Huddinge University Hospital. At that time he spoke very little but sometimes responded in writing. This was largely unintelligible due to abundant neologisms. He did not read aloud. His speech (though very scarce) appeared to be phonologically and syntactically well formed; articulation, however, was impaired. He scored 0/30 on the Mini-Mental State Examination (MMSE). He displayed both stimulus-bound and impulsive behavior, but no echophenomena. Perseveration appeared when LEA was requested to imitate series of different movements; otherwise, perseveration was not a conspicuous symptom. LEA's memory could not be reliably assessed, but he knew his age, indicating that he was better updated than the very low MMSE score would suggest. Magnetic resonance imaging (MRI) showed moderate cerebral atrophy, more pronounced in the right frontal and temporal lobes (Fig. 1). An area with increased signal intensity on T2-weighted images was seen on the right side adjacent to the frontal horn. An electroencephalogram (EEG) was normal. Single-photon emission computed tomography (SPECT) showed strongly reduced perfusion in the basal temporal lobes. Later, LEA became increasingly aggressive and was treated with haloperidol in low doses. He had difficulties in swallowing and drooled. His head drooped due to decreased tonus in the neck muscles. There was a positive glabella reflex but no myoclonus or cogwheel signs. He died of bronchial pneumonia at 63 years old.

NEUROPATHOLOGICAL FEATURES

Gross Findings

The total brain weight was slightly decreased (1270 g). Both cerebral hemispheres displayed moderate atrophy (1090 g), whereas the cerebellum and the brainstem were in the range of normal weight (150 and 30 g, respectively). The frontal lobes were moderately atrophied, predominantly at the right side (Fig. 2). On coronal section

¹ Some authors (e.g., Bozeat, Gregory, Ralph, & Hodges, 2000) use the term frontotemporal dementia in a wider sense to include semantic dementia. Frontotemporal dementia *sensu stricto* is then referred to as "the frontal variant of frontotemporal dementia."

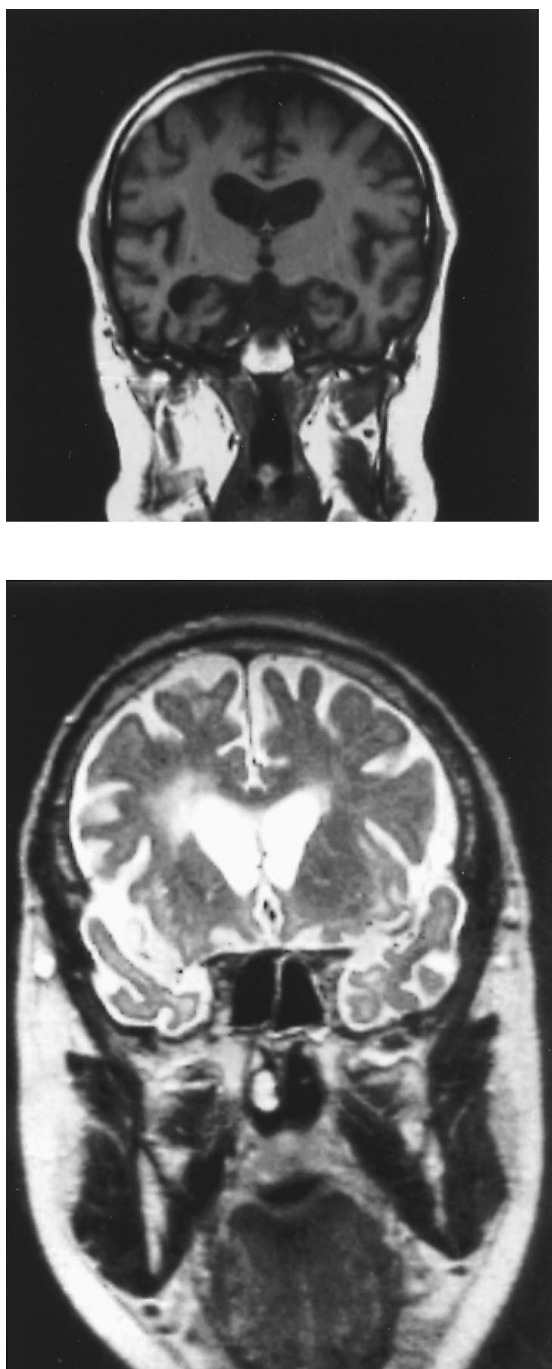


FIG. 1. (a) Coronal MR image of LEA's brain 8 months before death. The ventricles are asymmetrically enlarged, the lateral ventricle and the temporal horn being somewhat more dilated on the right side. (b) Coronal T2 w image showing signal hyperintensity in the right periventricular area, indicating a white matter lesion.

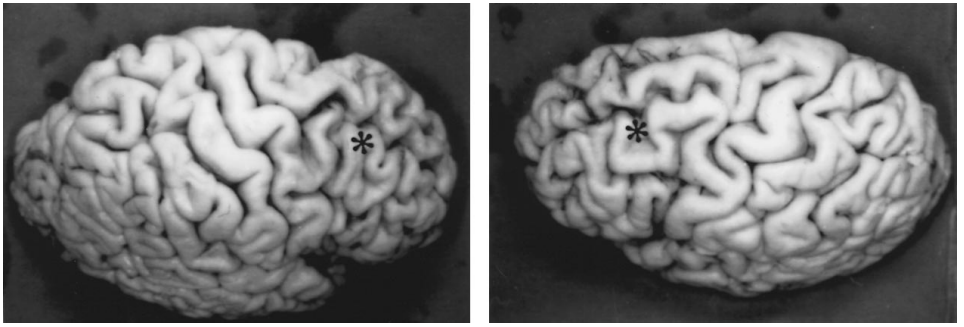


FIG. 2. Macroscopic image of LEA's brain in left lateral (a) and right lateral (b) view. Note that right frontal gyri are thinner and right frontal sulci more widened than the corresponding structures on the left side. The asterisk indicates the frontal lobe.

through the brain, the frontal cortical pallium was thinner while subjacent white matter was attenuated, displaying variable loss of myelinated fibers. The right frontal periventricular white matter close to the corpus callosum and nucleus caudatus showed slight softening macroscopically (see MRI image, Fig. 1A). The thickness of the anterior part of the corpus callosum was decreased. In the subcortical region, there was macroscopically bilateral mild atrophy of the putamen, globus pallidus, thalamus, hippocampus, and amygdala, while the nucleus caudatus displayed moderate degeneration. Ventricular dilatation was most apparent in the frontal horns, particularly at the right side.

Microscopic Findings

Neocortex. Microvacuolar degeneration and loss of (mainly) pyramidal cells were found almost exclusively in frontal (BA9/46, BA10, and BA12) and temporal areas (BA22/38, and BA21). A mild astrocytosis (GFAP immunostaining) was found in layer I and II and at the junction of gray and white matter. Furthermore, severe pyramidal neuron loss was apparent predominantly in layer II/III but not in layer V/VI. The immunohistochemistry by antibody against neurofilament (SMI-32) showed that large (pyramidal) neurons were more affected than small ones and that cell loss was greater in frontal and temporal than in other cortical regions, more so in the right hemisphere. No neurofibrillary pathology or other argentophilic inclusions were found using Bielschowsky silver-impregnation and tau (AT-8) immunostaining. No "ballooned" or "Pick" cells were seen.

Allocortex. In the hippocampus and amygdala no major histopathological changes were shown, though there was a slight astrocytosis in the gyrus dentatus and CA4, a mild granulovacuolar pathology in CA1, and neuronal loss in the entorhinal region. A single tangle on the section could be revealed by the Bielschowsky method in CA1 and entorhinal cortex. The major subcortical nuclei in the midbrain and brain stem as well as the cerebellum were largely unaffected, except the substantia nigra where neuronal loss, pigment spreading, and hypopigmentation were prominent features. No neurofibrillary pathology or Lewy bodies were detected. Widening of perivascular spaces with increased gliotic reaction and loss of myelin was found diffusely in patched form throughout the white matter but predominantly in the frontal lobe. The above-mentioned lesion in the right frontal periventricular region was characterized microscopically by the presence of reactive astrocytosis, great loss of myelin and axons, and microcystic degeneration around the vessels, a feature characteristic of incomplete white matter infarcts. The lesion extended and decreased gradually in the surrounding white matter (lateral stratum subcallosum) of the frontal lobe (Fig. 1B).

Jag våret båt bommer åt kopet äbbe lå lasse össe
 hommor påtet jag ävart över skulle jag och jag oss.

FIG. 3. Message written by LEA on blank paper, illustrating preserved graphetics and nonverbal visuospatial disposition. The message is largely neologistic. Orthographic transcription (English translation is in parentheses and nonwords are marked with an asterisk): Jag [I] *våret båt [boat] *bommer åt [to/ate homonym] *kopet *äbbe få [get/few homonym] *fasse *össe *hommor *påtet jag [I] *ävart över [over] skulle [should] jag [I] och [and] jag [I] oss [us].

Observations on Written Language Output

Material and method. LEA's severe behavioral and executive disorder precluded formal testing. Written material was produced spontaneously or as responses to written questions and to pictures. Written naming was elicited through an improvised play with drawings (e.g., of musical instruments). In sum, 216 word-sized units (words and nonwords) were gathered. Word-sized units were defined as any letter strings separated by blank space and/or punctuation marks. Word-sized unit type was defined as the presence of a certain word form. Word-sized unit token was defined as the occurrence of a certain word-sized unit type (i.e., its frequency). The sample allowed observations on graphetic features, differences in length between words and nonwords, syllable-internal structure, type-token ratios, as well as a limited error analysis based on comparison between nonwords and their inferred targets. Targets were inferred only for nonwords associated with pictures.

General writing behavior. LEA wrote mainly in cursive script. He made few revisions and never corrected errors. Nonverbal visuospatial disposition was normal (Fig. 3).

Evidence for jargonagraphia. Letters were easily recognized. All letters in the Swedish alphabet were represented save for the infrequent Q, W, X, and Z. Proper nouns and some nonwords were produced with majuscules in initial position. A high proportion of nonwords obtained: 47% when all word-sized unit tokens are included, or 61% when only word-sized unit types are counted. Some nonword syllables lacked nuclei (e.g., ⟨ugäggr⟩ and ⟨tll⟩) but most of them obeyed this constraint on syllable-internal structure. The personal pronoun ⟨jag⟩ ('I') and the conjunction ⟨och⟩ ('and') were the most frequent words, constituting nearly one-third of the word tokens. In contrast, nonwords were highly varied, as only two nonwords were produced more than once. Median word-sized unit length was three letters for words and six letters for nonwords (Fig. 4). The difference in length between words and nonwords was highly significant (Mann-Whitney U : $z = 6.50$, $p < .000001$). This difference refers to word and nonword types; hence it is not due to the repeated occurrence of certain short word tokens (see above).

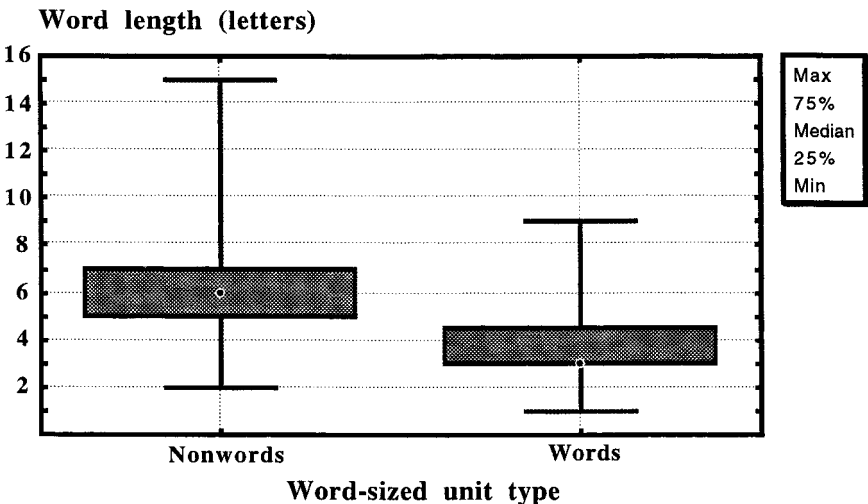


FIG. 4. Variation in length of words and nonwords produced by LEA.

Target words cannot be safely identified for most of the nonwords. Multiple spelling errors obtain when nonwords produced as naming attempts are compared with their inferred targets. Some show substitutions, insertions, deletions, and transpositions, e.g., ⟨klarinet⟩ “clarinet” → CANNERA; ⟨köttbullar⟩ “meatballs” → UGÄGGDR. However, some nonwords do not involve transpositions but only substitutions, omissions, and/or insertions (e.g., ⟨dragspel⟩ “accordion” → RAMSEN; ⟨trumpet⟩ “trumpet” → TRÖBE; ⟨gitarr⟩ “guitar” → GÖTORRE; ⟨tuba⟩ “tuba” → TRUPPE).

DISCUSSION

The patient reported here developed jargonagraphia in the context of FTD. This was unexpected, as spelling is considered relatively intact in this syndrome. Even in semantic dementia, a closely related syndrome associated with predominant left basitemporal atrophy, spelling is relatively preserved save for words with atypical orthography. Why, then, do not all cases of FTD develop jargonagraphia? One clue may be that lesions vary in FTD. The atrophy in our patient was bilateral but asymmetric, the right frontotemporal region being more affected. There was also a white matter lesion in the right anterior periventricular zone at the level of the subcallosal fasciculus. The fasciculus subcallosus is involved in motor speech function, specifically connecting frontal and cingular speech areas with the basal ganglia (Naeser, Palumbo, Helm-Estabrooks, Stiassny-Eder, & Albert, 1989; Jürgens, 1982). This leaves three rough alternatives as to the cause of the jargonagraphia. (a) It was caused by left frontotemporal cortical damage. (b) It was caused by right frontotemporal cortical and right frontal subcortical damage. (c) It was caused by a combination of left and right frontotemporal lesions. Alternative (a) implies that the right hemisphere lesions did not contribute to the jargonagraphia. However, jargonagraphia is usually a concomitant of Wernicke’s aphasia, which typically requires a left posterior lesion. Such a lesion was not present, nor was there a Wernicke’s aphasia. Alternative (b) implies that this was a case of crossed agraphia. Indeed, jargonagraphia is sometimes reported in crossed aphasia (see, e.g., Hashimoto, Tanaka, & Yoshida, 1998). However, jargonagraphia may also reflect disinhibition of (impaired) left hemisphere language processors following right hemisphere lesions (cf. Gil, Neau, Aubert, Fabre, & Tantot, 1995). This interpretation is consistent with alternative (c). Note, however, that most nonwords retained basic syllable-internal structure. This means that spelling was constrained phonologically to some extent. Accordingly, jargonagraphia in this case can be explained only in part by disinhibition of graphomotor engrams (cf. Hashimoto, Tanaka, & Yoshida, 1998). Further, the difference in length between words and nonwords (nonwords being much longer than words) points toward a working-memory deficit. Working memory is of limited capacity. When a longer word is retrieved from the lexicon, it takes more working memory to maintain its form than for a short word. This is also consistent with neuropathology. The selective layers II and III neuronal loss in the frontotemporal associative cortical areas indicates that at least associative and commissural fibers were particularly affected. The atrophied anterior corpus callosum further indicates that pyramidal neurons in layers II and III which prone commissural fibers to the opposite hemisphere were heavily degenerated. The specific regional and laminar nature of neuronal loss suggests that functionally related hierarchically centrifugal or feedforward projections (originating in layers II/III) were impaired. Due to differences in the extent of cortical atrophy, it might be suggested that the neuronal degeneration in the right hemisphere preceded that of the left side. Moreover, degeneration of pyramidal neurons in the superficial layers indicates a decrease of the receptive fields where centrifugal or feedback projections (functionally and hierarchically lower) are partially terminated (cf. Felleman & Van Essen, 1991; Barbas & Rempel-Clower, 1997). Hence the main damage in the neu-

ronal network was localized in frontal cortices and in the specific cortico-subcortical projection system. Moreover, a white matter lesion localized in the region of the subcallosal fasciculus and lateral stratum subcallosum might have contributed to the nonfluent aphasia by disconnecting the cortical area and subcortical regions (cf. Naeser, Palumbo, Helm-Estabrooks, Stiassny-Eder, & Albert, 1989; Jürgens, 1982), indicating that the neuronal network impairment was localized in the executive and perception-action domain of the right prefrontal cortex (Fuster, 1997).

To sum up, this may be the first documented case of jargonagraphia in autopsy-verified FTD and, for that matter, in any primary degenerative dementia. It is possible that the agraphia emerged through combined left and right anterior cerebral lesions involving cortico-subcortical connections. Importantly, these lesions disrupted the neuronal substrates of working memory. We conclude, therefore, that these factors may have conduced to the development of jargonagraphia.

REFERENCES

- Barbas, H., & Rempel-Clower, N. (1997). Cortical structure predicts the pattern of corticocortical connections. *Cerebral Cortex*, **7**, 635–646.
- Black, S. E. (1996). Focal cortical atrophy syndromes. *Brain and Cognition*, **31**, 188–229.
- Bozeat, S., Gregory, C. A., Ralph, M. A., & Hodges, J. R. (2000). Which neuropsychiatric and behavioural features distinguish frontal and temporal variants of frontotemporal dementia from Alzheimer's disease? *Journal of Neurology, Neurosurgery, and Psychiatry*, **69**, 178–186.
- Cappa, S. F., Cavallotti, G., & Vignolo, L. A. (1986). Jargonagraphia: Clinical and neuropsychological notes. *Neuropsychologia*, **25**, 281–286.
- Felleman, D. J., & Van Essen, D. C. (1991). Distributed hierarchical processing in the primate cerebral cortex. *Cerebral Cortex*, **1**, 1–47.
- Fuster, J. M. (1997). Network memory. *Trends in Neurosciences*, **20**, 451–459.
- Gil, R., Neau, J. P., Aubert, I., Fabre, C., & Tantot, A. M. (1995). Graphomimie anosognosique: Variété particulière d'hypergraphie au cours d'un infarctus sylvien droit. *Revue Neurologique (Paris)*, **151**, 198–201.
- Gustafson, L., Hagberg, B., & Ingvar, D. H. (1978). Speech disturbances in presenile dementia related to local cerebral blood flow abnormalities in the dominant hemisphere. *Brain and Language*, **5**, 103–118.
- Hashimoto, R., Tanaka, Y., & Yoshida, M. (1998). Selective kana jargonagraphia following right hemispheric infarction. *Brain and Language*, **63**, 50–63.
- Holland, A. L., McBurney, D. H., Moossy, J., & Reinmuth, O. M. (1985). The dissolution of language in Pick's disease with neurofibrillary tangles: A case study. *Brain and Language*, **24**, 36–58.
- Jürgens, U. (1982). Afferents to the cortical larynx area in the monkey. *Brain Research*, **239**, 377–389.
- Naeser, M. A., Palumbo, C. L., Helm-Estabrooks, N., Stiassny-Eder, D., & Albert, M. L. (1989). Severe nonfluency in aphasia: Role of the medial subcallosal fasciculus and the other white matter pathways in recovery of spontaneous speech. *Brain*, **112**, 1–38.
- Neary, D., Snowden, J. S., Gustafson, L., Passant, U., Stuss, D., Black, S., Freedman, M., Kertesz, A., Robert, P. H., Albert, M., Boone, K., Miller, B. L., Cummings, J., & Benson, D. F. (1998). Frontotemporal lobar degeneration: A consensus on clinical diagnostic criteria. *Neurology*, **51**, 1546–1554.
- Snowden, J. S., Neary, D., & Mann, D. M. A. (1996). *Fronto-temporal lobar degeneration: Fronto-temporal dementia, progressive aphasia, semantic dementia*. New York: Churchill Livingstone.