

## Tract hemianopia resulting from traumatic distal internal carotid artery dissection

Stephen K. Sauer,\* MD; William Burnette,† MD; Robert A. Egan,\* MD

**I**nternal carotid artery (ICA) dissection occurs after injury, but uncommonly in the distal ICA. We describe an optic tract lesion secondary to traumatic distal ICA dissection.


### CASE REPORT

A 29-year-old restrained driver was involved in a head-on automobile collision and incurred a closed head injury with momentary loss of consciousness. On awakening, he immediately noticed a left-sided visual field deficit. Neuro-ophthalmic examination was normal except for a left afferent pupillary defect and complete left homonymous hemianopia. Magnetic resonance imaging (MRI) showed a small crescent of abnormal signal in the distal right ICA consistent with arterial dissection (Fig. 1). Magnetic resonance angiography gave normal results. There was bright signal in the right optic tract on fluid-attenuated inversion-recovery sequences (Fig. 2).

Examination 5 months later confirmed the pupil defect and showed nerve fibre layer dropout superiorly and inferiorly in the right eye (Fig. 3, top). There was nasal optic nerve pallor in the left eye (Fig. 3, bottom). Repeat coronal T<sub>2</sub>-weighted MRI showed interval development of atrophy of the right optic tract (Fig. 4).

### COMMENTS

To our knowledge, this is the first reported case of an optic tract lesion due to traumatic ICA dissection. One case of a traumatic optic tract lesion has been reported secondary to a juxtaseellar hematoma.<sup>1</sup> It is doubtful that compression played a role in our patient since no hematoma was present. Infarction of the optic tract via the anterior choroidal artery was likely since this vessel originates from the distal ICA. Embolization from nontraumatic proximal ICA dissection has previously been reported.<sup>2</sup>

In cases of unexplained homonymous visual field loss after injury, attention to pupil defects may suggest a diagnosis of ICA dissection and lead to appropriate management. 

### REFERENCES

1. Katayama Y, Yoshida K, Ogawa H, Tsubokawa T. Traumatic homonymous hemianopsia associated with a juxtaseellar hematoma after acute closed head injury. *Surg Neurol* 1985;24:289-92.
2. Archer JS, Gracies JM, Tohver E, Crimmins DS, O'Leary BJ, Milder DG. Bilateral optic disk pallor after unilateral internal carotid artery occlusion. *Neurology* 1998;50:809-11.

**Key words:** carotid artery dissection, visual field, vision loss, stroke, trauma, optic tract

From \*the Neuro-Ophthalmology Unit, Casey Eye Institute, Portland, Ore., and †the Department of Neuro-Radiology, Oregon Health Sciences University, Portland, Ore.

Originally received May 2, 2001  
Accepted for publication July 6, 2001

Reprint requests to: Dr. Robert A. Egan, Casey Eye Institute, 3375 SW Terwilliger Blvd., Portland OR 97201, USA; fax (503) 494-4286; eganr@ohsu.edu

*Can J Ophthalmol* 2001;36:366-7

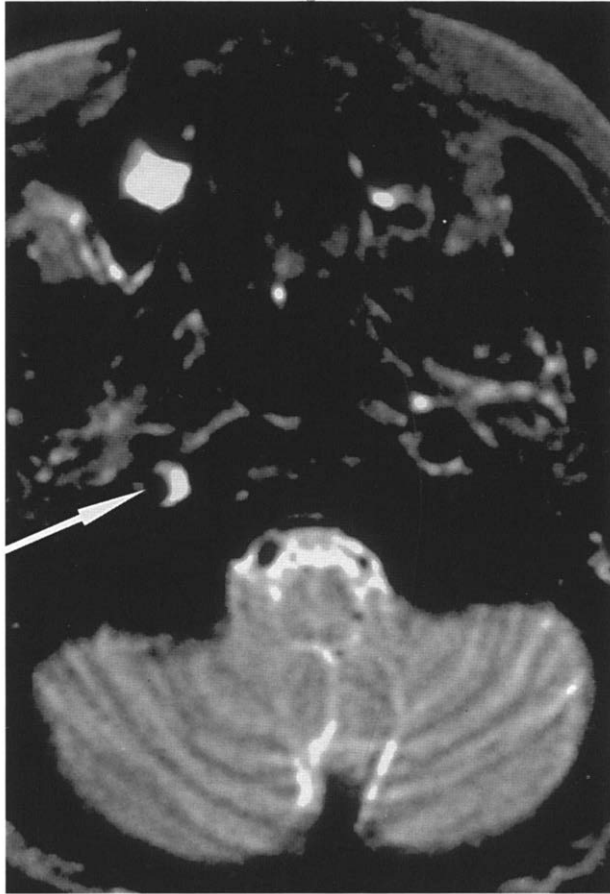


Fig. 1—Axial T<sub>2</sub>-weighted magnetic resonance imaging (MRI) image of brain, showing small crescent of abnormal signal in distal right internal carotid artery (arrow) consistent with arterial dissection.

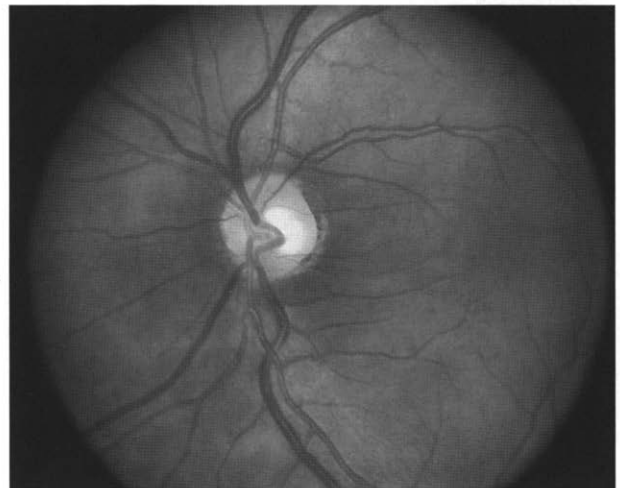
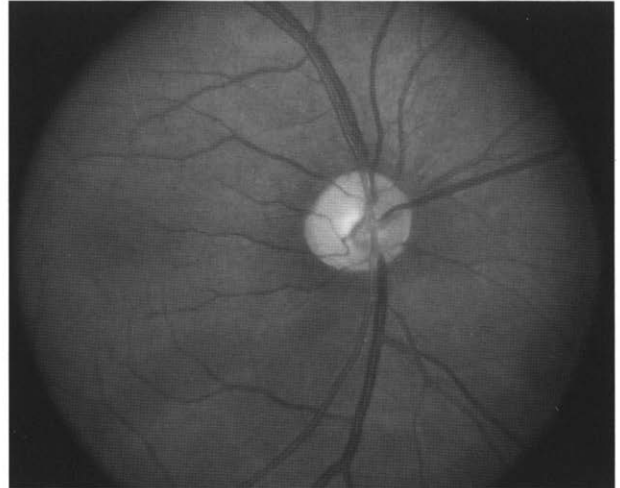


Fig. 3—Fundus photographs obtained 5 months after injury. Top: Right eye. There is very little arcuate nerve fibre layer present superiorly and inferiorly. Bottom: Left eye. By comparison, nerve fibre layer is very robust. Note nasal pallor of optic nerve (i.e., "bow-tie" atrophy).

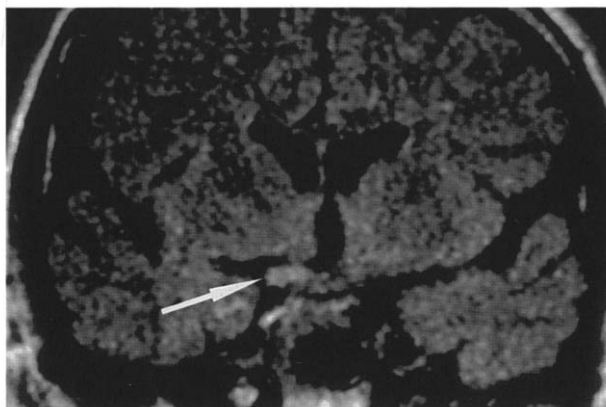


Fig. 2—Coronal fluid-attenuated inversion-recovery MRI image of brain through optic tract. Arrow indicates right optic tract, which is bright and enlarged.

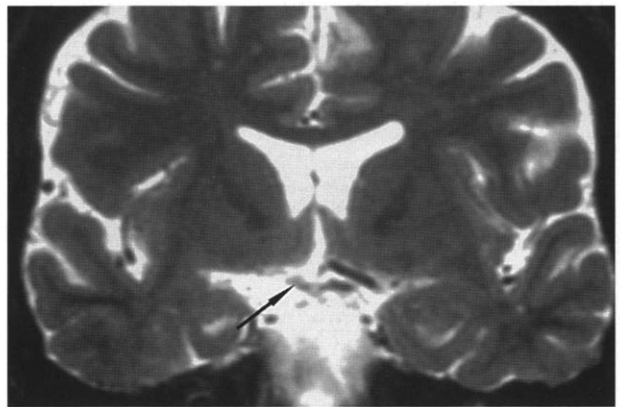


Fig. 4—Coronal T<sub>2</sub>-weighted MRI image of brain through optic tract obtained 5 months after injury, showing atrophic optic tract (arrow).