



## Case Report

## Cerebral venous thrombosis in Down's syndrome

Sultan Tarlaci <sup>a,\*</sup>, Ayse Sagduyu <sup>a,b</sup><sup>a</sup> Department of Neurology, Medical Faculty, Ege University, Bornova, 35040 Izmir, Turkey<sup>b</sup> Intensive care unit, Medical Faculty, Ege University, Bornova, Izmir, Turkey

Received in revised form 17 July 2001; accepted 17 July 2001

**Abstract**

We report the first case of cerebral venous thrombosis (CVT) diagnosed in an adult with Down's syndrome (DS). A 25-year-old man with DS was admitted because of a generalized tonic–clonic seizure and prolonged postictal period. Cerebral magnetic resonance imaging (MRI) and MR venography revealed CVT. No particular cause of the thrombosis was identified. CVT may be an unusual cause of stroke in DS. © 2001 Elsevier Science B.V. All rights reserved.

*Keywords:* Down's syndrome; Cerebral venous thrombosis; MRI

**1. Introduction**

The most common cardiovascular and gastrointestinal disorders in Down's syndrome (DS) are congenital heart disease (atrioventricular canal and ventricular septal defects), bowel atresias and Hirschsprung's disease [1]. In recent years, several reports have suggested that children with DS can also develop Moyamoya vasculopathy [2]. The association of cerebral venous thrombosis (CVT) with a variety of pathological states is well established [3–5]. No link between CVT and DS has yet been defined. We present the first reported case of an adult with DS who exhibited laboratory and clinical findings that were consistent with CVT.

**2. Case report**

A 25-year-old man with DS was admitted after suffering a generalized tonic–clonic seizure and prolonged postictal period. He had no history of seizures, toxic exposure or any systemic infection. His past medical history was unremarkable and he was not on any

medication. There was no family history of cerebrovascular or thromboembolic disorders. No other risk factors for venous sinus thrombosis such as head injury, otitis media, dehydration were identified. Initial physical examination was normal except for postictal confusion. The optic disks and retinae were normal in appearance. The blood pressure was 130/85 mmHg, the pulse rate was 76 per min and rhythmic. The body temperature was also normal. Ear nose and throat (ENT) examination was normal.

Complete blood count, liver function tests, serum sodium and osmolality, chest X-ray, antinuclear antibody and rheumatoid factor levels, serum protein electrophoresis, VDRL, serum IgG, IgA and IgM, C3, C4 and antiphospholipid antibody levels were all within normal ranges, except for erythrocyte sedimentation rate (Westergren) of 50 mm/h. Coagulation and thrombotic screens (lupus anticoagulant, prothrombin time, partial thromboplastin time, protein S, protein C, factor V Leiden and antithrombin III) were also normal. Thyroid function tests, echocardiography and electrocardiogram did not reveal any pathology. Cerebrospinal fluid was clear with normal opening pressure. Cranial computed tomography with and without contrast was normal. Family history for venous thromboembolism was negative.

\* Corresponding author. Tel.: +90-232-343-0174.

E-mail address: starlaci@hotmail.com (S. Tarlaci).

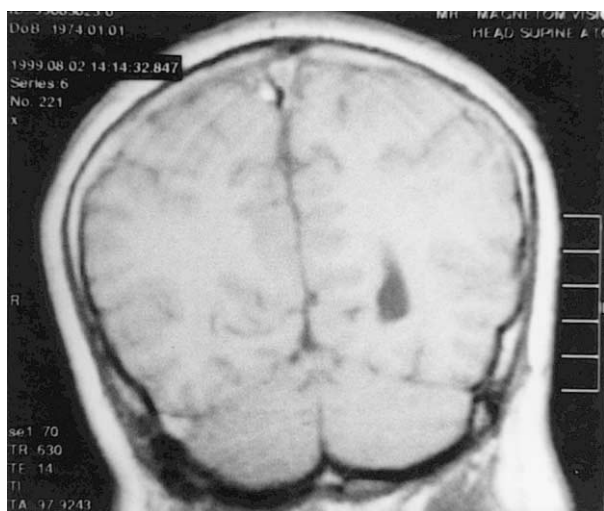

Fig. 1. T<sub>1</sub>-weighted coronal MRI image demonstrates a hyperintense signal of subacute thrombus within the right transverse and superior sagittal sinuses and an isointense signal in the left transverse sinus (normal flow void in the left transverse sinus).

One day after his admission to hospital, his muscle strength was moderately reduced on the left side and then he developed a progressive weakness of the left arm (1/5) and leg (2/5), and the left plantar response became extensor. He became somnolent and had two generalized tonic–clonic epileptic seizures during the second day of admission. Cranial magnetic resonance (MR) revealed hyperintense lesions in both frontal regions indicating venous hemorrhage on T<sub>2</sub>-weighted images. T<sub>1</sub>-weighted images demonstrated a hyperintense signal associated with subacute thrombosis within the right transverse and posterior part of the sagittal sinus (Fig. 1), subsequently confirmed by MR venography (Fig. 2).

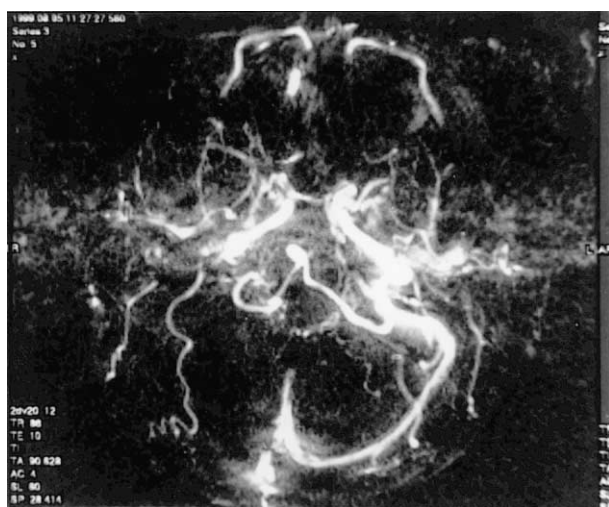


Fig. 2. MR venography demonstrates the thrombosis (void signal) within the right transverse and sigmoid sinuses. Note the normal flow in the left transverse and sigmoid sinuses.

Treatment was initiated with continuous intravenous high dose heparin for CVT and phenytoin for seizure control. He was later put on oral anticoagulation (INR 2.5). The left sided weakness moderately improved in the following 10 days. His neurological recovery was complete after 6-months on follow-up assessment and the control magnetic resonance imaging (MRI) showed that the old venous thrombosis was completely replaced by signs of recanalization on both the posterior part of sagittal and the right transverse sinuses.

### 3. Discussion

Patients with DS appear to be predisposed to strokes from emboli as a result of congenital heart disease [1]. Strokes in children with DS may also occur as a consequence of Moyamoya vasculopathy [2]. Moyamoya in a child with DS is frequently accompanied by manifestations of ischemia; cerebral hemorrhage is unusual in patients younger than 15 years of age.

CVT has been well documented in children and adults in association with a variety of other diseases [5]. However, there have been no previous reports of CVT in patients with DS. Causes of CVT include six general categories, blood disorders (disorders of coagulation and thrombolytic proteins, of red blood cells or of platelets), infection, inflammatory disorders, structural damage to venous sinuses from local trauma or adjacent lesions, miscellaneous, and finally, idiopathic [5]. Activated protein C resistance due to factor V Leiden has recently been established as an important risk factor for CVT [4]. However, in 20–35% of cases, no cause could be identified.

The mechanism underlying the onset of CVT in DS is unclear. However, there are some commonly encountered pathologies in DS one or several of which may be responsible for the development of CVT in the present patient. Children with DS have an 18–20-fold increased incidence of leukemia [6]. Hearing loss is another common problem in DS, possibly related to the increased incidence of undiagnosed otitis media in this population. One can, therefore, speculate that patients with DS may carry a risk for developing CVT due to leukemia or otitis media. Furthermore, DS also appears to have a relationship with autoimmune disorders. It has been shown that child with trisomy 21 affected by Moyamoya and Graves' disease, associated with antithyroid microsomal antibodies and antiphospholipid antibodies [7,8]. Antiphospholipid antibodies are known to be related with increased risk of venous and arterial thrombotic events, including CVT [8,9]. However, in our patient there was no evidence for the presence of any of these pathologies. Therefore, none of these reported associations appear to be a responsible factor for the development of CVT in this patient.

Hyperhomocysteinemia are associated with increased risk of stroke, cardiovascular disease, and venous thrombosis. Cerebrovascular manifestations of hyperhomocysteinemia are primarily those of ischemic stroke or CVT. The most frequent cause of severe hyperhomocysteinemia is homozygous deficiency of cystathionine  $\beta$ -synthase. Kraus et al. [10] demonstrated that mean activity of cystathionine  $\beta$ -synthase is 166% in cultured fibroblasts from DS patients compared with controls. Indeed, arteriosclerosis and CVT were rare in DS [11].

The clinical presentation of the present patient, according to our knowledge as being the first reported case, suggests that CVT can develop in an adult with trisomy 21 syndrome. Therefore, despite its rarity, CVT should be considered among the unusual causes of stroke in DS. Consequently, we suggest that CVT should be kept in mind for the differential diagnosis of stroke in DS, because of the fact that the prognosis of treated CVT patients is considerably favorable [5].

### Acknowledgements

Authors thank to Bulent Turman, for his review of the paper.

### References

[1] Kriss VM. Down syndrome: imaging of multiorgan involvement.

*Clin Pediatr* 1999;38:441–9.

- [2] Cramer SC, Robertson RL, Dooling EC, Scott RM. Moyamoya and Down syndrome. Clinical and radiological features. *Stroke* 1996;27:2131–5.
- [3] Daif A, Awada A, al-Rajeh S, Abduljabbar M, al Tahan AR, Obeid T, Malibary T. Cerebral venous thrombosis in adults. A study of 40 cases from Saudi Arabia. *Stroke* 1995;26(7):1193–5.
- [4] Ludemann P, Nabavi DG, Junker R, et al. Factor V Leiden mutation is a risk factor for cerebral venous thrombosis: a case–control study of 55 patients. *Stroke* 1998;29:2507–10.
- [5] Bousser MG. Cerebral venous thrombosis: diagnosis and management. *J Neurol* 2000;247:252–8.
- [6] Seibel NL, Sommer A, Miser J. Transient neonatal leukemoid reactions in mosaic trisomy 21. *J Pediatr* 1984;104:251–4.
- [7] Leno C, Mateo I, Cid C, Berciano J, Sedano C. Autoimmunity in Down's syndrome: another possible mechanism of Moyamoya disease. *Stroke* 1998;29:868.
- [8] Christopher R, Nagaraja D, Dixit NS, Narayanan CP. Anticardiolipin antibodies: a study in cerebral venous thrombosis. *Acta Neurol Scand* 1999;99(2):121–4.
- [9] Guariso G, Ruffatti A, Casonato A, Drigo P, Ghirardello A, Zancan L. Antiphospholipid syndrome in a child with trisomy 21: the relationship between anticardiolipin G antibodies and the von Willebrand factor. *Clin Exp Rheumatol* 1992;10:613–6.
- [10] Kraus JP, Williamson CL, Figaira FA, Yang-Feng TL, Munke M, Francke U, Rosenberg LE. Cloning and screening with nanogram amounts of immunopurified mRNAs: cDNA cloning and chromosomal mapping of cystathionine  $\beta$ -synthase and the  $\beta$ -subunit of propionyl-CoA carboxylase. *Proc Natl Acad Sci* 1986;83:2047–51.
- [11] Murdoch JC, Rodger JC, Rao SS, Fletcher CD, Dunnigan MG. Down's syndrome: an atheroma-free model. *Br Med J* 1977;2:226–8.