

# Internuclear Ophthalmoplegia and Cerebellar Ataxia: Report of One Case

Yakup Krespi Ebru Aykutlu Oğuzhan Çoban Rezzan Tunçay Sara Bahar

Department of Neurology, Edip Aktin Stroke Unit, Istanbul School of Medicine, University of Istanbul, Istanbul, Turkey

## Key Words

Internuclear ophthalmoplegia · Cerebellar ataxia · Lacune

## Abstract

Deep hemispheric or brainstem small infarcts can lead to atypical lacunar syndromes. Unilateral internuclear ophthalmoplegia (INO) and cerebellar ataxia has not been reported previously. A 57-year-old hypertensive female presented with bilateral appendicular and left truncal cerebellar ataxia and right INO. Cranial MRI showed a right paramedian infarct of lacunar size located in the tegmentum of caudal mesencephalon. At this level the involvement of medial longitudinal fascicle (MLF) led to right INO and the lesion of brachium conjunctivum caused the bilateral cerebellar ataxia. Ipsilateral involvement of both cerebellofugal fibers, before and after decussation, was responsible for bilateral cerebellar ataxia.

Copyright © 2001 S. Karger AG, Basel

Besides the classical lacunar syndromes (pure motor stroke, pure sensory stroke, sensorimotor stroke and ataxic hemiparesis) 70 different neurological syndromes resulting from small hemispheric or brainstem deep infarcts have been reported in the literature [1]. These syn-

dromes constitute the atypical lacunar syndrome group [2]. We have recently seen a patient who presented with a combination of unilateral internuclear ophthalmoplegia (INO) and cerebellar ataxia that resulted from a small unilateral infarct ( $\leq 15$  mm) of the lower midbrain. This constellation of signs of unilateral INO and cerebellar ataxia has not been previously reported in the English literature.

## Case Description

A 57-year-old woman presented with acute onset of dizziness, diplopia, slurring speech and difficulty in walking. She had long-standing hypertension. Physical examination showed an elevated blood pressure (190/130 mm Hg) and was otherwise normal. Neurological examination revealed right INO and bilateral upbeat nystagmus on upgaze. There was no ptosis. The pupils were of equal size. Direct and indirect pupillary light reflex and accommodation response were present and symmetrical. She had bilateral appendicular ataxia in both the upper and lower extremities that was more pronounced on her left side and had a tendency to fall to the left when sitting or walking. Cranial magnetic resonance imaging showed a right paramedian infarct of lacunar size located in the tegmentum of the caudal mesencephalon (fig. 1). Doppler ultrasonographic examination of the neck vessels and intracranial magnetic resonance angiography were all normal. Transthoracic echocardiography and ECG showed left-ventricular hypertrophy in accordance with her long-standing hypertension. The presumed etiological diagnosis was small-vessel disease due to hypertension, and she was discharged on antiaggregant and antihypertensive therapy.

## KARGER

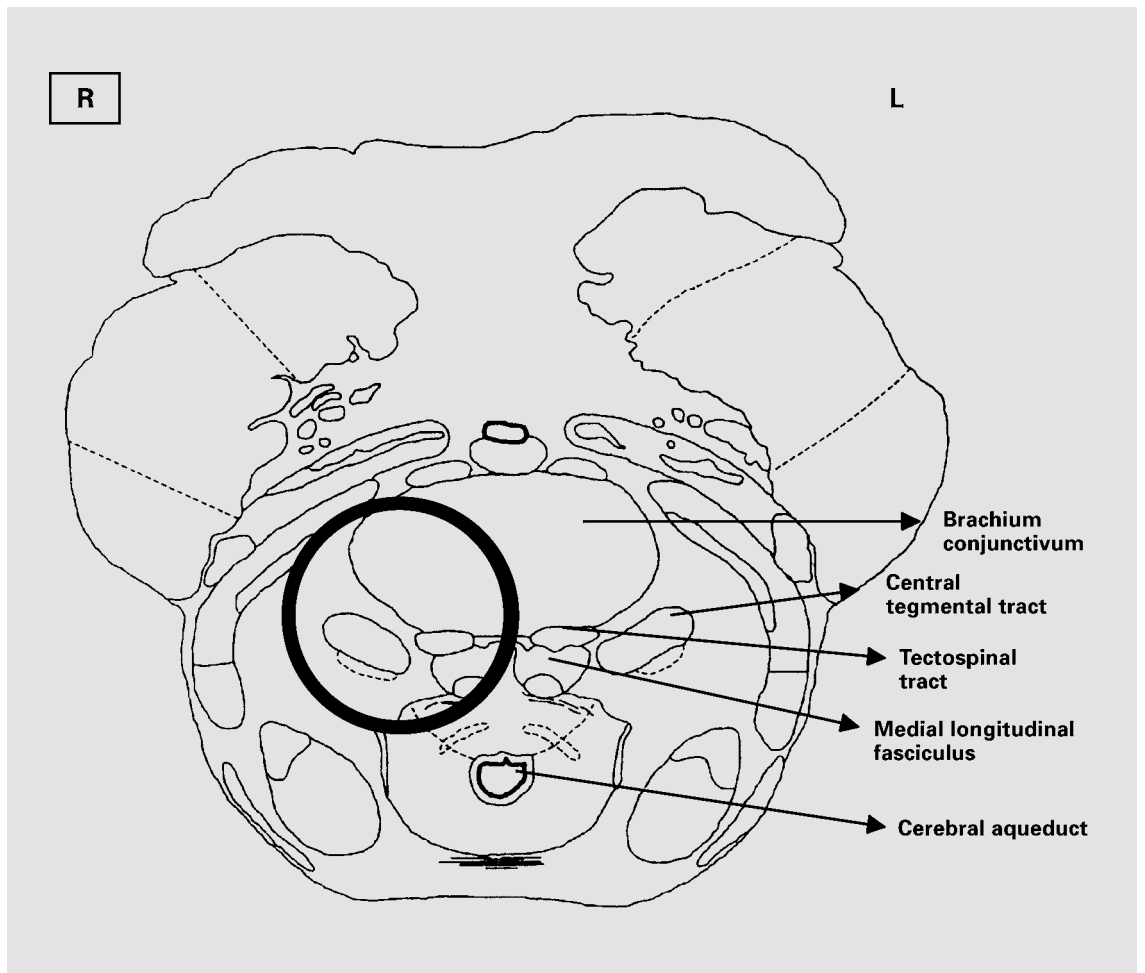
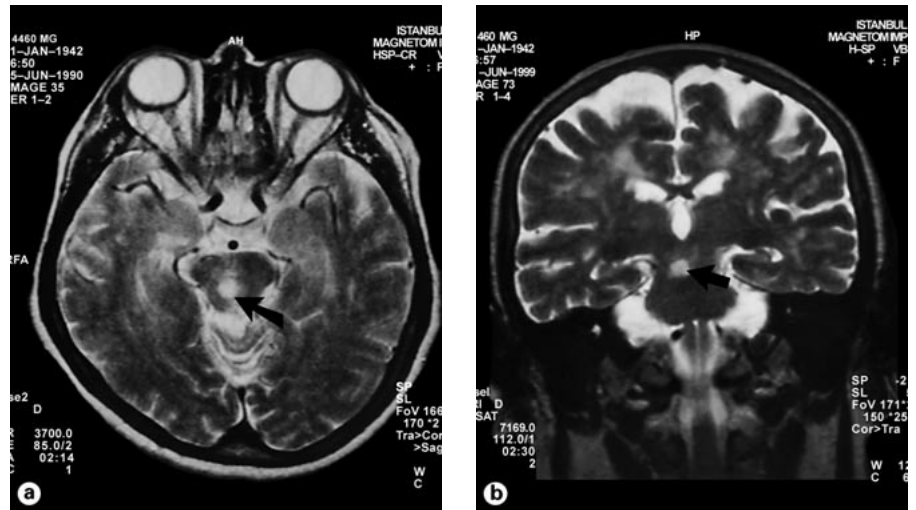
Fax + 41 61 306 12 34  
E-Mail [karger@karger.ch](mailto:karger@karger.ch)  
[www.karger.com](http://www.karger.com)

© 2001 S. Karger AG, Basel  
1015-9770/01/0124-0346\$17.50/0

Accessible online at:  
[www.karger.com/journals/ced](http://www.karger.com/journals/ced)

Yakup Krespi, MD  
Department of Neurology, Istanbul School of Medicine, University of Istanbul  
Millet cad, Çapa  
TR-34390 Istanbul (Turkey)  
Tel. +90 532 4850207, Fax +90 212 5334393, E-Mail [mykrespi@superonline.com](mailto:mykrespi@superonline.com)

**Fig. 1.** Axial (a) and coronal (b) T<sub>2</sub>-weighted images show a right paramedian infarct of lacunar size located in the tegmentum of the caudal mesencephalon at the level of the pontomesencephalic junction.



**Fig. 2.** Transverse section of the lower midbrain at the level of the inferior colliculus. The encircled region shows the lesion area of the patient. It includes the right MLF and the crossing fibers of the superior cerebellar peduncle.

## Discussion

Small infarcts of the brainstem and especially of the mesencephalon can cause numerous clinical syndromes. These syndromes constitute the atypical lacunar syndromes [3]. Patients with isolated INO [4], isolated truncal, unilateral appendicular or tetra-ataxia [5] due to small paramedian infarcts of the mesencephalic tegmentum have all been previously described. Cases presenting with the combined features of cerebellar ataxia and INO have been infrequently reported in the literature, and in such cases, in contrast to our patient, cerebellar ataxia was associated to bilateral INO [6, 7]. The right paramedian tegmental infarction in the lower midbrain explained all the clinical features in our patient. The involvement of the medial longitudinal fascicle (MLF) at this level led to

right INO and gaze-evoked upbeat nystagmus observed in our patient. In lesions of the MLF, the interruption of fibers that arise from the vestibular nuclei and control vertical gaze holding together with other features of vertical eye movements (i.e. vertical smooth pursuit, vestibulo-ocular reflex) is thought responsible for the gaze-evoked upbeat nystagmus [8, 9]. As in our case, this type of nystagmus can be seen in patients with unilateral INO, but is more severe in cases with bilateral involvement of the MLF [9]. Adjacent to the MLF, the lesion in the brachium conjunctivum caused the bilateral appendicular and left truncal cerebellar ataxia and was probably also responsible for the slurred speech (fig. 2). The ipsilateral involvement of both cerebellofugal fibers, before and after decussation, was responsible for the bilateral cerebellar ataxia.

## References

- 1 Fisher CM: Lacunar infarcts. A review. *Cerebrovasc Dis* 1991;1:311–320.
- 2 Hommel M, Besson G, Le Bas JF, Gaio JM, Polak P, Borgel F, Perret J: Prospective study of lacunar infarction using magnetic resonance imaging. *Stroke* 1990;21:546–554.
- 3 Besson G, Hommel M: Lacunar syndromes; in Pullicino PM, Caplan LR, Hommel M (eds): *Cerebral Small Artery Disease. Advances in Neurology*. New York, Raven Press, 1993, vol 62, pp 141–160.
- 4 Randolph S, Sacco RL, Kreuger R, Odel J: Dissociated vertical nystagmus and internuclear ophthalmoplegia from a midbrain infarction. *Arch Neurol* 1991;38:1304–1305.
- 5 Bogousslavsky J, Maeder P, Regli F, Meuli R: Pure midbrain infarction: Clinical syndromes, MRI, and etiologic patterns. *Neurology* 1994;44:2032–2040.
- 6 Okuda B, Tachibana H, Sugita M, Maeda Y: Bilateral internuclear ophthalmoplegia, ataxia and tremor from a midbrain infarction. *Stroke* 1993;24:481–482.
- 7 Sakakibara S, Sakato S, Shima T, Ide Y, Takamori M: Brainstem infarcts presented MLF syndrome and cerebellar ataxia. Report of three cases. *Rinsho Shinkeigaku* 1990;30:533–539.
- 8 Kirham TH, Katsarkas A: An electrooculographic study of internuclear ophthalmoplegia. *Ann Neurol* 1977;2:385–392.
- 9 Leigh RJ, Zee DS: Diagnosis of central disorders of ocular motility; in Leigh RJ, Zee DS (eds): *The Neurology of Eye Movements. Contemporary Neurology Series*. Philadelphia, Davis, 1991, vol 35, pp 378–530.