

Cerebrovascular Accident After Vacuum-Assisted Venous Drainage in a Fontan Patient: A Cautionary Tale

Marjan Jahangiri, FRCS, Alan Rayner, BS, Brian Keogh, FRCA, and Christopher Lincoln, FRCS

Department of Cardiac Surgery, Anesthesia, and Perfusion,
Royal Brompton Hospital, London, England

Vacuum-assisted venous drainage was used in a 24-year-old woman who underwent a redo Fontan procedure. She developed a hemiparesis, which is thought to be caused by cerebral air embolism.

(Ann Thorac Surg 2001;72:1727-8)

© 2001 by The Society of Thoracic Surgeons

Vacuum-assisted venous drainage (VAVD) is a relatively new concept that has gained popularity in the minimally invasive field by overcoming the higher resistance of the smaller cannulas used in this field. It is also gaining a place in redo operations and pediatric practice. In vitro experiments have shown arterial line emboli exacerbated by VAVD [1]. We report the case of a patient who developed a significant cerebrovascular accident after a redo Fontan procedure, where a VAVD was used during cardiopulmonary bypass.

A 24-year-old woman was admitted for a revision Fontan procedure. Her morphologic diagnosis was situs solitus, absent right atrioventricular connection (tricuspid atresia) and concordant ventriculoarterial connections. At the age of 15 months she underwent a modified Blalock-Taussig shunt. At 4 years of age she underwent a Fontan procedure, where a right atrial to right ventricular anastomosis was performed using a 20-mm Teflon graft. The atrial septum was closed with a patch of dura mater. At age 22 she developed intermittent atrial flutter for which she was commenced on amiodarone and warfarin, and more recently, she developed increasing cyanosis. Cardiac catheterization revealed significant stenosis of the conduit between the right atrium and the right ventricle. She therefore underwent revision of the Fontan procedure. Because of the very close proximity of the conduit to the posterior table of the sternum, cardiopulmonary bypass was established by cannulation of the left femoral vessels. Flow rate of 4 L/minute was achieved and the size of the arterial filter used was 40 microns. After 30 minutes of establishing bypass, VAVD was started using a low suction wall unit attached to the cardiotomy reservoir and regulated by pressure monitoring connected to

the venous inlet port. The pressure was maintained at no greater than -35 mm Hg (-20 to -35 mm Hg) at the venous inlet. The sternum was reopened uneventfully. While dissecting the superior vena cava and the right atrium, the electrocardiogram showed profound ST segment elevations suggestive of an ischemic episode. This was difficult to explain, since the aorta was not clamped, nor was there any dissection near the coronary arteries being performed. During the dissection, it had been noticeable that venous return was excellent, so good, in fact, that the free wall of the right atrium was closely approximated to the atrial septum and there was virtually no residual blood in the right atrium. The ascending aorta was immediately aspirated to check for air. After aspiration through an 18-gauge cannula, a considerable amount of air bubbles continued to exit through this vent site. Because we could not explain the source of air, having checked all the venous catheters and the purse strings around the cannulas, we elected to transfer the femoral arterial line to the ascending aorta. At this point, the arterial line filter was inspected for air bubbles in the trap area and none were seen. The VAVD was disconnected immediately. No further air bubbles were noted and the operation continued by antegrade cardioplegic arrest of the heart. The conduit was removed and the Fontan circulation was reconstructed by superior vena cava, right atrium to pulmonary artery anastomosis. The patient also underwent high frequency ablation of presumed conduction pathway. Her postoperative course was complicated by severe left-sided hemiparesis. Computed tomographic scan confirmed the presence of an infarct in the right hemisphere and in addition, subtle changes were noted in the left parietal lobe. The overall computed tomography appearance was thought to be consistent with cerebral air emboli. Her hemiparesis improved in the course of the next 8 months and currently she has minimal neurologic deficit.

Comment

This case alarmed us to a potential problem with the use of VAVD. The ST segment elevation changes and subsequent expulsion of air occurred before opening any of the cardiac chambers. The origin of the observed air was unclear and it appeared to be recollecting while the VAVD was applied. After the operation the perfusion system was checked and found to be in perfect working order. Specifically, the level sensor and the bubble trap in the circuit were both working effectively with no evidence of bubble formation within the circuit. The possibility of the presence of an atrial septal defect that would allow air to reach the left side was ruled out when the atrium was opened and a tense atrial septum was found. Also the possibility that suction would result in air from the pulmonary veins entering the left ventricle was considered. There was no evidence of air being drawn accidentally into the venous side of the circulation. Furthermore, immediately after discontinuing the VAVD, the bubbling through the aortic root vent ceased. All this made the VAVD the most likely mechanism of air embo-

Accepted for publication Jan 19, 2001.

Address reprint requests to Dr Jahangiri, Department of Cardiac Surgery, Great Ormond Street Hospital, Great Ormond St, London WC1N 3JH, England.

lism. Sources of arterial emboli entering the bypass circuit include bubble oxygenators, cardiotomy suctions, and venous reservoirs. The advances in oxygenators and venous reservoir designs [2] and the use of arterial line filters have reduced the risk of arterial emboli [3]. The venous air in the bypass circuit was always thought to be benign. In vitro studies have shown that VAVD increases the number of emboli reaching the patient when venous air is entrained into the bypass circuit. It also seems that the passage of venous air through the bypass circuit is delivery-rate dependent [1]. The use of transoesophageal echocardiography in the setting where VAVD is being used should be considered to detect the occurrence of air emboli and its egress from the pulmonary veins. We believe that VAVD has to be used expeditiously and cautiously in pediatric practice.

References

1. Willcox TW, Mitchell SJ, Gorman DF. Venous air in the bypass circuit: a source of arterial line emboli exacerbated by vacuum-assisted drainage. *Ann Thorac Surg* 1999;68:1285-9.
2. Jonas RA, Elliott MJ. Oxygenators for pediatric cardiac surgery. In: *Cardiopulmonary bypass in neonates, infants and young children*. Oxford: Butterworth-Heinemann Ltd, 1994: 173-85.
3. Treasure T. Interventions to reduce cerebral injury during cardiac surgery—the effect of arterial line filtration. *Perfusion* 1989;4:147-52.

Tension Pneumopericardium After Blunt Chest Trauma

Jon C. Gould, MD, and Michael A. Schurr, MD

Department of Surgery, University of Wisconsin Hospital, Madison, Wisconsin

We present a case of tension pneumopericardium in a patient involved in a motor vehicle crash. This patient was treated initially with a percutaneously placed drain and then definitively by a video assisted thoracoscopic pericardial window.

(*Ann Thorac Surg* 2001;72:1728-30)

© 2001 by The Society of Thoracic Surgeons

Tension pneumopericardium is a very unusual cause of hemodynamic compromise in the blunt trauma patient. The patients are often severely injured and a high index of suspicion is required to make the diagnosis. Other more common causes of hypotension, such as hemorrhagic shock or tension pneumothorax, should be considered first. A previous review article disclosed 12 cases of symptomatic pneumopericardium.

Accepted for publication Jan 19, 2001.

Address reprint requests to Dr Schurr, Department of Surgery, University of Wisconsin Hospital, 600 Highland Ave, Madison, WI 53792; e-mail: schurr@surgery.wisc.edu.

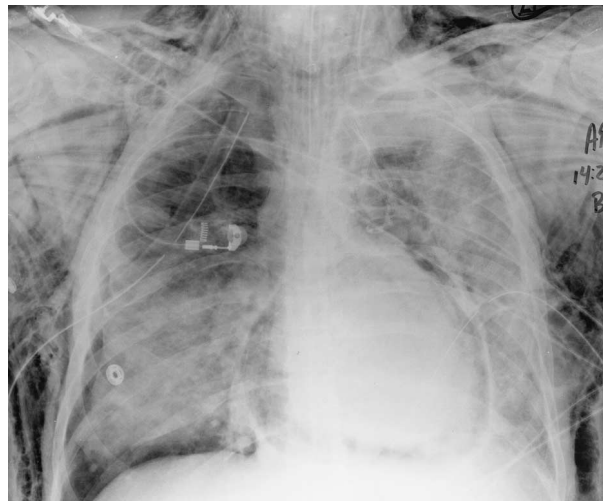


Fig 1. Chest x-ray showing pneumopericardium.

A 31-year-old man was an unrestrained front-seat passenger in a high-speed, single motor vehicle crash. A prolonged extrication was required. The patient was agitated and complained of shortness of breath at a referring hospital. He was orotracheally intubated and bilateral tube thoracostomies were performed for bilateral pneumothoraces on initial chest radiograph. He was then transferred to our institution for further therapy. On arrival the patient was noted to be tachycardic to 160 beats per minute, hypertensive with a systolic blood pressure of 190 mm Hg, and anemic with a hematocrit of 22%. Diagnostic peritoneal lavage was negative. Given the initial chest radiographic findings (Fig 1), a computed tomographic examination of the chest was obtained (Fig 2), which demonstrated large bilateral hemopneumothoraces, large pneumopericardium, multiple rib fractures,

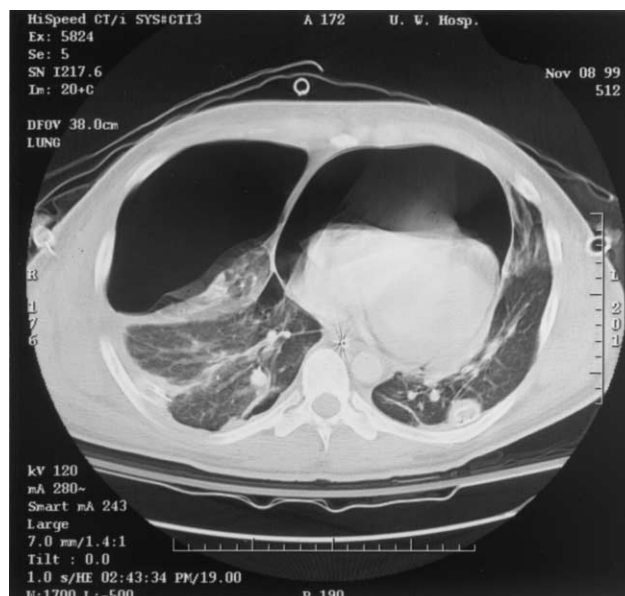

Fig 2. Computed tomographic (CT) scan demonstrating pneumopericardium with the heart displayed posteriorly by air.