

Ronald Boet
Wai S. Poon
Michael S. Y. Chan
Simon C. H. Yu

Childhood posterior fossa pial–dural arteriovenous fistula treated by endovascular occlusion

Received: 28 February 2001
Published online: 19 October 2001
© Springer-Verlag 2001

R. Boet · W.S. Poon (✉)
Department of Surgery,
Division of Neurosurgery,
Prince of Wales Hospital,
The Chinese University of Hong Kong,
Shatin, New Territories, Hong Kong
e-mail: wpoon@cuhk.edu.hk
Tel.: +852-26322624
Fax: +852-26377974

M.S.Y. Chan · S.C.H. Yu
Department of Diagnostic Radiology
and Organ Imaging,
Prince of Wales Hospital,
The Chinese University of Hong Kong,
Shatin, New Territories, Hong Kong

Abstract Posterior fossa dural arteriovenous fistulae in children are rare lesions that are difficult to treat effectively. We report a case of a 2-year-old girl with such a fistula, who presented clinically with progressive neurological deficit. The lesion was treated by endovascular occlusion, resulting in radiological and clinical cure.

Keywords Pial-dural arteriovenous fistula · Posterior fossa · Childhood · Embolization

Introduction

Posterior fossa dural arteriovenous fistulae are uncommon in children, and treatment protocols have therefore not been clearly defined. Surgery, endovascular occlusion and a combination of the two have all been used in the past. This report details the successful treatment of a patient in whom endovascular occlusion alone was used.

Case report

A 2-year-old girl presented to our unit with a history of progressive unsteadiness in walking. She had previously been seen in a paediatric outpatient clinic at the age of 1, after her mother had noticed that her head was suggestively large. At the later visit her developmental milestones were found to be normal. She was able to utter simple words and to walk without support. Her head circumference was 48 cm, which was on the 97th percentile for her age. Ultrasonography of the brain was normal. During follow-up clinic visits it was noted that the patient's head circumference was following the 97th percentile curve.

When the patient was 18 months of age, her mother noticed that her daughter became unsteady while walking, and this prompted her to seek medical attention. Clinical examination at this stage confirmed the patient's ataxia during walking but did not reveal any other neurological deficit. An MRI was performed, which revealed a dilated and tortuous left transverse sinus associated with a suspected venous aneurysm (Fig. 1). Some degree of hydrocephalus was also present, the nature of which was thought to be obstructive.

Cerebral angiography was carried out under general anaesthesia, which demonstrated the following:

1. There was a complex intracranial fistula with several feeders going directly and separately into a common ovoid varix measuring 14 mm×40 mm (Fig. 2a, b). The feeders derived from the right and left vertebral artery, the right and left internal carotid arteries via the posterior communicating arteries, and both thyro-cervical trunks via meningeal branches (Fig. 3).
2. The varix was drained by several draining veins with a course running posteriorly to the venous sinuses (Fig. 2a, b). There was evidence of underperfusion of the brain parenchyma owing to marked shunting of blood to the fistula.
3. Retrograde filling of the major venous sinuses and abnormally dilated deep veins were observed (Fig. 4).

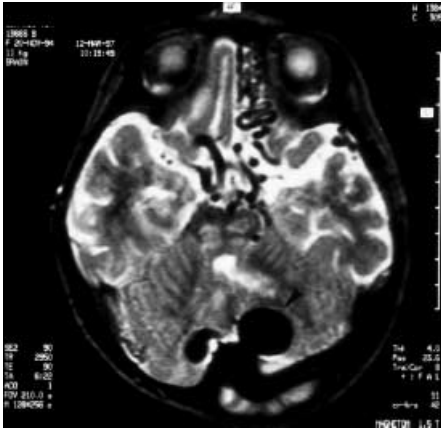


Fig. 1 Axial T2-weighted MR image shows a dilated left transverse sinus and suspected venous aneurysm (arrowhead)

While the patient was still under the same anaesthetic a 4-F catheter was placed in the left vertebral artery, followed by introduction of a microcatheter into the ovoid varix. The venous pressure measured in the varix was 50/30 mmHg. Eleven GDC-18 (Target Therapeutics, Fremont, Calif.) microcoils (two 14 mm/30 cm, two 12 mm/30 cm, two 10 mm/30 cm, one 9 mm/30 cm, two 8 mm/30 cm, and two 7 mm/30 cm) were detached inside the varix. Near-complete occlusion was achieved with the microcoils (Fig. 5). The microcatheter was pulled out slightly so that the tip was situated just at the entrance of the varix. Embucrylate glue, 1.9 ml of 25% (Histoacryl, B/Braun, Melsungen, Germany) in lipiodol, was then introduced under real-time digital subtraction fluoroscopy. This achieved complete occlusion of the varix. After embolization, four-vessel cerebral angiography revealed that the fistulae no longer filled, the normal vessels were all patent, and the brain perfusion had improved considerably (Fig. 6a, b).

Total anesthesia time was around 8 h. After the procedure the patient was transferred to our intensive care unit (ICU), where she was extubated the same evening. Her stay in the ICU was complicated by a generalized tonic-clonic seizure that required temporary re-intubation and management with appropriate anticonvulsants. Following this, the patient made an excellent recovery. Three years of follow-up visits after discharge from the hospital revealed complete resolution of her neurological symptoms. She has normal mobility and cognitive function, is attending a normal school, and achieves above average academic results.

Repeat cerebral angiography 1 year after the embolization procedure revealed that the fistulae remained occluded and the feeders and collaterals found previously had atrophied (Fig. 7a, b). Follow-up CT scans of the brain revealed resolution of the hydrocephalus.

Discussion

Though dural arteriovenous fistulae (DAVF) of the posterior fossa related to the sigmoid/transverse sinus or the tentorial incisura are not infrequently encountered in adults, DAVF in the posterior fossa are much less common in children. Adult variants of DAVF in this region are thought to be acquired lesions secondary to thrombosis of one of the large venous sinuses, with subsequent

enlargement of primitive dural arteriovenous connections leading to fistula formation. In contrast to this, posterior fossa DAVF in children are likely to be congenital [1].

According to Newton and Cronqvist, intracranial arteriovenous malformations can be classified into three types, pure pial, pial-dural and pure dural [9]. Mixed pial-dural malformations derive their blood supply from the cerebral or cerebellar arteries as well as from meningeal branches of vessels that supply the head and neck region. In our patient, feeders from both internal carotid and vertebral arteries as well as meningeal feeders originating from both thyro-cervical trunks supplied the venous varix. It seems reasonable therefore to name this malformation a pial-dural arteriovenous fistula.

One variant of an arteriovenous fistula in the posterior fossa in childhood is the vein of Galen aneurysm (VOGA). A true VOGA results from fistulous connections between the vein of Galen and branches of the deep cerebral arteries such as the choroidal, pericallosal and posterior cerebral arteries. A secondary VOGA is a pathologic dilatation of the vein of Galen resulting from drainage of an adjacent dural or parenchymous vascular malformation into this deep central vein [5].

Other childhood DAVF do not involve the vein of Galen, but rather the dura and/or the large venous sinuses. Their arterial supply is likely to come from one or more of the following: branches of the external carotid, such as the occipital arteries, meningeal branches of the vertebral arteries, and dural branches of the internal carotid artery. Only a few of these have been described in the literature, and their treatment is still controversial. It is sometimes difficult to determine from individual case reports whether these fistulae are purely dural or pial-dural, as the arteriogram report often describes feeders that are clearly not 'dural.'

Morita et al. reported three such fistulae in children [7]. Two of their cases were treated with a combination of surgery and embolization. One patient subsequently died. The third case was kept under observation only. These authors also reviewed the literature on another 18 cases. They reported a historical mortality of 38% and an anatomical cure in only 9%. They noted that these lesions were often enormous and commonly had a large associated venous lake. Symptoms and signs varied according to age, but commonly included a cranial bruit, cardiac manifestations, dilated scalp veins, macrocephalus, hydrocephalus, and delayed neurological development.

The natural history of a DAVF is unpredictable. In adults, various factors that predispose to a possible aggressive neurological course have been identified [2, 4]. Although there is no anatomical location of these fistulae in which they can definitely be said not to have such an aggressive course, Awad et al. concluded that lesions with leptomeningeal venous drainage or variceal or an-

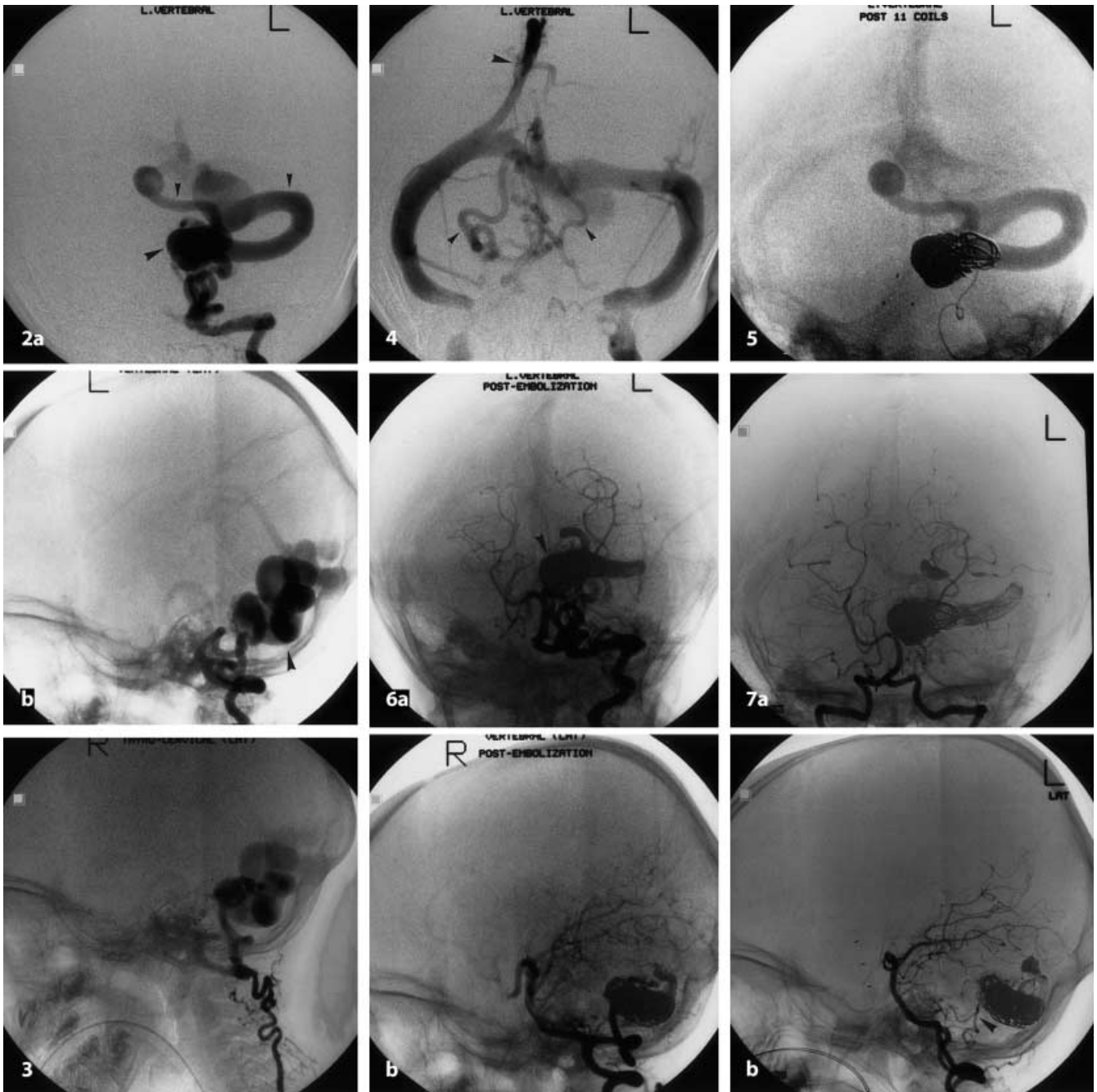


Fig. 2a, b DSA (digital subtraction angiography) of the left vertebral artery. **a** Anteroposterior view shows an ovoid varix (*large arrowhead*) and dilated draining veins (*small arrowheads*). **b** Lateral view with landmarking shows the ovoid varix (*arrowhead*)

Fig. 3 DSA (lateral view) of the right thyro-cervical trunk injection (with landmarking) shows the supply to the fistula

Fig. 4 DSA (anteroposterior view) of the left vertebral artery shows retrograde filling of the deep cerebral veins (*small arrowheads*) and the superior sagittal sinus (*large arrowhead*)

Fig. 5 DSA (anteroposterior view) of left vertebral artery with landmarking after detachment of 11 GDC coils

Fig. 6a, b DSA with landmarking immediately after treatment. **a** Anteroposterior view of the left vertebral arteriogram shows return of the normal distribution of the posterior circulation. Note the completely embolized fistula (*arrowhead*). **b** Lateral view of the right vertebral arteriogram

Fig. 7a, b DSA with landmarking 1 year after treatment. **a** Anteroposterior view of the left vertebral arteriogram shows complete occlusion of the fistula. **b** Lateral view of the left vertebral arteriogram shows atrophy of the feeders (*arrowhead*)

eurysmal venous dilatation, lesions draining into the vein of Galen, and lesions around the tentorial incisura had a particularly aggressive neurological course; lesions of the cavernous, sigmoid or transverse sinuses were least likely to behave aggressively.

Because posterior fossa DAVF in childhood are rare, with only a limited number of cases reported, the natural history of these lesions is not well known. Their course is, however, likely to be dynamic and progressive, with the development of cardiac and neurological manifestations [10]. Because of this, these lesions usually require attention and treatment. Treatment options include surgical resection or endovascular obliteration through either the transarterial or the transvenous route. A combination of these methods may be employed. The difficulty in treating these lesions is highlighted in a case report by Albright et al., detailing a posterior fossa DAVF in a 23-month-old child. Despite preoperative embolization and subsequent surgical excision, the fistula had re-canalized 10 months after surgery [1].

Complicated DAVF in adults have been successfully treated with combination therapy [3]. The aim of surgical therapy can vary. First, it can be used to expose and obliterate arterial feeders. Secondly, structures such as veins or venous sinuses can be exposed to allow embolization to be performed through these routes. Lastly, the fistula itself can be considered for resection. In children,

massive blood loss during surgery is of major concern, and endovascular methods are therefore preferred.

Though arterial embolization may have some role in the management of these lesions, for example by improving cardiac manifestations or limiting blood loss during surgery, this is generally not curative and may in fact lead to a troublesome collateral supply. Embolization of the venous side of the fistula is said to offer the best chance of permanent cure, and once the venous side has been occluded the arterial supply will regress spontaneously [8]. Various routes can be chosen to reach the site of planned embolization, as demonstrated in a case report by Komiya et al., who used a transumbilical route to embolize a torcular DAVF in a neonate [6].

Conclusion

A paediatric posterior fossa DAVF is a rare lesion that requires careful analysis of the haemodynamic aspects of the fistula before occlusion of the lesion. Though combination treatment may be required in some cases, occlusion of the venous side of the fistula is an effective primary mode of treatment. Once the venous sack had been obliterated through an arterial route, our patient with presumed congenital pial–dural arteriovenous fistula achieved a radiological and clinical cure.

References

- Albright AL, Latchaw RE, Price RA (1983) Posterior dural arteriovenous malformations in infancy. *Neurosurgery* 13:129–135
- Awad IA, Little JR, Akrawi WP, Ahl J (1990) Intracranial dural arteriovenous malformations: factors predisposing to an aggressive neurological course. *J Neurosurg* 72:839–850
- Barnwell SL, Halbach VV, Higashida RT, Hieshima G, Wilson CB (1989) Complex dural arteriovenous fistulas. Results of combined endovascular and neurosurgical treatment in 16 patients. *J Neurosurg* 71:352–358
- Brown RD Jr, Wiebers DO, Nichols DA (1994) Intracranial dural arteriovenous fistulae: angiographic predictors of intracranial hemorrhage and clinical outcome in nonsurgical patients. *J Neurosurg* 81:531–538
- Hamilton MG, Herman JM, Khayata MH, Spetzler RF (1996) Aneurysms of the vein of Galen. In: Youmans JR (ed) *Neurological surgery*, 4th edn. Saunders, Philadelphia, pp 1491–1510
- Komiya M, Nishikawa M, Kitano S, Sakamoto H, Miyagi N, Kusuda S, Sugimoto H (1999) Transumbilical embolization of a congenital dural arteriovenous fistula at the torcular Herophili in a neonate. *J Neurosurg* 90:964–969
- Morita A, Meyer FB, Nichols DA, Patterson MC (1995) Childhood dural arteriovenous fistulae of the posterior dural sinuses: three case reports and literature review. *Neurosurgery* 37:1193–1200
- Mullan S (1994) Reflections upon the nature and management of intracranial and intraspinal vascular malformation and fistulae. *J Neurosurg* 80:606–616
- Newton TH, Cronqvist S (1969) Involvement of dural arteries in intracranial arteriovenous malformations. *Radiology* 93:1071–1078
- Ross DA, Walker J, Edwards MSB (1986) Unusual posterior fossa dural arteriovenous malformation in a neonate: case report. *Neurosurgery* 19:1021–1024