

Cortical blindness in cranial arteritis

I. H. CHISHOLM

From Moorfields Eye Hospital, City Road, London EC1V 2PD

Visual symptoms are reported in up to 65 per cent of patients suffering from cranial arteritis (Crompton, 1959; Meadows, 1966; Wagener and Hollenhorst, 1958). These include transient or permanent blindness, field defects, ophthalmoplegia (diplopia, ptosis) (Whitfield, Bateman, and Cooke, 1963), and formed visual hallucinations (Hart, 1967). Ischaemia is the underlying mechanism and may affect any part of the visual pathway although visual loss is usually caused by disease in the territory of the ophthalmic artery affecting the retinal or choroidal circulations.

Wilkinson and Russell (1972) found that the ophthalmic artery was involved in 76 per cent (13 out of 17) of the arteries examined in 12 necropsy studies. From this study it was also apparent that it was the ophthalmic and posterior ciliary arteries that were chiefly involved rather than the central retinal artery. The proximal part of this artery was more severely involved than the distal where it was buried in the substance of the optic nerve, and this appeared to correlate with the amount of elastic tissue in the vessel wall. This further supports the concept of the disease being an autoimmune reaction involving arterial elastic tissue.

In a case reported by Symonds and Mackenzie (1957) bilateral blindness was associated with normal pupil responses, a fact which allowed the mistaken diagnosis of hysteria to be made initially. The present case, the full pathology of which was presented by Wilkinson and Russell (1972), emphasizes the possibility of cortical blindness in this disease and its clinical recognition.

Case report

A previously active 79-year-old man presented in Casualty at Moorfields Eye Hospital with recent onset of visual and mental deterioration. He had been unsteady on his feet and generally unwell for about 2 weeks. His vision was perception of light in each eye but his pupil responses were normal with no afferent defect. The right fundus was normal but detailed examination of the left fundus was

impossible because of lens opacities. His erythrocyte sedimentation rate was 58 mm/hr. A visually evoked response using a computer of average transients (CAT Mnemotron) (Fig. 1) was performed at that time showing a flat response, and a presumptive diagnosis of cortical blindness caused by cranial arteritis was made and later confirmed by a positive temporal artery biopsy. The patient was admitted to the National Hospital, Queen Square, where, despite treatment, he died five days later.

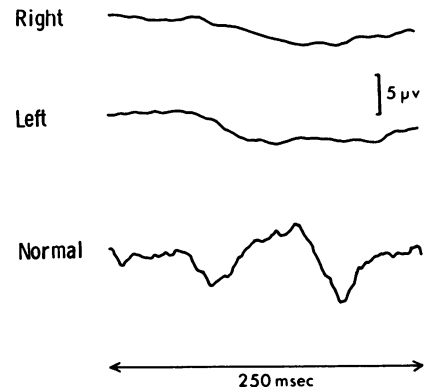


FIG. 1 *Tracing of visually evoked responses and a normal tracing for comparison (CAT Mnemotron)*

The necropsy findings were of thrombosis and arteritic involvement of both vertebral arteries with recent blood clot extending to the origin of the basilar artery. The terminal parts of the carotid arteries were healthy. Examination of both the right and left ophthalmic arteries showed some areas of arteriosclerosis but no evidence of arteritis in either the ophthalmic or ciliary arteries. Both cerebellar hemispheres showed infarction and softening. The right occipital lobe showed an old infarct involving the optic radiation while on the left there was more recent and extensive softening involving the upper and lower lips of the calcarine fissure extending to the posterior pole (Fig. 2). These necropsy findings failed to show any evidence of cranial arteritis in the territory of the ophthalmic artery and fully supported the clinical diagnosis of cortical blindness.

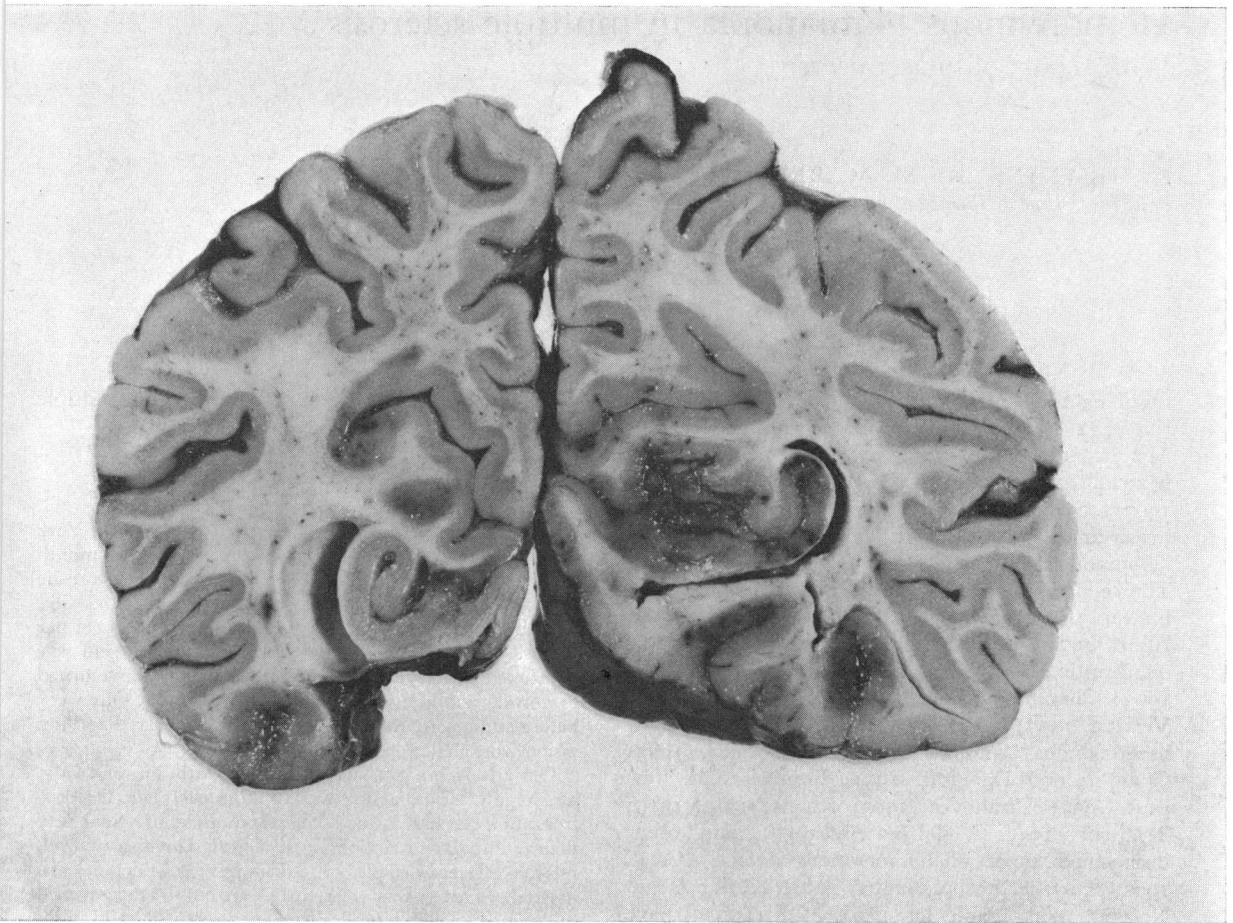


FIG. 2 Brain section to show old infarct in right optic radiation and more extensive and recent softening in region of left calcarine fissure (section looking posteriorly)

Summary

A case is presented of cortical blindness in cranial arteritis. A clinical diagnosis at the time of presentation was based on the integrity of the pupillary light reflex and the absence of visually evoked responses. Pathological examination confirmed bilateral occipital infarction. This report stresses the need for recog-

nizing this presentation of cranial arteritis and initiating immediate treatment.

I should like to thank Mr M. D. Sanders for his help in preparing this paper, and Mr P. Fells and Dr K. W. Ross Russell for permission to report on this patient. I am grateful to Professor Blackwood of the Department of Neuropathology, the National Hospital for Nervous Diseases, for the necropsy report and photograph.

References

- CROMPTON, M. R. (1959) *Brain*, **82**, 377
 HART, C. T. (1967) *Brit. med. J.*, **3**, 643
 MEADOWS, S. P. (1966) *Proc. roy. Soc. Med.*, **59**, 329
 SYMONDS, C., and MACKENZIE, I. (1957) *Brain*, **80**, 415
 WAGENER, H. P., and HOLLENHORST, R. W. (1958) *Amer. J. Ophthalm.*, **45**, 617
 WHITFIELD, A. G. W., BATEMAN, M., and COOKE, W. T. (1963) *Brit. J. Ophthalm.*, **47**, 555
 WILKINSON, I. M. S., and RUSSELL, R. W. ROSS (1972) *Arch. Neurol. (Chicago)*, **27**, 378