

CONCLUSION

Trans-sphenoidal encephaloceles are rare entities and trans-sellar variety is rarest among these. We present one case of a male infant with trans-sellar trans-sphenoidal rhino-oral encephalocele and another case of an adolescent boy with a trans-sellar trans-sphenoidal rhinal encephalocele. Both patients were symptomatic and had associated anomalies. The first case had a cleft palate and the second case had cleft lip and hypertelorism.

The diagnosis of these conditions has become relatively straightforward with the availability of imaging modalities, like CT scanning, MRI imaging and DSA studies. Ideal surgical approaches are still not clear due to the lack of adequate experience in the literature. We had performed trans-basal approaches and were satisfied with surgical techniques but in our first case the CSF leak resulting in fulminant meningitis was fatal. Management of these cases is a real challenge and must be meticulously planned on a case to case basis. A generalised approach may not be wise or appropriate in these cases.

ACKNOWLEDGEMENT

We sincerely thank Dr Paul, maxillofacial & dental surgeon, for the guidance and assistance in the management of case 2.

REFERENCES

1. Abiko S, Aoki H, Fudaba H. Trans sphenoidal encephaloceles-report of a case. *Neurosurgery* 1988; 27: 933-936.
2. Tsutsumi K, Asano T, Shigeno T, Matsui T, Ito S, Kaizulf. Transcranial approach for trans sphenoidal encephalocele: Report of two cases. *Surg Neurol* 1999; 51: 252-257.
3. Wiese GM, Kempe LG, Hammon WM. Trans sphenoidal meningoencephalocele: Case report. *J Neurosurg* 1972; 37: 475-478.
4. Kobayashi S, Miyazaki M, Miyagi O, Yodouaka M, Shimiza S. A case report of trans sphenoidal meningoencephalocele. *Neurol Surg* 1990; 18: 1671-1677 (In Japanese).
5. Itakura T, Miyamoto K, Uekatsa Y, Hayashi S, Kolval N. Bilateral morning glory syndrome associated with sphenoidal encephalocele. *J Neurosurg* 1992; 77: 949-951.
6. Ingraham FD, Matson DD. Spina bifida and cranium bifidum IV. An unusual nasopharyngeal encephalocele. *New Eng J Med* 1943; 228: 815-820.
7. Avazimi G, Crivelli G. A case of sphenopharyngeal encephalocele. *Acta Neurochir* 1970; 22: 205-212.
8. Ellyin F, Khatir AH, Sinyan SP. Hypothalamic-pituitary functions in patients with trans sphenoidal encephaloceles and midfacial anomalies. *J Clin Endocrinol Metab* 1980; 51: 854-856.
9. Shirataki K, Sakamoto K, Ohata Y. Diagnosis and treatment of trans sphenoidal encephalocele. Report of a case with review of the literature. *Brain Nerve* 1976; 28: 281-291 (In Japanese).
10. Takezawa N, Sato M, Yanagisawa T, Shimizu N. Pituitary dwarfism associated with morning glory syndrome and trans sphenoidal encephalocele - a case report. *No To Hittatsu* 1987; 19: 492-496 (In Japanese).
11. Lewin ML. Sphenothmoidal encephalocele with cleft palate: transpalatal versus transcranial repair. Report of two cases. *J Neurosurg* 1983; 58: 924-931.
12. Pollock JA, Newton TH, Hoyt WF. Trans sphenoidal encephalocele. *Radiology* 1968; 90: 442-453.
13. Modesti LM, Glasaaer FE, Terplan KL. Sphenothmoidal encephalocele. A case report and review of the literature. *Child's Brain* 1977; 3: 140-153.
14. Yakota A, Matsukado Y, Fuwa I, Motoki K, Nagahira S. Anterior basal encephalocele of the neonatal and infantile period. *Neurosurgery* 1986; 19: 468-478.
15. Sakoda K, Liozumi T, Nishi Y. Basal meningoencephalocele. Proceedings of Japanese Congress of Neurological Surgeons, Tokyo, 1983 (In Japanese): 41-52.
16. Bruce DA. Anterior basal encephalocele of the neonatal and infantile period. *Neurosurgery* 1986; 19: 477-478.
17. Mahapatra AK. Anterior encephaloceles - a study of 65 cases. *Ind J Pediatr* 1997; 64: 699-704.
18. Monka M, Marubayashi T, Masamitsu T. Basal encephaloceles with morning glory syndrome and progressive hormonal and visual disturbances. Case report and review of the literature. *Brain Dev* 1995; 17: 196-201.

Spinal epidural haematoma: MRI-aided diagnosis

Wai Hoe Ng¹ MBBS, C. C. Tchoyoson Lim² FRCR, Puay Yong Ng¹ FRACS, Kheng Kooi Tan¹ FRCS

¹Department of Neurosurgery ²Department of Neuroradiology, National Neuroscience Institute, Singapore

Summary Spinal epidural haematoma is a rare cause of spinal cord compression. It is most commonly attributed to trauma and coagulation disorders. We report a case of a 64 year-old man with thrombocytopaenia who presented with a traumatic epidural haematoma who presented with right hemiparesis which progressed to complete tetraplegia. MR of the cervical spine showed an epidural collection on the posterior aspect of the cord throughout the cervical spine. The patient underwent C1-C7 laminectomy and decompression. Postoperatively, the patient has improved gradually and has power of grade 3 (Medical Research Council classification of power) in all 4 limbs at 2-month follow-up. MRI is an important modality in the early diagnosis of spinal epidural haematomas and can facilitate emergent decompressive surgery which offers the best chance of neurological improvement. © 2002 Harcourt Publishers Ltd

Journal of Clinical Neuroscience (2002) 9(1), 92-94 © 2002 Harcourt Publishers Ltd

DOI: 10.1054/jocn.2000.0918, available online at <http://www.idealibrary.com> on **IDEAL**[®]

Keywords: epidural haematoma, spinal cord compression, magnetic resonance imaging, spinal trauma

Received 27 June 2000

Accepted 27 October 2000

Correspondence to: Dr Wai Hoe Ng, Department of Neurosurgery, National Neuroscience Institute, Singapore, 11 Jalan Tan Tock Seng, Singapore 308433. Tel.: +65 357 7153; Fax: +65 256 4755.

INTRODUCTION

Spinal epidural haematoma is a rare condition which can present with acute spinal cord compression. Jackson first described a spontaneous case in 1869.¹ Its description in the literature has mainly been confined to anecdotal reports or a small series of cases. Causation factors are related to trauma, anticoagulant therapy, blood dyscrasias, vascular malformations, epidural anaesthesia, surgery or lumbar puncture. There are also reported cases associated with cervical spondylosis and systemic lupus erythematosus. MR imaging can quite accurately characterize epidural haematomas and hence aid in early diagnosis and institution of definitive treatment.

CASE REPORT

A 64 year-old man presented with a history of assault. Post-injury, he was fully ambulant and had no neurological deficit. The next day, he sustained a fall at home and subsequently presented to the hospital with complaints of right-sided neck pain and right hemiparesis. On admission, there was evidence of right hemiparesis (power grade 2) and the bladder was distended.

Approximately 8 h later, he developed left hemiparesis (power grade 2) and this rapidly progressed to complete tetraplegia 10 h later.

High dose intravenous methylprednisolone was commenced. The patient was however noted to have thrombocytopenia with a platelet count of 62×10^9 – this was attributed to be secondary to alcoholic liver cirrhosis. The clotting profile was normal and plain radiographs of the cervical spine revealed no fracture.

An urgent MRI of the cervical spine revealed an epidural collection compressing the posterior aspect of the cord throughout the cervical spinal. On T2-weighted images, the linear low signal representing the dura mater clearly delimited this collection at its superior extent from the bright signal of the CSF (Fig. 1).

The signal intensity of the blood collection was slightly increased in both T1 and T2 compared to muscle, with collections of susceptibility at its inferior extent (Figs 1, 2 & 3). The prevertebral soft tissue exhibited generalized T2 prolongation, and the patient had evidence of a background of degenerative osteophytic disc disease.

The platelet level was optimized and the patient subsequently underwent C1–C7 cervical laminectomy. In the immediate post-operative period, the motor strength in the left upper limb and right upper limb improved to grade 3 and grade 1 respectively. The post-surgical course was complicated by hypotension, atrial fibrillation, respiratory failure and sepsis. These were reversed by aggressive medical therapy. At 2-month follow-up, the patient has regained some neurological function with power of grade 3 in all 4 limbs.

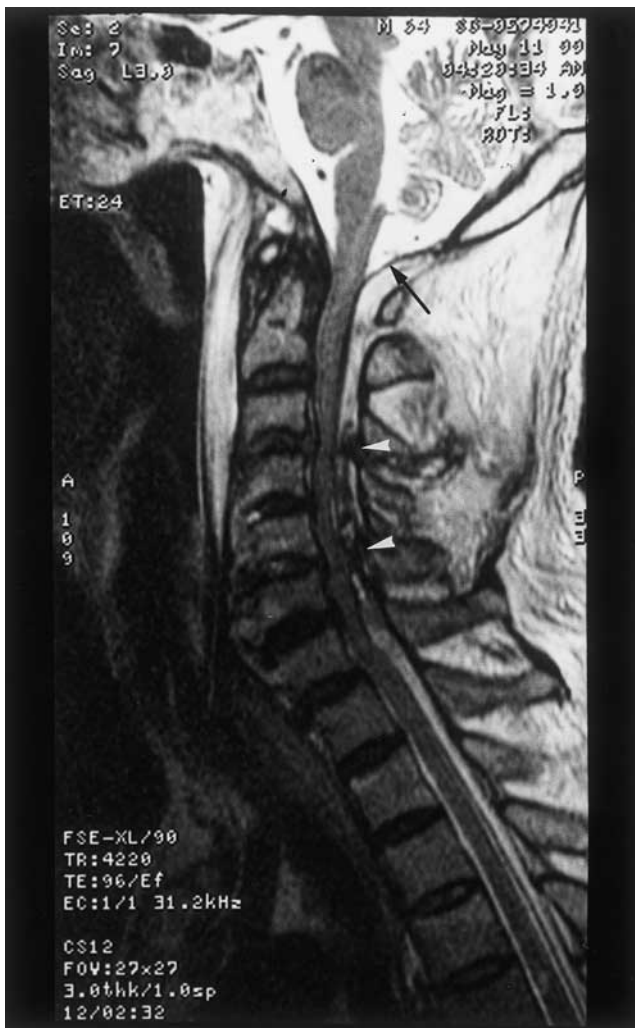

Fig. 1 Fast spin-echo (FSE) T2-weighted repetition time (TR) msec/echo time (TE) msec, 4220/96 image shows an epidural fluid collection posterior to the spinal cord. The signal intensity is higher than muscle but lower than CSF, with a few collections of very low signal (arrowheads) from magnetic susceptibility within. The low intensity dura (arrow) is clearly seen.

DISCUSSION

Spinal epidural haematoma is a rare condition. Its true incidence is not known and there is no sexual predilection. Controversy exists

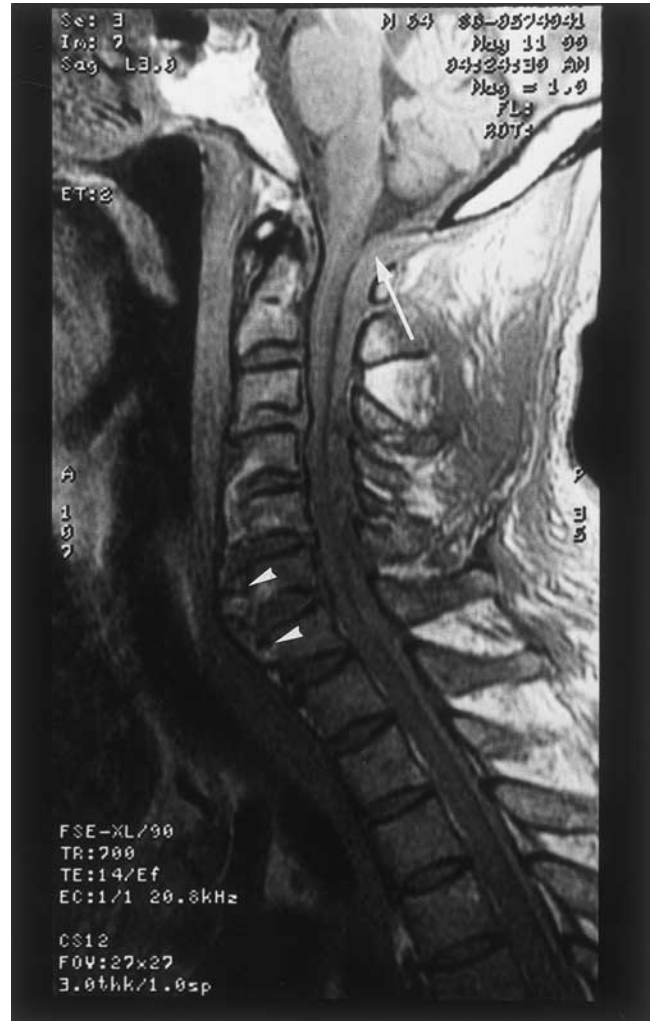

Fig. 2 On T1-weighted (700/14) image, the epidural collection (arrow) is increased in signal compared to muscle. There is also evidence of degenerative spondylosis (arrowheads).

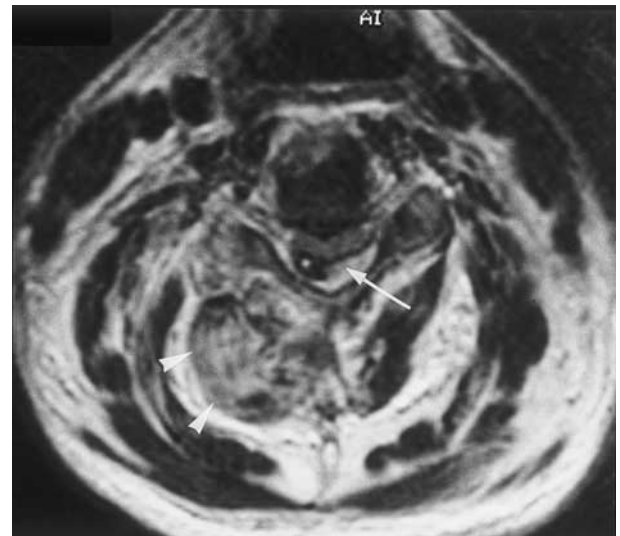


Fig. 3 This axial FSE T2-weighted (5040/84) image at C4-5 level shows an area of decreased signal in the haematoma with a focus of increased signal within (arrow). Note the swollen, prolonged T2 of the traumatized muscles on the right (arrowheads).

regarding the pathogenesis of spontaneous epidural haematoma and there is no agreement as to whether the bleeding is of arterial or venous origin.² There exists a rich venous plexus in the epidural space and it is postulated that there is increased blood flow into the valveless epidural veins during straining.³ As such, it is believed that the epidural veins are the likely source of haemorrhage; their valveless nature also predisposes them to bleeding with minor trauma. With an associated fracture of the vertebra, cancellous bone bleeding would be an obvious source of haemorrhage.

The causative agent may be anti-coagulant treatment, blood dyscrasias, vascular malformations, epidural anaesthesia,⁴ lumbar puncture and surgery. There has also been reports of spontaneous epidural haematomas occurring in patients with cervical spondylosis⁵ and systemic lupus erythematosus.⁶ The aetiological agent is unknown in many cases.

Most cases reported in the literature have a history of anticoagulant therapy or platelet disorder; this was also the case in our patient who had thrombocytopenia secondary to alcoholic liver cirrhosis.

Spinal epidural haematomas may present with back pain, radiculopathy, weakness or spinal cord compression. In rare cases, there may be a course of repeated spontaneous recovery and relapse.⁷ There is however no distinctive clinical sign pathognomonic for epidural haematoma.

Johnston⁸ believes that modern radiological imaging modalities can overcome the shortfalls in clinical examination in the management of acute spinal cord compression. Since the introduction of MRI, the mean incidence of acute spontaneous spinal epidural haematoma reported in the literature has increased from 2.2 to 6.4 new cases per year.⁹ Indeed MRI can be considered as the imaging modality of choice.

Sagittal MRI typically shows biconvex haematoma in the posterior epidural space with well-defined borders tapering superiorly and inferiorly. Axial sections would show a concave or convex mass. The dura mater separates the haematoma from the spinal cord on T1 and T2-weighted images. Boukobza et al.¹⁰ reviewed the MRI characteristics of 11 cases of spinal epidural haematomas and found that within 24 h of onset, the epidural haematoma is usually isointense on T1-weighted images. Occasionally, there is a mildly or markedly increased signal. On T2-weighted images, there may be a homogenous high signal or inhomogenous areas of mixed high and low signal. After 24 h, there is usually a high signal on T1-weighted images; T2-weighted images in most cases give the same signal as CSF. Important differential diagnosis to exclude are subdural haematoma, epidural metastasis and epidural abscess.

Management

Prompt surgical evacuation is the treatment of choice in spinal epidural haematomas. Rapid diagnosis and emergent surgical treatment maximises neurological recovery. Lawton et al.¹¹ showed that patients who underwent decompression within 12 h had better neurological outcomes than patients with identical Frankel grades (Table 1) whose decompression was delayed beyond 12 h. Groen et al.¹² reviewed 330 cases of spontaneous spinal epidural haematomas. They conclude that incomplete pre-operative sensorimotor deficit and early surgery (within 36 h) were correlated with better outcome. Mortality was higher in patients with cervical or cervicothoracic haematomas, especially in patients with cardiovascular disease and those on anti-coagulant therapy.

There have been reported cases of spontaneous resolution of spinal epidural haematomas with good neurological recovery.^{13,14} It is postulated that this occurs from the spreading of the haematoma in the epidural space upwards and downwards resulting in decompression. Some authors have proposed conservative

Table 1 Frankel grading

Grade A: complete loss of motor and sensory function below a given level
Grade B: some preservation of sensation; complete motor function paralysis
Grade C: sensory function useless; some motor function preserved, but insufficient to be useful
Grade D: sensory function useful; weak but useful motor function
Grade E: neurologically intact

management by lumbar punctures.¹⁵ However, prompt surgical evacuation should remain the treatment of choice except in cases where operative morbidity and mortality is high and in cases with no neurological deficit. We also consider that the risk of injury to blood vessels and nerve roots during lumbar puncture can be high and the likelihood of adequate decompression is low.

REFERENCES

1. Jackson R. Case of spinal apoplexy. *Lancet* 1896; 2: 5–6.
2. Groen RJM, Ponsen H. Vascular anatomy of the spinal epidural space: considerations on the etiology of spontaneous epidural hematoma. *Clin Anat* 1991; 4: 413–429.
3. Bruyn GW, Bosma NJ. Spinal extradural haematoma. In: Vinken PJ, Bruyn GW, eds. *Handbook of clinical neurology*. Vol. 13 Amsterdam: Elsevier, 1976: 1–30.
4. Gingrich TF. Spinal epidural hematoma following epidural anesthesia. *Anesthesiology* 1968; 29: 162–163.
5. Sannoh N, Kubokura T, Nishimura T, Koyama S, Tsubone K. A case of spontaneous cervical hematoma associated with cervical spondylosis. *NO Chinkei Geka* 1988; 16(Suppl 5): 539–543.
6. Satoh S, Hirakata M, Kameda H, Hama N, Yoshida T, Mimori T, Akizuki M, Ikeda Y. A case of systemic lupus erythematosus associated with spinal epidural hematoma. *Nihon Rinsho Meneki Gakka Kaishi* 1998; 21(4): 166–171.
7. Chen CJ, Fang W, Chen CM, Wan YL. Spontaneous spinal epidural haematomas with repeated remission and relapse. *Neuroradiology* 1997; 39(10): 737–740.
8. Johnston RA. The management of acute spinal cord compression. *J Neurol Neurosurg Psychiatry* 1993; 56:1046–1054.
9. Jamjoom ZA. Acute spontaneous spinal epidural hematoma: the influence of magnetic resonance imaging on diagnosis and treatment. *Surg Neurol* 1996; 46(4): 345–349.
10. Boukobza M, Guichard JP, Boissonet M, George B, Reizine D, Gelbert F, Meland JJ. Spinal epidural haematoma: report of 11 cases and review of the literature. *Neuroradiology* 1994; 36: 456–459.
11. Lawton MT, Porter RW, Heiserman JE, Jacobowitz R, Sonntag VK, Dickman CA. Surgical management of spinal epidural hematoma: relationship between surgical timing and neurological outcome. *J Neurosurg* 1995; 83(1): 1–7.
12. Groen RJ, van Alphen HA. Operative treatment of spontaneous spinal epidural hematomas: a study of factors determining postoperative outcome. *Neurosurgery* 1996; 39(3): 494–508.
13. Wagner S, Forsting M, Hacke W. Spontaneous resolution of a large spinal epidural hematoma: case report. *Neurosurgery* 1996; 38(4): 816–818.
14. Giovanni La Rosa, Domenico D'Avella, Alfredo Conti, Salvatore Cardeli, Domenico La Torre, Fabio Cacciola, Marcello Longo, Francesco Tomasello. Magnetic resonance imaging-monitored conservative management of traumatic epidural hematomas. *J Neurosurg (Spine 1)* 1999; 91: 128–132.
15. Lee JI, Hong SC, Shin HJ, Eoh W, Byun HS, Kim JH. Traumatic spinal subdural hematoma: rapid resolution after repeated lumbar spinal puncture and drainage. *J Trauma* 1996; 40(4): 654–655.

An unusual case of paroxysmal kinesigenic dyskinesia

Reji Thomas¹ MD, M. Behari¹ MD DM, S.B. Gaikwad² MD, K. Prasad¹ MD DM

¹Departments of Neurology and ²Neuro Radiology, All India Institute of Medical Sciences, New Delhi-110 029, India