

The many faces of crossed aphasia in dextrals: report of nine cases and review of the literature

P. Mariën^a, S. Engelborghs^a, L. A. Vignolo^b and P. P. De Deyn^a

^aDepartment of Neurology, General Hospital Middelheim, Antwerp, Belgium and Laboratory of Neurochemistry and Behaviour, Born-Bunge Foundation, University of Antwerp, Belgium; and ^bDepartment of Neurology, Clinica Neurologica della Università, Spedali Civili, Brescia, Italy

Keywords:

crossed aphasia,
neurolinguistics,
neuropsychology,
review

Received 20 April 2001

Accepted 25 July 2001

A substantial body of the aphasia literature has been devoted to the topic of crossed aphasia in dextrals (CAD) over the past century but still no theory exists that explains the anomalous organization of neurocognitive functions in this population. However, if strict selection criteria are applied only some cases of vascular CAD are reported in which the correlation between neurocognitive disturbances and the locus of the brain lesion is studied. This study describes nine new cases of vascular CAD who underwent in-depth neurolinguistic and neuropsychological investigations. Our analysis shows the semiological variability of CAD phenomena and the many faces of the lesion-behaviour relationships of this exceptional neurobiological condition.

Introduction

Crossed aphasia in dextrals (CAD) – i.e. aphasia following a right hemisphere lesion in right-handers – is rare. Notwithstanding its low incidence, which is variably estimated between 0.38 and 3% (Hécaen *et al.*, 1971; Carr *et al.*, 1981) in patients with vascular lesions, more than 200 CAD patients have been reported since the initial description of the concept by Byrom Bramwell in 1899. Although many issues remain unsettled, continuous attention for CAD has led to a substantial increase of insights in the neurobiological mechanisms underlying the functional neurocognitive organization of the brain.

One of the most influential and widely held views on CAD of the last decades was advanced by Brown and coworkers in the 1970s (Brown and Wilson, 1973; Brown, 1976; Brown and Hécaen, 1976). In accord with the classical concept of acquired childhood aphasia and aphasia in sinistrals they defined CAD as prototypically non-fluent and often transient regardless of the lesion site (Mariën *et al.*, 2001b,c). Many subsequent studies added evidence to this view supporting the concept of more diffuse language representation as the consequence of a disrupted lateralization process (e.g. Urbain *et al.*, 1978; Barroche *et al.*, 1979; Goldstein *et al.*, 1979; Pillon *et al.*, 1979; Taylor and Salomon, 1979; Donoso *et al.*, 1980; Barroche *et al.*, 1981; Delreux *et al.*, 1989). Since the advent of advanced neuro-imaging techniques the validity of this view has been challenged. From the 1980s onwards studies have

documented in CAD similar aphasia types, lesion-behaviour relationships and recovery patterns as in uncrossed aphasia (UCA) (e.g. Carr *et al.*, 1981; Yarnell, 1981; Joannette *et al.*, 1982; Henderson, 1983; Castro-Caldas and Confraria, 1984; Sweet *et al.*, 1984; Alexander *et al.*, 1989). However, in comparison with UCA the number of CAD cases that violate classically expected lesion-behaviour relationships is disproportionately high. In this respect, review studies show that < 13% of the cases of UCA display anomalous lesion-behaviour correlates (Basso *et al.*, 1985). This proportion increases to 35% in CAD (Alexander *et al.*, 1989; Coppens and Hungerford, 1998).

This study reports nine CAD patients who developed aphasia after a vascular lesion of the right hemisphere. Detailed clinical and neurocognitive data are reported. The cases presented underscore the variability of neurocognitive symptoms in CAD and show that lesion-behaviour relationships even extend beyond the clear-cut distinction of the mirror-image versus anomalous dichotomy.

Subjects and methods

During the past 10 years 19 right-handed patients with aphasia following a right hemisphere lesion have been examined in the neurolinguistic department of A. Z. Middelheim. Nine of these patients fulfilling the following criteria were selected for the present study: (i) clear-cut evidence of aphasia, (ii) aphasia producing lesion in the right hemisphere ascertained by computerized tomography (CT), Magnetic Resonance Imaging (MRI) or post-mortem examination, (iii) vascular etiology, (iv) absence of early brain damage or a history of seizures in early childhood, (v) absence of familial

Correspondence: Peter Mariën, A. Z. Middelheim, Department of Neurology, Lindendreef 1, B-2020 Antwerp, Belgium (fax: +32-3-281-37-48; e-mail: petermarien@skynet.be).

sinistrality. Nine of the 19 cases were excluded for the following reasons: non-vascular aetiology (five cases), familial sinistrality (one case), additional vascular damage to the language areas of the left hemisphere (two cases), incomplete record lacking information on familial left-handedness, early brain damage and developmental milestones (one case). One case represents CAD in acquired childhood aphasia and was extensively reported previously (Mariën *et al.*, 2001a; Mariën *et al.*, 2001b,c). All cases withheld for the present study are adults. Six patients are men, three are women.

In agreement with a three epoch time-frame for models of aphasia (Mazzocchi and Vignolo, 1979; Basso *et al.*, 1985; Alexander, 1989) most patients were examined at several periods post-onset. To avoid remote functional effects of the lesion, generally accounting for the instability of the aphasic profile during the first 2 or 3 weeks post-onset (acute phase), formal language assessments were especially performed in the lesion phase. This phase (which might last up to 4 months) offers a reliable basis for anatomoclinical correlations (Mazzocchi and Vignolo, 1979; Alexander, 1989). To capture various effects of recovery and functional brain reorganization, some patients ($n = 3$) could also be examined in the late phase, commencing around 4 months after onset of the neurological symptoms.

The neurolinguistic test battery consisted of a selection of tests including the Dutch version of the Aachener Aphasia Test (AAT) (Graetz *et al.*, 1992), the Boston Diagnostic Aphasia Examination (BDAE) (Goodglass and Kaplan, 1983), the Token Test (De Renzi and Vignolo, 1962), the Boston Naming Test (BNT) (Kaplan *et al.*, 1983; Mariën *et al.*, 1998), a phonological and semantic verbal fluency task (unpublished tests) and subtests of the Dutch version of the Psycholinguistic Assessments of Language Processing in Aphasia (PALPA) (Bastiaanse *et al.*, 1995).

Neuropsychological investigations were based on a selection of standardized tests. This consisted of: the Mini Mental State Examination (MMSE) (Folstein *et al.*, 1975), the Alzheimer's Disease Assessment Scale (ADAS) (Rosen *et al.*, 1984), the Coloured Progressive Matrices (Raven, 1976), the Wechsler Adult Intelligence Scale (WAIS) (Stinissen *et al.*, 1970), the Hierarchic Dementia Scale (HDS) (Cole and Dastoor, 1987), the Wechsler Memory Scales (WMS and WMS-R) (Wechsler, 1945, 1984), Rey's 15 words, the Rey-Osterrieth figure, the Wisconsin Card Sorting Test (Grant and Berg, 1993), the Stroop Colour-Word Test (Lezak, 1983), the Right-Left Orientation test, the Visual Form Discrimination test and the Judgment of Line Orientation test (JLO) (Benton *et al.*, 1983). Handedness was formally assessed with the Edinburgh Inventory (EI) (Oldfield, 1971).

Case summaries

Table 1 displays a summary of demographic data, neurolinguistic findings, lesion site and etiology. Table 2 displays a summary of neuropsychological findings.

Case 1

History

A 55-year-old trans-sexual man developed speech problems and paresis of the left hemicorpus. On admission he was well-oriented, alert and co-operative. Neurological examination revealed expressive aphasia, moderate left hemiparesis and central facial nerve palsy. The left plantar response was extensor. Sensory examination disclosed left hypoesthesia. On confrontation no visual field defects or spatial neglect phenomena were encountered. Besides a trans-sexual operation, carried out 3 years before this admission, medical history was unremarkable. The patient worked as a technician and had an education level of 13 years. For 10 of 10 unimanual tasks a strong and consistent right hand preference was indicated and later confirmed by means of the EI which yielded a Laterality Quotient (LQ) of +90. Family history of left-handedness or ambidexterity was negative. Both parents, siblings and the grandparents were dextrals.

On admission CT scan of the brain did not reveal abnormalities. Seven days post-onset a repeat CT scan of the brain showed extensive infarction in the right parietal region. MRI of the brain (Fig. 1A) performed 5 months after stroke confirmed the CT findings and ruled out left hemisphere involvement.

After 2 years the neurological condition had improved to a discrete residual left hemiparesis. Neuropsychological and neurolinguistic examinations were performed 6 days, 3, 12 and 24 months after stroke.

Neurolinguistic and neuropsychological findings

Following extensive infarction in the right parietal lobe, this patient developed persistent non-fluent aphasia. In the acute phase, neurolinguistic investigations revealed a dissociation between nearly intact receptive and markedly disturbed expressive language functions. Auditory-verbal and written language comprehension were only disturbed for syntactically complex language. In speech as well as in oral reading phonological disturbances were found. Agrammatism in speech, writing and oral reading was reflected by telegraphic style, omission of determinators, deletion of pronomina, deletion of flexional morphemes and derivational errors. The neurolinguistic profile, strongly resembling crossed Broca aphasia with

Table 1 Case summaries: aphasic symptoms, lesion site and cause

Case	Age/gender	Time post onset	Aphasia symptoms							Lesion site	Cause
			Fluency	Compreh.	Repetition	Naming	Reading	Writing	Aphasia typology		
1	55/M	Day 6	+++	+	++	+	++	++	++	Parietal	Infarction
		Month 3	+		++		+	++	Broca aphasia, agrammatism		
		Month 12/24	+		++			++	Severe Broca aphasia		
2	63/M	Acute phase		+++	+++	+++	+++	+++	+++	Temporo-parietal	Haemorrhage (AVM)
		Week 7		+++	+++	+++	+++	+++	Severe Wernicke aphasia		
		Week 16		+++	+++	+++	+++	+++	Severe Wernicke aphasia		
3	75/F	Admission	++	+	+	++	+	+	Minor non-fluent aphasia	Putamen, globus pallidus, parietal PVWM	Infarction
		Day 26	+++	+	++		++	++	Dynamic aphasia		
		Month 18	+++	+	++			+	Dynamic aphasia		
4	79/F	Day 1	+++		+++	+++	+++	+++	Mutism	Caudate nucleus, corona radiata, external capsule, putamen, globus pallidus of the lentiform nucleus	Infarction
		Day 2	+++	++	++	++	++	++	Global aphasia		
		Day 3	+++	+++	+++	+++	+++	+++	Global aphasia		
5	38/M	Day 9			++		+	+	Conduction aphasia	Temporal	Infarction
		Day 44			++				Conduction aphasia		
		Day 15	++	+	++	+	++	++	Severe Broca aphasia	Fronto-temporo-parietal	Infarction
6	61/M	Day 31	++	+	++	+	++	++	Broca aphasia		
		Day 1	++	++	++	++	++	++	Neologistic jargon aphasia	Temporo-parietal	Haemorrhage
		Day 31	++	++	++	++	++	++	Neologistic jargon aphasia		
8	62/M	Day 18	++	++	++	++	++	++	Severe Broca aphasia	Fronto-temporo-parietal	Infarction
		Month 3	++	+	+	+	+	+	Broca aphasia, speech apraxia		
		Month 18	++	+	+	+	+	+	Broca aphasia, speech apraxia		
9	73/M	Day 6	+	+	++	++	++	++	Conduction aphasia	Temporo-parietal	Infarction
		Day 32	+	+	++	++	++	++	Conduction aphasia		
		Day 32	+	+	++	++	++	++	Conduction aphasia		

Compreh.: comprehension; M: male; F: female; PVWM: periventricular white matter; +++: severely disturbed; ++: moderately disturbed; +: mildly disturbed; not disturbed (blank); AVM: arteriovenous malformation.

Table 2 Case summaries: neurocognitive symptoms

Case	Age/ gender	Time post onset	Dysprosodia	Visual neglect	Construct. apr.	Ideomotor apr.	Ideational apr.	Oral apr.	Anosognosia	Acalculia	Additional disturbances	Lesion site & etiology
1	55/M	Day 7 Month 5	+	-	-	-	-	-	+	+	Right/left disorientation None	Parietal infarction
2	63/M	Week 7	-	+	+	-	-	-	+	?	Left motor, tactile & auditory neglect	Temporo-parietal haemorrhage
3	75/F	Week 16 Day 27	-	+	-	-	-	-	+	?	?	Infarction: putamen, globus pallidus, & parietal PVWM
5	38/M	Month 18 Day 9	+	+	+	-	-	-	-	?	None	Temporal infarction
6	61/M	Day 44	-	-	+	-	-	-	-	-	Discrepancy verbal > non-verbal; frontal dysfunctions	Temporo-temporo- parietal infarction
7	86/F	Day 32 Day 31	+	-	+	-	-	-	-	-	Discrepancy verbal > non-verbal Memory disturbances	Temporo-temporo- parietal infarction
8	62/M	Month 3	+	+	+	-	-	+	+	+	?	Fronto-parietal Haemorrhage
9	64/F	Day 32	-	-	+	-	-	-	-	+	Memory; VIQ & PIQ Finger agnosia	Fronto-temporo- parietal infarction Temporo-parietal infarction

Construct.: constructional; apr.: apraxia; M: male; F: female; PVWM: periventricular white matter; +: present; -: absent; ?: no information.

receptive and expressive agrammatism, was further characterized by phonological jargonagraphia and phonological alexia.

Three months after stroke receptive agrammatism receded, speaking rate normalized, phonematic paraphasias decreased, letter reading normalized and word reading improved. The phonological jargon agraphia had evolved to phonological agraphia. Notwithstanding further improvement, residual agrammatism with phonematic distortions persisted in oral as well as written language. After month 9, the agraphic symptoms did not further improve.

As no finger agnosia was found, neuropsychological investigations only disclosed an incomplete Gerstmann's syndrome (acute phase) from which the patient rapidly recovered. Aside from these focal dysfunctions no additional neurocognitive deficits were found.

Case 2

History

A 63-year-old man was admitted to hospital when found on the street not being able to stand or making himself verbally clear. On admission the patient was alert and co-operative, responded verbally very inconsistently to simple oral commands and produced well-articulated jargon. He was unable to repeat, read or write. Neurological examination further revealed a left hemiparesis. Sensory examination disclosed left hypoaesthesia and allesthesia. On confrontation left hemianopia and spatial neglect were found. A CT scan of the brain showed a large haemorrhage of approximately 4 cm diameter in the right temporo-parietal region associated with a midline shift to the left (Fig. 1B).

Within the next 2 days the patient's neurological condition progressively worsened. A repeat CT scan of the brain showed marked increase of the intraparenchymal blood collection, increased midline shift and intraventricular blood. A panarteriography of the cerebral vessels disclosed an arteriovenous (AV) malformation in the right posterior parietal region. He was operated and the AV malformation was coagulated. Information about familial handedness, medical history and schooling was hetero-anamnestically obtained from the patient's near relatives (ex-wife and younger brother). He had 10 years of schooling and was trained as a bricklayer. He had not had early developmental or scholastic problems. At age 55 he broke up with his family and relatives and became homeless. His parents, both his siblings and his two children were strong dextrals. Apart from alcohol abuse, medical antecedents were negative.

Seven weeks after stroke onset, the patient was referred to our department. Neurocognitive investigations were performed at week 7 and 16.

Neurolinguistic and neuropsychological findings

Neurolinguistic investigations showed severe and persistent crossed Wernicke's aphasia with auditory-verbal agnosia, jargonagraphia and jargonalexia. The condition did not improve during 2 months of follow-up. Auditory-verbal agnosia and severe semantic jargon persisted in oral-verbal language. Written language remained disturbed by perseverative jargon. Although severely limited by the aphasic disturbances, neuropsychological assessments revealed multimodal hemineglect, severe constructional apraxia and anosognosia for neurocognitive and motor dysfunctions.

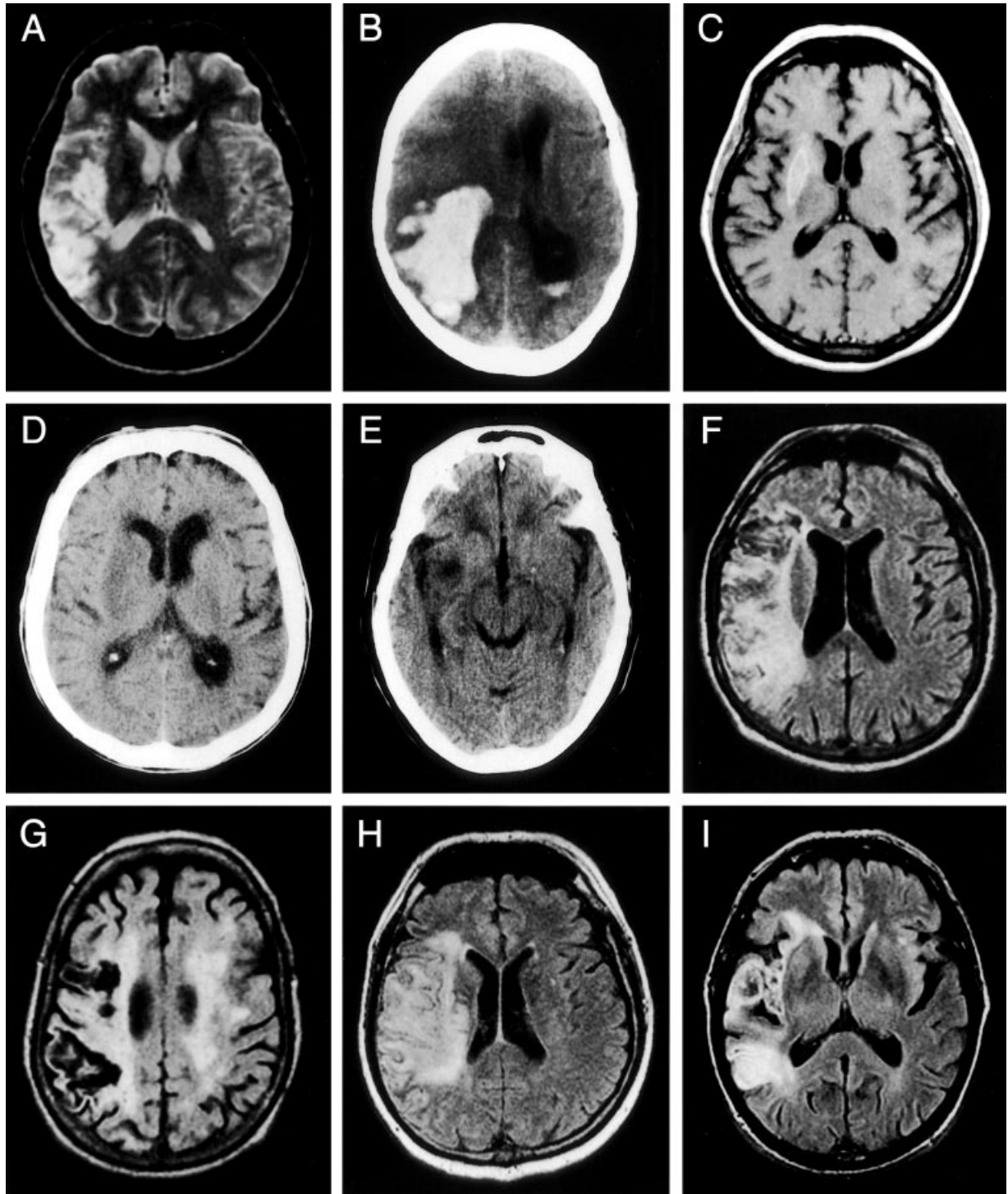
Case 3

History

A 75-year-old woman was admitted to hospital after sudden onset of expressive language disturbances. She was strongly right-handed by self-report and, as later assessed by the EI, obtained an LQ of +100. There was no family history of left-handedness or ambidexterity. On admission, she was alert and co-operative. The neurological examination revealed non-fluent aphasia characterized by reduced verbal output, word-finding disturbances and phonemic paraphasias in both oral and written language. CT scan of the brain on admission was negative. On day 6 of admission the neurological condition abruptly deteriorated. Within a few hours the patient became mute and stuporous. A score of eight was found on the Glasgow Coma Scale. There was left hemiplegia with left-sided hyperreflexia and central facial nerve palsy. Co-ordination and sensation could not be tested. Repeat CT and MRI of the brain disclosed a vascular lesion involving the crus anterior of the internal capsule, the globus pallidus, the putamen, the external capsule, the claustrum and the paraventricular white matter of the right parietal lobe (Fig. 1C). Eight days later the patient regained consciousness. Pyramidal symptoms persisted. Severe non-fluent aphasia and paralytic dysarthria disrupted communication. Echo doppler-examination of the carotid arteries disclosed occlusion of the right internal carotid artery. Eighteen months after stroke the neurological examination still showed a severe left sensory-motor syndrome. Neurocognitive investigations were performed at day 27 and repeated 18 months post-stroke.

Neurolinguistic and neuropsychological findings

At onset, this patient presented mild non-fluent aphasia. After consistent improvement during the early



acute phase, the neurological condition acutely deteriorated and induced permanent non-fluent aphasia. Auditory-verbal and reading comprehension were mildly impaired. Marked adynamia, word-finding problems, phonematic errors, reduced sentence length, dysprosodia and spastic dysarthria characterized spon-

taneous oral-verbal output. In contrast to spontaneous speech, imposed speech was significantly better preserved. Formal language tests revealed mild anomia, mild repetition disturbances and normal syntax. Oral reading was disturbed by phonological and visual errors and normalized after 18 months. A similar dissociation

Figure 1 (A) T2-weighted brain MRI (case 1) performed 5 months after stroke demonstrates a temporo-parietal infarction involving homologous Wernicke's area and the angular gyrus of the right hemisphere. (B) Non-enhanced CT scan of the brain (case 2) performed in the acute phase shows a large right temporo-parietal haematoma surrounded by oedema, a midline shift and an intraventricular blood level in the left occipital horn of the lateral ventricle. (C) T1-weighted brain MRI (case 3) revealing a right subcortical haemorrhagic infarction in the putamen. The lesion encroached upon the crus anterior of the internal capsule, the globus pallidus, the external capsule and the claustrum (not shown on this slice). (D) Non-enhanced CT scan of the brain (case 4) performed in the acute phase shows an ischaemic right subcortical lesion involving the caudate nucleus, the internal capsule, the external capsule and the putamen. (E) Non-enhanced CT scan of the brain (case 5) performed in the acute phase shows a hypodense cortico-subcortical lesion in the right temporal lobe. (F) Brain MRI axial FLAIR (case 6) performed 45 days after onset of the neurological symptoms shows an extensive fronto-temporo-parietal infarction in the right hemisphere. (G) Brain MRI axial FLAIR slice (case 7) demonstrates an extensive right temporo-parietal infarction, extensive bilateral white matter damage and diffuse cortical atrophy. (H) Brain MRI axial FLAIR (case 8) on day 25 of admission shows an extensive ischaemic lesion in the vascular territory of right middle cerebral artery. (I) Brain MRI axial FLAIR (case 9) performed 30 days after the stroke demonstrates an ischaemic lesion in the right temporo-parietal region involving the entire lateral part of the temporal lobe, the external capsule and the subcortical white matter of the parietal lobe.

between self-generated and imposed language characterized written language. After 18 months, the patient was still not able to write anything spontaneously although agraphic symptoms had clearly improved. Neuropsychological assessments disclosed left-sided neglect, afferent dysgraphia and constructional apraxia. These symptoms improved but did not resolve after 18 months.

Case 4

History

A 79-year-old right-handed woman with 9 years of schooling acutely developed mutism and left hemiplegia after a subcortical right hemisphere stroke. On admission the neurological examination additionally disclosed left homonymous hemianopia. The patient was alert and responded adequately to verbal instructions but could not speak. Any attempt to speak resulted in mere grunting. She could read and write. Non-verbal responses to the EI revealed an LQ of +100. Near relatives confirmed this strong and consistent right hand preference. Familial antecedents of left-handedness, evidence of early brain damage or a history of seizures were excluded. CT scan of the brain on admission (Fig. 1D) revealed a hypodense subcortical

lesion involving the parietal white matter of the right hemisphere. The lesion encroached upon the basal ganglia.

^{99m}Tc-HMPAO SPECT of the brain performed on the day of admission showed marked decrease of rCBF in the right hemisphere including the basal ganglia and the fronto-temporo-parietal region with slight occipital extension. Crossed cerebellar diaschisis was reflected by an area of diminished perfusion in the left hemisphere of the cerebellum. No perfusional deficits were encountered in the left cerebral hemisphere.

A neurolinguistic bed-side screening on the second day of admission evidenced a deterioration of language functions. Auditory-verbal comprehension was, in contrast to the day before, limited to elementary daily language. She could only respond to simple questions and was not able to express herself neither on command nor spontaneously. There was no automatic, over-learned language use. Repetition was impossible. All she was able to produce were some undifferentiated, poorly articulated, dysarthric grunts. Reading comprehension was totally disturbed and writing resulted in perseverative scribbles. On day 3 of admission she became globally aphasic. Consciousness remained normal. The next day her physical condition worsened progressively as a result of pneumonia. Within the next few days she became comatose. She deceased on day 13 of admission.

Post-mortem examination was performed. Gross inspection of the brain after formalin fixation showed haemorrhagic transformation of the ischaemic lesions. These involved the head, body and tail of the caudate nucleus, the corona radiata, the external capsule and the entire putamen. The genu and posterior limb of the internal capsule were extensively damaged (Fig. 2A–C). Macroscopical examination of the left hemisphere did not reveal vascular damage.

Case 5

History

A 38-year-old man was admitted to hospital after acute onset of left-sided weakness and speech difficulties. On admission the patient was alert, well-oriented and co-operative. His speech was fluent but contained many aphasic errors. Auditory-verbal comprehension was normal. Mild left sensory-motor deficits were found. On confrontation no visual field defects or spatial neglect phenomena were encountered. Apart from some minor stroke-like episodes during the week prior to admission, medical history was unremarkable. He was fully right-handed on the EI (LQ + 100) and had no familial antecedents of left-handedness. His educational level was 12 years. He was employed as a clerk in a firm.

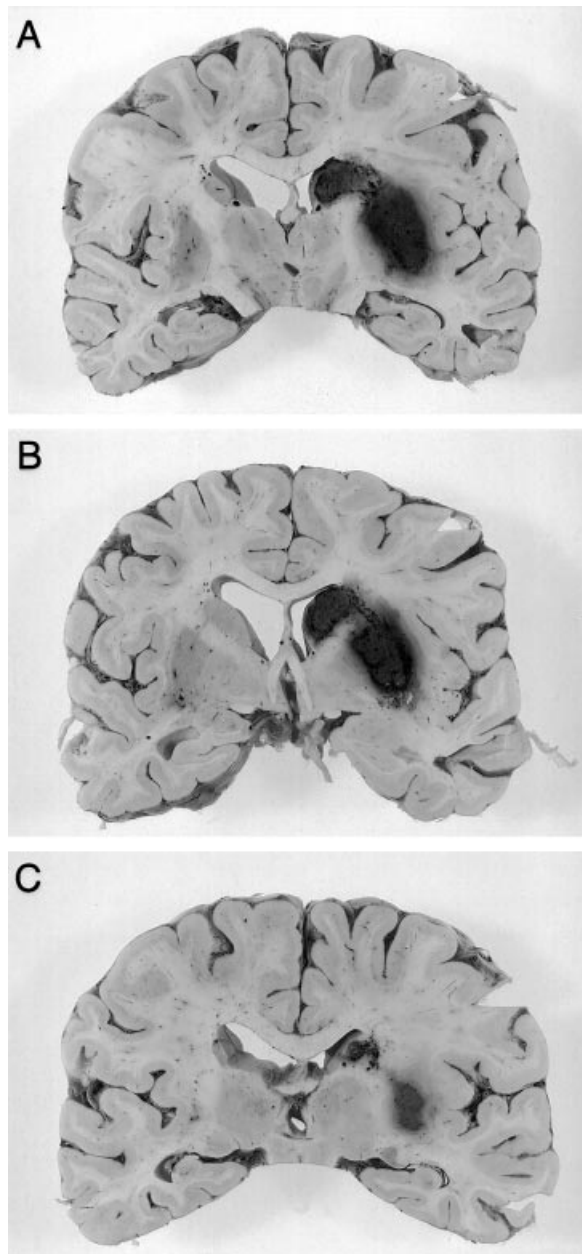


Figure 2 Serial 1.0-cm-thick coronal sections (case 4) from rostral to caudal (A,B,C) show haemorrhagic transformation of the right hemispheric ischaemic lesions involving the head, body and tail of the caudate nucleus, the genu and posterior limb of the internal capsule, the corona radiata, the external capsule and the entire putamen.

CT scan of the brain 2 days after admission revealed a hypodense right cortico-subcortical temporal lesion (Fig. 1E). MRI of the brain ruled out structural damage of the left hemisphere. Neurocognitive assessments were performed 9 days and 44 days after stroke.

Neurolinguistic and neuropsychological findings

Nine days after onset of the neurological symptoms, formal language assessments in this patient revealed conduction aphasia with severe anomia. Auditory-verbal and written language comprehension were normal. Notwithstanding some phonological errors, oral reading and spelling were within the normal range. Oral-verbal language, however, was disproportionately impaired. Phonemic paraphasias, phonemic approximations, numerous self-corrections and severe anomia disturbed otherwise fluent speech. Imposed speech was primarily affected by marked repetition disturbances with relatively intact number repetition. Severe constructional and drawing apraxia, modality-specific impairments of memory, attention and frontal lobe functions characterized the neuropsychological profile. In the lesion phase formal language assessments did not disclose severe residual deficits. Mild phonological disturbances persisted, however, in self-generated speech. Frontal lobe dysfunctions (problem solving) resolved in the lesion phase but constructional and drawing apraxia as well as visual memory and attention problems remained.

Case 6

History

A 61-year-old right-handed house-painter with 8 years of schooling was admitted to hospital for intense retrosternal pain. A transmural anterior myocardial infarction was diagnosed. Medical antecedents were negative. During the first night of admission he developed severe aphasia and left hemiplegia as the result of a haemorrhagic right hemisphere stroke. The neurological examination additionally showed gross auditory-verbal comprehension disturbances, incomprehensible speech, left hemianopia and spatial neglect. No reliable information was obtained regarding sensory functions. A CT scan of the brain disclosed an extensive right fronto-temporo-parietal hypodense lesion with slight mass effect. A focal hyperdense area indicated a haemorrhagic component. MRI of the brain performed 45 days after the onset of ictus confirmed the structural integrity of the left hemisphere (Fig. 1F).

The EI indicated strong right hand preference (LQ + 80). There were no familial antecedents of left-handedness. After 1 month the hemianopia and visual neglect phenomena had resolved. However, a predominantly non-fluent aphasia, hemiparesis and hypoesthesia persisted. Language was assessed 15 and 31 days after stroke. Neuropsychological examinations were performed on day 32.

Neurolinguistic and neuropsychological findings

Following a haemorrhagic stroke in the posterior right hemisphere this 61-year-old dextral patient developed severe Broca aphasia, expressive agrammatism, paralytic dysarthria, dysprosodia and mild afferent dysgraphia. Disrupted syntactic knowledge only induced on high linguistic complexity levels auditory-verbal comprehension disturbances. Reading comprehension, however, was normal. Phonological disturbances distorted visual confrontation naming. Verbal fluency was reduced. Spontaneous speech was limited to fragmented attempts and characterized by numerous phonemic paraphasias, agrammatism, word-finding disturbances, articulatory distortions and long pauses. During follow-up the aphasia ameliorated. However, 1 month after onset of stroke self-generated speech was still dysfluent, agrammatic and characterized by phonemic paraphasias. Repetition had not normalized. Dysarthric symptoms had receded but prosody remained abnormal. After remission of phonological errors oral reading also normalized. During follow-up the afferent dysgraphia ameliorated.

Neuropsychological investigations revealed visuo-constructive apraxia and disturbed visual memory.

Case 7*History*

An 86-year-old woman was admitted to hospital the day she developed severe aphasia and left hemiplegia. On admission she was confused and disoriented. In addition to fluent aphasia and left hemiplegia the neurological examination indicated left sensory loss and left hemianopia with visual neglect. Medical history included arterial hypertension. A grand-daughter, who lived together with the patient, reported onset of mild memory difficulties 2 months prior to this admission. These had no major repercussions on the patient's activities of daily life. The patient was said to be a strong dextral and had no familial history of left-handedness. An LQ of +100 was hetero-anamnesticly obtained. CT scan of the brain on the third day of admission revealed an extensive temporo-parietal hypodense lesion encroaching upon the basal ganglia of the right hemisphere. MRI of the brain additionally disclosed diffuse cortical atrophy and extensive white matter damage in both cerebral hemispheres (Fig. 1G).

One month after onset of symptomatology she was referred to our department. The patient was well-oriented and co-operative. Aside from neologistic jargon aphasia, the neurological examination revealed a flaccid left hemiparesis (4/5) with hyperreflexia, Hoffmann-Trömner sign and central facial nerve

paresis. The left plantar response was extensor. Left sensory disturbances persisted. On confrontation left hemianopia was found. ^{99m}Tc-HMPAO SPECT of the brain disclosed hypoperfusion of the entire vascular territory of the right middle cerebral artery. Relative hypoperfusion of the left cerebellar hemisphere was attributed to crossed cerebellar diaschisis. No perfusional deficits were observed in the left hemisphere. Neurocognitive assessments were performed 31 days after stroke.

Neurolinguistic and neuropsychological findings

This patient developed neologistic jargon aphasia. Auditory-verbal comprehension was grossly disturbed at basic linguistic levels. Speech mainly consisted of perseverative neologistic jargon intermingled with Dutch and French words. Articulation and prosody were preserved. Repetition, visual confrontation naming and syntax were severely distorted. Because of the severity of the aphasia, extensive neuropsychological investigations could not be performed. However, a concise psychometric screening revealed total acalculia, left visuo-spatial neglect, constructional apraxia and anosognosia.

Case 8*History*

A 61-year-old patient with 11 years of schooling developed left hemiplegia and aphasia the night before admission. On admission he uttered some undifferentiated sounds and displayed severe comprehension disturbances. Reading and writing was not possible. The neurological examination additionally revealed a left central facial nerve palsy, left hemiparesis and left-sided hyperreflexia. The left plantar response was extensor. The patient's medical history included arterial hypertension, acute myocardial infarction, coronary artery bypass and a surgically treated aneurysm of the abdominal aorta. He was strongly right-handed (LQ +100) and had no familial tract of left-handedness. CT scan of the brain on the day of admission showed some old periventricular lacunar infarctions. Four days later repeat CT disclosed an extensive ischaemic lesion in the right temporo-parieto-occipital region. Clinically relevant damage to the left hemisphere was excluded by means of brain MRI (Fig. 1H). Doppler duplex echography of the cervical blood vessels showed thrombosis of the right internal carotid artery as confirmed by means of MR angiography.

Formal neurolinguistic tests performed 18 days, 3 and 10 months after stroke revealed persistent non-fluent aphasia. Neuropsychological assessments were performed 3 months after stroke.

Neurolinguistic and neuropsychological findings

In the acute phase this patient showed severe non-fluent aphasia associated with expressive and receptive agrammatism, alexia and agraphia. In the lesion phase, language assessments revealed moderate auditory-verbal comprehension disturbances. Agrammatic errors, phonemic paraphasias, sound distortions and disrupted speech. Visual confrontation naming and repetition were most impaired at the sentence level. Left visual neglect errors and phonemic paralexias characterized oral reading. Reading comprehension was mildly disturbed for words and grossly defective for sentences. Dictational writing was mildly affected. Apart from a slight improvement of grammatical competence, the aphasic disturbances did not resolve during follow-up. Ten months post-stroke moderate Broca aphasia with mild speech apraxia and agrammatism persisted. Neuropsychological investigations disclosed pathological verbal and performance IQ levels, disturbed visual and verbal memory, constructional apraxia and left visuo-spatial neglect.

Case 9*History*

A 73-year-old right-handed man was admitted to hospital with angina pectoris. Four days after the patient underwent a coronary artery bypass graft, he developed left hemiparesis and near mutism associated with good comprehension. Atrial fibrillation was diagnosed. The clinical neurological examination revealed left central facial nerve palsy and left hemiparesis. MRI of the brain 30 days after the stroke showed an ischaemic lesion in the right temporo-parietal region involving the entire lateral part of the temporal lobe, the external capsule and the subcortical white matter of the parietal lobe (Fig. 11). Left hemiparesis and facial nerve palsy spontaneously recuperated within a few days.

Medical history consisted of arterial hypertension. The patient was fully right-handed (LQ + 100) and had no familial antecedents of left-handedness. Intensive physical therapy and speech and language training was started which resulted in almost complete recuperation of motor symptoms and partial amelioration of aphasia. Neurocognitive examinations were performed six and 32 days after onset of neurological symptoms.

Neurolinguistic and neuropsychological findings

At onset this patient developed severe conduction-like aphasia with total agraphia. Auditory-verbal comprehension was mildly disturbed. Oral-verbal output consisted of a severe lack of nouns, numerous 'condu-

ites d'approches' and phonemic paraphasias. Articulation was not disturbed and prosody and syntax were normal. He could not repeat. Although he could comprehend the meaning of written words, oral reading was impossible. There was total agraphia. During the lesion phase the aphasia evolved to typical conduction aphasia. Reassessment of spoken language 25 days later revealed normalization of written comprehension. Persistent deficits remained at all linguistic levels (auditory-verbal comprehension, speech, written language). On the neuropsychological level a partial Gerstmann syndrome accompanied mild constructional apraxia. Verbal memory could not be evaluated. Visual memory was normal.

Results**Neurolinguistic findings**

Neurolinguistic information was obtained in the acute phase for the entire group of nine cases. In-depth language assessments were performed in the lesion phase in eight patients (case 1, 2, 3, 4, 6, 7, 8, 9). One patient deceased in the acute phase (case 4). Four patients had a longitudinal follow-up extending beyond the lesion phase for more than 1 year (case 1, 3, 8).

Five patients presented non-fluent aphasia (three men, two women), four showed fluent aphasia (two men, two women). The non-fluent group comprises three patients with Broca aphasia (case 1, 6, 8), one patient with dynamic aphasia (case 3) and one patient with global aphasia (case 4). Two patients with conduction aphasia (case 5, 9), one patient with Wernicke aphasia (case 2) and one patient with neologistic jargon aphasia (case 7) belong to the fluent group. Mean age distribution between the non-fluent and fluent group was not different (66.8 and 65 years, respectively).

All patients displayed the most pronounced aphasic deficits in the acute phase. The aphasic profile of patient 3, who showed mild non-fluent aphasia at onset and more severe dynamic aphasia on day 26, is not an exception to this observation because language functions acutely deteriorated on day 6 as the consequence of a progressive stroke. Neurolinguistic data of the eight patients examined in the subsequent lesion phase showed that aphasia did not resolve rapidly. Two patients had no change of aphasic symptoms (case 2, 7). Four patients (case 1, 5, 6, 8) had improved at all linguistic levels: fluency, auditory-verbal comprehension, repetition, naming, reading and writing. Two patients displayed modality-specific improvements (case 3, 9). In contrast to oral language, written language functions ameliorated in case 3. The reversed pattern was found for case 9. In this case oral but not written

language improved. All four patients in whom formal language assessments were performed in the late phase displayed residual aphasic deficits. Mild Broca aphasia persisted in case 1, moderate Broca aphasia in case 8 and severe dynamic aphasia in case 3. Lesion phase data further disclosed a dissociated pattern of impairment between oral and written language in three patients (case 1, 3, 9). In these patients spelling was disproportionately more affected than oral language. Oral and written language were equally disturbed in the other four patients.

Five of the eight patients examined in the lesion phase had lesion-behaviour relationships comparable with those following an analogous lesion in the left hemisphere and are therefore mirror-image representatives (case 2, 3, 5, 7, 9). Case 2 developed persistent Wernicke aphasia following a temporo-parietal lesion. Patient 3 presented dynamic aphasia and spastic dysarthria after a progressive subcortical stroke (basal ganglia and paraventricular white matter of the parietal lobe). Patient 5 developed conduction aphasia in association with a cortico-subcortical temporal lesion. Patient 7 showed neologistic jargon aphasia after an extensive temporo-parietal lesion and patient 9 displayed conduction aphasia following damage to the entire lateral part of the temporal lobe, the external capsule and the subcortical white matter of the parietal lobe. The lesion-aphasia profile shared by the other three patients is anomalous because unexpected symptoms were found given the lesion site (case 1, 6, 8). Patient 1 showed predominantly non-fluent aphasia in association with a posteriorly located right hemisphere lesion involving Wernicke's area proper. Patients 6 and 8 developed Broca aphasia with relative sparing of auditory-verbal and reading comprehension rather than global aphasia despite large perisylvian lesions causing destruction of the classical language areas.

Neuropsychological findings

In all but one patient (case 4) neuropsychological investigations were performed in the lesion phase. Two patients were also extensively tested in the acute phase (case 1, 5) and two patients were re-examined in the late phase (case 1, 5). Severe fluent aphasia in two patients rendered extensive psychometric investigation impossible (case 2, 7). However, minimal neurocognitive information on praxis, visuo-spatial functions, and gnosis was obtained in all cases.

None of the patients under consideration showed ideomotor or ideational apraxia. Oral apraxia was present in one patient (case 8). Seven patients had constructional apraxia (case 2, 3, 5, 6, 7, 8, 9).

Left visual neglect characteristics were present in four patients (case 2, 3, 7, 8). One patient displayed in addition to visual neglect, severe left motor, tactile and auditory inattention (case 2).

Gnostic deficits were encountered in four patients (case 1, 2, 3, 7). All these patients displayed severe anosognosia. Finger agnosia was found in two patients (case 2, 7). Visual agnosia was not found in our study sample. All patients with longitudinal neuropsychological follow-up, recovered agnostic symptoms (case 1, 3).

Calculation was not tested in two patients (case 2, 3). Four patients presented acalculia (case 1, 7, 8, 9). Partial Gerstmann syndrome (disturbed right-left discrimination, fingeragnosia, acalculia, agraphia) with three of four cardinal symptoms present was found in two patients (case 1, 9).

In three patients a Wechsler IQ was assessed in the lesion phase (case 1, 7, 8). One patient had an entirely normal IQ profile (case 1). One patient had defective IQ levels with verbal and performance capacities equally affected (case 8). One patient had a normal VIQ and a pathological PIQ (case 5). Spatial reasoning was examined in two patients by means of the Coloured Progressive Matrices (case 3, 9). Patient 3 performed at a very low level (percentile 10), patient 9 obtained a normal score (percentile 50).

Memory was formally evaluated in six patients. Five patients were subjected to the Wechsler Memory Scale (case 1, 5, 6, 8, 9), one patient to the memory subtests of the Hierarchic Dementia Scale (case 3). Two patients had normal memory (case 1, 3). Two patients displayed a significant discrepancy between normal verbal memory and defective visual memory (case 5, 6). Patient 9 displayed the reversed profile characterized by normal visual memory and inassessible verbal memory functions. Memory was equally distorted at verbal and visual levels in one patient (case 8).

Discussion

All but one of the nine cases (case 8) presented fit current criteria for a diagnosis of vascular CAD: (i) aphasia evidenced, (ii) aphasiogenic lesion of vascular origin in the right hemisphere, (iii) strong right-hand preference with no familial antecedents of left-handedness, (iv) structural integrity of the left hemisphere ascertained, and (v) absence of early brain damage. In patient 8, extensive ischaemic damage in the peri- and para-ventricular white matter of the left hemisphere casts doubt on a clear-cut CAD diagnosis. We did not exclude this case for the present study because no direct clinical evidence was found for the relevance of these lesions on the aphasic symptoms: (i) the patient did not display any type of subcortical aphasia compatible with

the subcortical localization of the lesions in the left hemisphere (Alexander, 1989), (ii) the typical region of destruction of the patient's aphasia (neologistic jargon aphasia) was not damaged in the left but in the right hemisphere (Wernicke's area) (Buckingham and Kertesz, 1976) and (iii) in accordance with the findings of high performance MRI studies (Awad *et al.*, 1986; Hunt *et al.*, 1989; Fazekas *et al.*, 1991; Fukui *et al.*, 1994; Pantoni and Garcia, 1995) the subcortical left hemisphere lesions observed in this 86-year-old patient might represent clinically silent neuroradiological phenomena attributable to high age. Moreover, the fact that the aphasia in this patient occurred simultaneously with a left sensory-motor syndrome, has been considered in several prior CAD reports of patients with additional lesions in the left hemisphere a convincing point in favour of the aphasiogenic power of the right hemisphere damage (e.g. Yokoyama *et al.*, 1981; Sweet *et al.*, 1984; Alexander *et al.*, 1989; Caramelli *et al.*, 1994). Related to this issue, Castro-Caldas *et al.* (1986) called attention to the importance to carefully control for aetiology when a diagnosis of CAD is suspected. They reported a right-handed patient with post-traumatic conduction aphasia in whom the CT scan only disclosed a right frontal lesion. The EEG, however, additionally revealed a left occipito-temporal dysfunction that accounted for the aphasic manifestations. As a result, Castro-Caldas *et al.* (1986) cautioned against a possible bias of including traumatic cases in series of CAD and attributed the reported much higher incidence of CAD in traumatic patients (e.g. 18% in the Mohr *et al.*, 1980 study) to undetected contrecoup lesions in the left hemisphere.

Regarding the overall group characteristics, our group of nine vascular CAD patients seems to constitute a highly representative sample of some recently changed insights in CAD population characteristics. In comparison with patients with UCA, most studies of the 1970s and the early 1980s unequivocally emphasized the relative young age of CAD patients (Boller, 1973; Brown and Hécaen, 1976; Urbain *et al.*, 1978; Goldstein *et al.*, 1979; Donoso *et al.*, 1980; Joannette *et al.*, 1982). Brown and Hécaen (1976), for instance, reported in their review of 29 unselected CAD patients a mean age of 44.7 (SD 14.0) years. Subsequent studies on larger population samples did not confirm CAD patients to be relatively younger than UCA patients. In their comparative analysis of 39 vascular CAD patients with 390 UCA patients, Castro-Caldas and Confraria (1984) found an average age of 57.4 years for both groups and attributed the contrasting findings of prior studies to the inclusion of patients with non-vascular aetiology. Donoso (1984) and Coppens and Hungerford (1998) reported com-

parable mean age figures of 57.4 and 57.3 years, respectively, for adult CAD. The mean age of our group (65.7 years) is apparently higher than the figures previously reported. Although our limited sample size does not allow rigid conclusions regarding this difference, the mean age figure supports the view that vascular CAD patients are not by definition younger than UCA patients and seems to indicate that age is not a distinctive feature of vascular adult CAD. In the late 1970s also, the suggestion that the degree of left hemisphere dominance for language is lower in women than in men (Brown and Hécaen, 1976; Andrews, 1977; McGlone, 1977) established the view that CAD should be more frequent in women (Urbain *et al.*, 1978; Donoso *et al.*, 1980). Several later studies, however, consistently observed the opposite gender difference (Joannette *et al.*, 1982; Castro-Caldas and Confraria, 1984; Donoso, 1984; Coppens and Hungerford, 1998). Castro-Caldas and Confraria (1984), for instance, showed that the male to female ratio was higher in their group of CAD patients (32 men and seven women) than in their group of UCA patients (229 men and 161 women). The present sample of patients includes six men and three women which contradicts the prior opinion that the CAD population consists of more women than men.

In further contrast to the influential view advanced in the 1970s (Brown and Wilson, 1973; Brown, 1976; Brown and Hécaen, 1976; Urbain *et al.*, 1978; Barroche *et al.*, 1979; Goldstein *et al.*, 1979; Pillon *et al.*, 1979; Donoso *et al.*, 1980; Barroche *et al.*, 1981; Delreux *et al.*, 1989) our data support the view that CAD does not consist of a semiologically uniform syndrome but of a variety of symptoms comparable with UCA (Carr *et al.*, 1981; Joannette *et al.*, 1982; Henderson, 1983; Castro-Caldas and Confraria, 1984; Alexander *et al.*, 1989; Lanoë *et al.*, 1992; Coppens and Hungerford, 1998). In our patient group a broad and rich spectrum of non-fluent and fluent symptoms characterized the aphasia profiles in the acute, lesion and late phase. In the lesion phase, five of the eight patients examined displayed non-fluent aphasia and three fluent aphasia. This non-fluent to fluent ratio of 62.5 to 37.5% is comparable with the percentages found by Carr *et al.* (1981) (72 versus 27%) who in addition referred to similar distribution figures for UCA. Our lesion phase data add further evidence to Castro-Caldas and Confraria's findings (1984) that CAD and UCA populations are comparable in terms of aphasia type distribution with Broca aphasia as the most frequent type. A similar pattern of age differences among vascular UCA and CAD patients was also found in our population with Broca aphasics being younger than Wernicke aphasics (59.5 vs. 74.5 years, respectively). However, mean age

distribution between our non-fluent and fluent group of adult patients did not differ (66.8 and 65 years, respectively).

In contrast to the long-standing opinion that CAD is essentially a transient phenomenon (Bramwell, 1899; Holmes and Sadoff, 1966) or that it recovers much better and faster than UCA (Foroglou *et al.*, 1975; Brown, 1976; Brown and Hécaen, 1976; Urbain *et al.*, 1978; Goldstein *et al.*, 1979; Donoso *et al.*, 1980; Pita *et al.*, 1997; Özeren *et al.*, 1998) Coppens and Hungerford (1998) recently showed that the proportion of CAD cases associated with rapid recovery only represented a minority (< 9%) of the 114 reviewed cases with a vascular aetiology. These authors additionally demonstrated that the cases with transient aphasia shared no other common characteristics than their rapid and favourable outcome. In none of our patients the aphasic syndrome receded rapidly or completely. All but two patients (cases 2 and 7) improved after the acute phase. Four patients (case 1, 5, 6, 8) improved at all linguistic levels and two patients displayed modality-specific improvements (case 3, 9). All three patients with a follow-up in the late phase (case 1, 3, 8) still displayed aphasic deficits of variable severity. Mild Broca aphasia persisted in patient 1, moderate Broca aphasia in patient 8 and severe dynamic aphasia in patient 3.

Although striking semiological resemblances and highly comparable population characteristics hold between UCA and CAD, our data clearly demonstrate that CAD cannot be merely viewed as the mirror-image pattern of UCA in the opposite hemisphere (Joanette *et al.*, 1982). Five of the eight patients (62.5%) examined in the lesion phase had lesion-behaviour relationships comparable with those following an analogous lesion in the left hemisphere and could therefore be considered mirror-image representatives (case 2, 3, 5, 7, 9). The lesion-aphasia profile shared by the three other patients (37.5%) was anomalous because unexpected aphasia types were found, given the site of the lesion (case 1, 6, 8). As a consequence, the number of cases that violate classically expected lesion-aphasia correlates is much higher than the degree of anatomoclinical variability encountered in UCA populations (e.g. less than 13% in the Basso *et al.*, 1985 study). Patient 1 showed Broca aphasia in association with a posterior lesion involving the region homologous to Wernicke's area proper in the right hemisphere. Patients 6 and 8 developed Broca aphasia (and not global aphasia) in association with a large perisylvian lesion causing destruction of the homologous classical language areas in the right hemisphere. This pattern seems to indicate that language functions in these patients are represented bilaterally: expressive language

functions in the right hemisphere and receptive language functions in the left hemisphere. A similar hypothesis of dissociated bilateral language representation might be advanced for the other anomalous CAD case with a focal posterior lesion and non-fluent aphasia (case 1). However, the fact that in this patient the aphasiogenic lesion spared the anterior part of the right hemisphere leaves open the possibility of an intra-hemispheric inversion of the language centres in the right hemisphere (expressive language located posteriorly and receptive language anteriorly). Although more research on larger CAD populations is needed to correlate type of aphasia with lesion-aphasia configurations, the observation that all four patients with an anomalous lesion-aphasia profile are of the non-fluent type is striking and contrasts with Alexander *et al.*'s finding (1989) that all 12 anomalous cases (35.3%) identified in a series of 34 published CAD cases had fluent aphasia. However, it needs to be emphasized that correlations with Alexander *et al.*'s group (1989) are difficult because the operational criteria applied for CAD were different and the assessment and definition of lesion-aphasia profiles not based on the same parameters. The same holds for a comparison with the 26 anomalous CAD cases (35.1%) identified by Coppens and Hungerford (1998) in their review of 114 cases with vascular aetiology, but it seems that in this series non-fluent aphasias are overrepresented as well. An interesting line of future research in the understanding of the mechanisms underlying language organization might consist of a further specification and delineation of the anatomoclinical configurations in anomalous CAD by means of a methodological stringent approach that incorporates in addition to aetiological and time based factors also uniform parameters at the linguistic description level.

On the neuropsychological level our observations confirm that a variety of neurocognitive deficits may accompany CAD. Castro-Caldas *et al.* (1987) observed that in contrast to a lower incidence of ideomotor apraxia (17%), the incidence of oral apraxia in acute CAD (52%) is comparable with its incidence in acute UCA (60%). These observations led to the view that oral praxis tends to be lateralized in close functional and anatomic association with language and ideomotor skills with hand preference. Our data, however, demonstrate that the mechanisms subserving oral praxis are dissociable from oral language since oral apraxia was only present in one patient with non-fluent aphasia (case 9). Typical non-dominant hemisphere symptoms such as left visuo-spatial neglect and visuo-constructional apraxia have been reported to represent frequent phenomena in CAD. Castro-Caldas *et al.* (1987) found in 82% of the 66 reviewed CAD cases left visuospatial

neglect, an incidence which is twice as high the reported frequency of 33–46% in cases with right hemisphere lesions and left hemisphere language dominance (Hier *et al.*, 1983). Lesion phase data obtained in our sample do not confirm the view that neglect is a much more frequent phenomenon in CAD as it was only observed in four patients (case 2, 3, 7, 8). The relatively rare presence of left-sided neglect in our study group contradicts Castro-Caldas *et al.*'s hypothesis (1987) that in CAD the right hemisphere subserves both visuo-spatial functions and language and seems to suggest that in anomalous dextrals the mechanisms underlying attention and language may lateralize independently of one another to either hemisphere. On the other hand, the fact that seven of the eight patients in our series displayed symptoms of constructional apraxia (case 2, 3, 4, 6, 7, 8, 9) agrees with the findings of Castro-Caldas *et al.* (1987) that the 76% figure for constructional apraxia in CAD is significantly higher than the number of 45% reported for UCA. The observation that all patients with visuo-spatial neglect presented with constructional apraxia and that only three patients had constructional apraxia in isolation reflects the double nature of constructional apraxia as a visuo-spatial induced (case 2, 3, 7, 8) and as a genuine apraxic phenomenon (5, 6, 9). As this distinction is rarely reported in the CAD literature the incidence of constructional apraxia as a genuine apraxic disturbance might have been overestimated in prior reports.

In the literature on CAD to date there is little reference to other neurocognitive areas such as gnosis, calculation, orientation, memory and intelligence. Our data, however, seem to suggest that a more systematic approach of these functions might contribute to the further understanding of CAD. Most of the patients in the present study displayed severe modality-specific gnostic deficits: anosognosia (case 1, 2, 3, 7), finger agnosia (case 2, 7) and auditory-verbal agnosia (case 2). Recovery of gnostic functions was complete in both patients with longitudinal neuropsychological follow-up (case 1, 3). The majority of patients in whom calculation was formally tested (4 of 6) showed arithmetic disturbances (case 1, 7, 8, 9). Partial Gerstmann's syndrome (disturbed right-left discrimination, finger-agnosia, acalculia, agraphia) with three of four cardinal symptoms present was found in two patients (case 1, 9) in the acute phase. No consistent pattern was found in the Wechsler IQ and Wechsler memory profiles of the patients examined with these tests. One patient had a normal IQ (case 1). One patient (case 8) displayed a general decline of intelligence whereas another patient had a significant asymmetry between the verbal and performal IQ: VIQ > PIQ (case 5). Two patients subjected to the Wechsler Memory Scale obtained

normal results (case 1, 3). A generalized deterioration of verbal and visual memory was found in patient 7. Two patients displayed a modality-specific decrease: verbal memory was superior to visual memory in cases 5 and 6 while the reverse pattern was found in case 9. This study does not allow to draw firm conclusions about the incidence and significance of accompanying neurocognitive symptoms in CAD but it may be interesting to note that aphasia did not by definition disrupt verbally mediated neurocognitive functions such as verbal intelligence and verbal memory.

The neurolinguistic and neuropsychological data of the first patient of this study illustrate the relevance of our plea for a more systematic approach of neuropsychological functions in CAD and add evidence to the importance of this approach in the identification of brain-behaviour relationships in anomalous dextrals. In this patient with an anomalous inter- and intra-hemispheric lesion-aphasia profile (crossed Broca aphasia after a parietal infarction), in-depth neurocognitive assessments disclosed a configuration of symptoms suggesting a complete *situs inversus* of neurocognitive functions. In the first place, a partial crossed Gerstmann's syndrome (Gerstmann, 1940) was found after destruction of the typical lesion area (left parietal region with the angular gyrus crucially involved) in the right hemisphere. The fact that this syndrome was caused by a homologous lesion in the opposite hemisphere adds evidence to the dominant qualities of the right hemisphere and seems to implicate that on the intrahemispherical level at least some dominant parietal brain functions were not organized anomalously. In addition, the absence of typical 'minor' hemisphere symptoms such as left neglect and visuo-spatial deficits indicates that attentional and visuo-spatial functions were not typically subserved by the posterior right hemisphere. However, it remains unsettled whether these functions were strongly lateralized in the 'minor' left hemisphere or represented anomalously in the structurally intact parts of the right hemisphere. Although it is plausible to believe that a single gene is responsible for the laterality of many brain functions (Alexander and Annett, 1996), no theory of CAD to date can sufficiently account for the dissociations in the intra-hemispherical organization of the dominant hemisphere functions in this patient. Future studies are needed in which the application of well-balanced functional neuroimaging paradigms might contribute to the clarification of these issues.

Conclusions

Several conclusions can be made from this study. First, there is no consensus in the literature on CAD

regarding the relevance of additional vascular lesions in the left hemisphere. Therefore, a common standpoint is needed to define the relevance of these lesions for conclusions regarding anatomoclinical correlations in CAD. Secondly, our study adds evidence to some recently changed insights in CAD. Regarding the population characteristics our study suggests that: (i) vascular CAD patients are not younger than UCA patients and (ii) the CAD group does not consist of more women than men. On the semiological level our study corroborates the view that CAD is not a semiologically uniform syndrome with good recovery but built-up by a variety of symptoms with an aphasia type distribution and an evolution comparable with UCA. Thirdly, our data show that on the anatomoclinical level CAD can not be merely viewed as the mirror-image pattern of UCA in the opposite hemisphere and that different, even dissociated inter- and intra-hemispherical language lateralization patterns are likely to occur far much frequently than in UCA. Fourthly, it is demonstrated that a variety of neurocognitive deficits may accompany CAD. Our data support the hypothesis that the mechanisms subserving oral praxis are dissociable from oral language but do not confirm the view that the right hemisphere subserves both visuo-spatial functions and language. They further indicate that the incidence of constructional apraxia as a genuine apraxic disturbance might have been overestimated in prior reports and demonstrate our plea that a more systematic approach of neurocognitive functions might contribute to the further understanding of the semiological variability of CAD phenomena and the many faces of the lesion-behaviour relationships in this exceptional neurobiological condition.

Acknowledgements

The technical assistance (photographic work) of Mrs Inge Bats and Mr Jan Cruysberghs is gratefully acknowledged. Supported by OCMW Medical Research Foundation and Born-Bunge Foundation, University of Antwerp. S.E. is a Research Assistant of the Fund for Scientific Research – Flanders (F.W.O. – Vlaanderen).

References

- Alexander MP (1989). Clinical-anatomical correlations of aphasia following predominantly subcortical lesions. In: Boller F, Grafman J eds. *Handbook of Neuropsychology*, Vol. 2. Elsevier Science Publishers, Amsterdam, pp. 47–66
- Alexander MP, Annett M (1996). Crossed aphasia and related anomalies of cerebral organization: case reports and a genetic hypothesis. *Brain and Language* **55**:213–239.
- Alexander MP, Fischette MR, Fischer RS (1989). Crossed aphasias can be mirror image or anomalous. *Brain* **112**:953–973.
- Andrews R (1977). Aspects of language lateralization correlated with familial handedness. *Neuropsychologia* **15**:769–778.
- Awad IA, Spetzler RF, Hodak JA, Awad CA, Carey R (1986). Incidental subcortical lesions identified on magnetic resonance imaging in the elderly. I: correlation with age and cerebrovascular risk factors. *Stroke* **17**:1084–1089.
- Barroche G, Presles O, Ramel P, Weber M, Arnould G (1979). L'aphasie croisée chez le droitier. *Revue Otonéuroophthalmologique* **51**:251–262.
- Barroche G, Marchal JC, Ascaillas JP, Rivail J, Lepoivre J (1981). Aphasie par lésion hémisphérique droite chez une droitière. *Revue Otonéuroophthalmologique* **53**:389–399.
- Basso A, Lecours AR, Moraschini S, Vanier M (1985). Anatomoclinical correlations of the aphasias as defined through computerized tomography: exceptions. *Brain and Language* **26**:201–229.
- Bastiaanse R, Bosje M, Visch-Brink E (1995). *Psycholinguistic Assessments of Language Processing in Aphasia*. (Dutch Edition). Lawrence Erlbaum Associates, East Sussex, UK.
- Benton AL, deS Hamsher K, Varney NR, Spreen O (1983). *Contributions to Neuropsychological Assessment: a Clinical Manual*. Oxford University Press, New York.
- Boller F (1973). Destruction of Wernicke's area without language disturbance. *Neuropsychologia* **11**:243–246.
- Bramwell B (1899). On 'crossed' aphasia and the factors which go to determine whether the 'leading' or 'driving' speech-centres shall be located in the left or in the right hemisphere of the brain, with notes on a case of 'crossed' aphasia (aphasia with right-sided hemiplegia in a left-handed man). *Lancet* **1**:1473–1479.
- Brown JW (1976). The neural organization of language: aphasia and lateralization. *Brain and Language* **3**:482–494.
- Brown JW, Wilson FR (1973). Crossed aphasia in a dextral. *Neurology* **23**:907–911.
- Brown JW, Hécaen H (1976). Lateralization and language representation: observations on aphasia in children, left-handers, and 'anomalous' dextrals. *Neurology* **26**:183–189.
- Buckingham HW, Kertesz A (1976). Neologistic jargon aphasia. In: Hoops R, Lebrun Y, eds. *Neurolinguistics: an International Series Devoted to Speech Physiology and Speech Pathology*, Vol. 3. Swets & Zeitlinger, Amsterdam.
- Caramelli P, Parente MAMP, Hosogi ML, Bois M, Lecours AR (1994). Unexpected reading dissociation in a Brazilian 'nisei' with crossed aphasia. *Behav Neurol* **7**:165–170.
- Carr MS, Jacobson T, Boller F (1981). Crossed aphasia: analysis of four cases. *Brain and Language* **14**:190–202.
- Castro-Caldas A, Confraria A (1984). Age and type of CA in dextrals due to stroke. *Brain and Language* **23**:126–133.
- Castro-Caldas A, Confraria A, Paiva T, Trindade A (1986). Contrecoup injury in the misdiagnosis of crossed aphasia. *J Clin Exp Neuropsychol* **8**:697–701.
- Castro-Caldas A, Confraria A, Poppe P (1987). Non-verbal disturbances in crossed aphasia. *Aphasiology* **1**:403–413.
- Cole MG, Dastoor D (1987). A new hierarchic approach to the measurement of dementia. *Psychosomatics* **28**:298–305.
- Coppens P, Hungerford S (1998). Crossed aphasia. In: Coppens P, Lebrun Y, Basso A, eds. *Aphasia in Atypical Populations*. Lawrence Erlbaum Associates, NJ, USA, pp. 203–260.

- De Renzi E, Vignolo LA (1962). The token test: a sensitive test to detect receptive disturbances in aphasia. *Brain* **85**:665–678.
- Delreux V, de Partz MP, Kevers L, Callewaert A (1989). Aphasie croisée chez un droitier. *Revue Neurologique* **145**:725–728.
- Donoso A (1984). Crossed aphasia in dextrals. In: Ardila A, Ostrosky-Solis F, eds. *The Right Hemisphere: Neurology and Neuropsychology*. Gordon and Breach, New York, pp. 125–143.
- Donoso A, Vergara E, Santander M (1980). Las afasias cruzadas en los diestros. *Acta Neurologica Latinoamerica* **26**:238–257.
- Fazekas F, Schmidt R, Offenbacher H *et al.* (1991). Prevalence of white matter and periventricular magnetic resonance hyperintensities in asymptomatic volunteers. *J Neuroimaging* **1**:27–30.
- Folstein M, Folstein S, McHugh P (1975). Mini-Mental State: a practical method for grading the cognitive state of patients for the clinician. *J Psychiatry Res* **12**:189–198.
- Foroglou G, Assal G, Zander E (1975). Une nouvelle observation d'aphasie croisée chez un droitier. *Schweizer Arch Neurologie, Neurochirurgie Psychiatrie* **117**:205–210.
- Fukui T, Sugita K, Sato Y, Takeuchi T, Tsukagoshi H (1994). Cognitive functions in subjects with incidental cerebral hyperintensities. *European Neurol* **34**:272–276.
- Gerstmann J (1940). Syndrome of finger agnosia, disorientation for the right and left, agraphia and acalculia. *Arch Neurol Psychiatry* **44**:398–408.
- Goldstein B, Vaillant C, Laplanche A, Pépin B (1979). Aphasie croisée chez les droitiers. *Concours Méd* **101**:549–555.
- Goodglass H, Kaplan E (1983). *The Assessment of Aphasia and Related Disorders*, 2nd edn. Lea & Febiger, Philadelphia.
- Graetz P, De Bleser R, Willmes K (1992). *De Akense Afasie Test*. Swets & Zeitlinger, Lisse, The Netherlands.
- Grant DA, Berg EA (1993). *Wisconsin Card Sorting Test*. Psychological Assessment Resources, Odessa, FL, USA.
- Hécaen H, Mazars G, Ramier AM, Goldblum MC, Merienne L (1971). L'aphasie croisée chez un sujet bilingue (vietnamien–français). *Revue Neurologique* **124**:319–323.
- Henderson VW (1983). Speech fluency in crossed aphasia. *Brain* **106**:837–857.
- Hier DB, Mondlock J, Caplan LR (1983). Behavioral abnormalities after right hemisphere stroke. *Neurology* **33**:337–344.
- Holmes JE, Sadoff RL (1966). Aphasia due to a right hemisphere tumor in a right-handed man. *Neurology* **16**:392–397.
- Hunt AL, Orrison WW, Yeo RA *et al.* (1989). Clinical significance of MRI white matter lesions in the elderly. *Neurology* **39**:1470–1474.
- Joanette Y, Puel M, Nespoulous JL, Rascol A, Lecours AR (1982). Aphasie croisée chez les droitiers. *Revue Neurologique* **138**:575–586.
- Kaplan E, Goodglass H, Weintraub S (1983). *The Boston Naming Test*. Lea & Febiger, Philadelphia, USA.
- Lanoë Y, Fabry B, Lanoë A, Pedetti L, Fahed M, Benoît T (1992). Aphasie croisée chez un adulte: représentation du langage dans les deux hémisphères. *Revue Neuropsychologie* **2**:373–392.
- Lezak MD (1983). *Neuropsychological Assessment*. Oxford University Press, New York.
- Mariën P, Mampaey E, Vervaeke A, Saerens J, De Deyn PP (1998). Normative data for the Boston Naming Test in native Dutch-speaking Belgian elderly. *Brain and Language* **65**:447–467.
- Mariën P, Engelborghs S, Paquier P, De Deyn PP (2001a). Anomalous cerebral language organization: acquired crossed aphasia in a dextral child. *Brain and Language* **76**:145–157.
- Mariën P, Paquier Ph, Cassenaer S, De Deyn PP (2001b). The history of crossed aphasia: confluence of concepts. *J Neurolinguistics*.
- Mariën P, Paquier Ph, Engelborghs S, De Deyn PP (2001c). Acquired crossed aphasia in dextral children revisited. *Brain Language*.
- Mazzocchi F, Vignolo LA (1979). Localisation of lesions in aphasia: clinical-CT scan correlations in stroke patients. *Cortex* **15**:627–654.
- McGlone J (1977). Sex differences in the cerebral organization of verbal functions in patients with unilateral brain lesions. *Brain* **100**:775–793.
- Mohr JP, Weise GH, Caviness HF *et al.* (1980). Language and motor disorders after penetrating head injury in Vietnam. *Neurology* **30**:1273–1279.
- Oldfield RC (1971). The assessment and analysis of handedness: the Edinburgh Inventory. *Neuropsychologia* **9**:97–113.
- Özeren A, Mavi H, Sarica Y, Karatas M (1998). Subcortical crossed aphasia. *Acta Neurologica Belgica* **98**:204–208.
- Pantoni L, Garcia JH (1995). The significance of cerebral white matter abnormalities 100 years after Binswanger's report: a review. *Stroke* **26**:1293–1301.
- Pillon B, Desi M, Lhermitte F (1979). Deux cas d'aphasie croisée avec jargonographie chez des droitiers. *Revue Neurologique* **135**:15–30.
- Pita G, Karavelis A, Foroglou G (1997). Crossed aphasia with alalia in Greek – a case study; extent of a problem. *J Neurolinguistics* **10**:1–9.
- Raven JC (1976). *Coloured Progressive Matrices*. HK Lewis, London.
- Rosen WG, Mohs RC, Davis KL (1984). A new rating scale for Alzheimer's disease. *Am J Psychiatry* **141**:1356–1364.
- Stinissen J, Willems PJ, Coetsier P, Hulsman WLL (1970). *Handleiding Bij de Nederlandstalige Bewerking Van de Wechsler Adult Intelligence Scale (WAIS)*. Swets and Zeitlinger, Lisse, The Netherlands.
- Sweet EWS, Panis W, Levine DN (1984). Crossed Wernicke's aphasia. *Neurology* **34**:475–479.
- Taylor HG, Salomon JR (1979). Reversed laterality: a case study. *J Clin Neuropsychol* **1**:311–322.
- Urbain E, Seron X, Remits A, Cobben A, Van der Linden M, Mouchette R (1978). Aphasie croisée chez une droitière. *Revue Neurologique* **134**:751–759.
- Wechsler D (1945). A standardized memory scale for clinical use. *The J Psychol* **19**:87–95.
- Wechsler D (1984). *Wechsler Memory Scale – Revised*. Psychological Corporation, New York.
- Yarnell PR (1981). Crossed dextral aphasia: a clinical radiological correlation. *Brain and Language* **12**:128–139.
- Yokoyama K, Okubo M, Doseki K, Yamadori A (1981). Jargonaphasia in crossed motor aphasia. *Rinsho Shinkeigaku* **21**:961–967.