

## Cerebral vasculitis and ischaemic stroke in Behçet's disease: report of one case and review of the literature

Y. Krespi, G. Akman-Demir, M. Poyraz, B. Tugcu, O. Coban, R. Tuncay, P. Serdaroglu and S. Bahar

Department of Neurology, Istanbul Faculty of Medicine, University of Istanbul, Istanbul, Turkey

### Keywords:

Behçet's disease, ischaemic stroke, vasculitis

Received 23 May 2001

Accepted 5 July 2001

**Introduction.** Behçet's disease (BD) is a multisystemic, recurrent, inflammatory disorder. Neurological involvement is well-known but cerebral vasculitis and ischaemic stroke are unusual.

**Case description.** A 43-year-old male patient presented with acute left hemiparesis, he had recurrent oral aphthae and scrotal ulcerations. Two episodes of transient brainstem ischaemia and an episode of right hemiparesis were reported in the past 2 years. Cranial magnetic resonance (MR) imaging showed a right striatocapsular infarction and multiple segmental stenosis, fusiform enlargement and beading of the arteries of the polygone of Willis were seen on angiography. Cerebro-spinal fluid (CSF) examination disclosed lymphocytic pleocytosis. Skin pathergy test was positive. A diagnosis of BD with cerebral vasculitis was made and immunosuppressive therapy was started. Some improvement of the arterial lesions on MR angiography and normalization of CSF were observed after 1 year of treatment.

**Discussion.** Low grade chronic meningo-encephalitis is the core neuropathological process in neuro-Behçet's disease. Nevertheless BD is a systemic disease known to cause vasculitis and can exceptionally lead to cerebral vasculitis and brain infarction. While BD is usually not part of the differential diagnosis of cerebral vasculitis, it should be borne in mind especially in endemic areas of the disease and in patients from these areas.

### Introduction

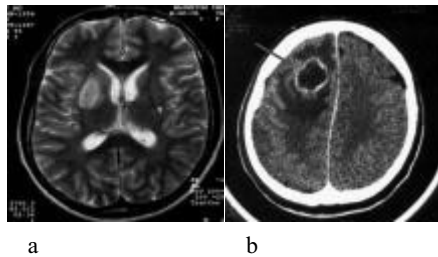
Behçet's disease (BD), is a multisystemic, recurrent, inflammatory disorder, also affecting the nervous system. Neurological involvement in BD has two common features: parenchymal involvement and non-parenchymal involvement, also called cerebral angio-Behçet's syndrome that mainly encompasses cases with dural sinus thrombosis (Akman-Demir *et al.*, 1996). Ischaemic stroke and cerebral vasculitis are unusual manifestations during the course of BD.

### Case report

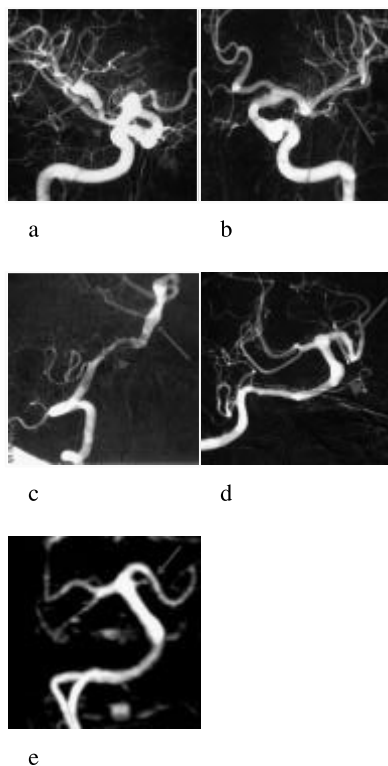
A 43-year-old male presented in October 1997, 10 days after acute left hemiparesis and dysarthria. He reported an episode of right hemiparesis that lasted 2 days in December 1995. In January 1996 he was evaluated for acute diplopia, nausea and vomiting that regressed in 3 days. A small old left putaminal infarct, which was probably responsible for the previous episode, was seen

on cranial computerized tomography (CT). He also reported an episode of acute vertigo, nausea, vomiting, ataxia and diplopia that lasted 2 days in May 1997. He had a 20-year history of recurrent oral aphthae and three episodes of scrotal ulceration. No vascular risk factor other than cigarette smoking was reported. On admission his physical examination was normal. He had dysarthria and left hemiparesis with left central facial paresis. Deep tendon reflexes were brisk on the left side with a left Babinski sign. Erythrocyte sedimentation rate was 40 mm at 1 h. Haemogram and serum chemistry were normal. Skin pathergy test performed as described before (Dilsen *et al.*, 1986) was negative. Cranial magnetic resonance imaging (MRI) showed a well delineated right basal ganglia and capsular lesion, with no mass effect and which was slightly enhanced after gadinium (Gd-DTPA) injection in addition to an old left putaminal infarct (Fig. 1a). The new lesion was compatible with a striatocapsular infarction. Cerebral digital subtraction angiography (DSA) revealed multiple segmental stenosis, fusiform enlargement and beading of the arteries of the polygone of Willis (Fig. 2a–d). Cerebro-spinal fluid (CSF) examination disclosed lymphocytic pleocytosis (28/mm<sup>3</sup> lymphocytes, 6/mm<sup>3</sup> polymorphonuclear leucocytes) and high protein content (0.66 g/l). The angiographic features

Correspondence: Yakup Krespi MD, Department of Neurology, Istanbul Faculty of Medicine, University of Istanbul, Millet cad, 34390, Çapa, Istanbul, Turkey (fax: +90-212-533-43-93; e-mail: mykrespi@superonline.com).



**Figure 1** Magnetic resonance imaging T2-weighted images in axial plane (a) show a striatocapsular infarct and a small old infarct area in the left putamen (arrow-head). (b) Control cranial computerized tomography examination shows a right frontal abscess formation with perilesional oedema in the area of biopsy (arrow).



**Figure 2** Digital subtraction angiography: (a) stenosis (arrow-head) and fusiform enlargement (arrow) of right middle cerebral artery (MCA) M1 segment; (b) tubular narrowing of distal left MCA M1 and proximal M2 segment (arrow); (c) slight stenosis of distal part of the V4 segment of right vertebral artery (VA) (arrow-head) and irregularities of the basilar artery (BA) (arrow); (d) ectasic appearance of proximal segment of BA (arrow-head) and beading of P1 and P2 segment of left posterior cerebral artery (PCA) (arrow). (e) On control magnetic resonance angiography 12 months later, the beading appearance of left PCA P1 and P2 segments is improved.

and the lymphocytic pleocytosis were considered in favour of an indolent meningo-vasculitic process, which was probably evolving for 2 years, and was the putative

stroke mechanism. There was no clinical or serological evidence in favour of any other cause of cerebral vasculitis. A diagnostic right frontal leptomenigeal and cortical biopsy was performed at the 60th day of the hospitalization that showed normal brain and leptomenigeal tissue.

During the hospital course, he developed florid oral aphtae and scrotal ulcers and a repeat skin pathergy test was now positive. On the 11th day after the biopsy he had a left simple motor seizure and his left hemiparesis progressively worsened. A control cranial CT examination revealed a right frontal abscess formation with perilesional oedema in the area of biopsy (Fig. 1b). Smears prepared from the aspiration specimen disclosed a haemorrhagic exudate, which was rich in neutrophils and macrophages. Gram staining, aerobic and anaerobe cultures remained negative. Antibiotic (meropenem 6 g/day) and methylprednisolone 48 mg/day was started and the patient showed clinical and radiological improvement. A chest CT showed bilateral pulmonary artery aneurysms that had a thrombosed appearance on the right side, pointing to asymptomatic pulmonary artery vasculitic involvement. A diagnosis of BD with presumed cerebral vasculitis and a consequent brain infarction was made. Monthly 1 g IV cyclophosphamide for 12 months was added to steroid therapy.

Repeat CSF examination was normal at the 6th month of therapy. At the 12th month of therapy cranial MRI showed a residual infarct area in the right putamen and MR angiography, although less sensitive than conventional angiography, showed improvement of beading appearance of P1 and P2 segments of the left posterior cerebral artery (PCA) (Fig. 2e) and practically no change in other arteries. The patient was neurologically stable after 3.5 years of follow up.

## Discussion

Our patient fulfilled the diagnostic criteria for BD (International Study Group For Behçet's Disease, 1990); he had more than three episodes of oral aphtae, active genital ulceration and a positive pathergy test. Moreover, he also had asymptomatic pulmonary artery aneurysms, which is considered pathognomonic of Behçet's vasculitis (Park *et al.*, 1984). He presented with cerebral vasculitis and the new striatocapsular lesion seen on MRI was compatible with a middle cerebral artery (MCA) deep territory infarction. This lesion was well differentiated from the typical basal ganglia involvement observed during acute attacks of neuro-Behçet, which is confluent and not fitting within any arterial territory (Çoban *et al.*, 1999). We were intrigued by the appearance of a cerebral abscess after

the cerebral biopsy that was contemporaneous with a strongly positive skin pathergy test. Although negative bacteriological studies could not definitely rule out a pyogenic brain abscess, we think that this lesion might probably be the result of an aseptic focal brain inflammatory response to the non-specific physical insult of the biopsy procedure and was reminiscent of skin pathergy reaction. Concomitant appearance of florid oral aphthae and scrotal ulcers were considered in favour of this second hypothesis. To our knowledge such focal reaction in the brain has not been previously described in BD.

The constellation of cerebral vasculitis and brain infarction represent a particular and unusual form of cerebral angio-Behçet's syndrome. This patient is the only case of cerebral vasculitis in our large registry including 200 neuro-Behçet cases (Akman-Demir *et al.*, 1999). Another patient in this series with right brain-stem infarction had right extra-cranial vertebral artery (VA) dissection because of vasculitis and was previously reported (Bahar *et al.*, 1993). During the course of BD, arterial involvement is rare (1–5%) and peripheral arteries are most commonly involved with aneurysm and pseudo-aneurysm formation or occlusion (Dilsen *et al.*, 1993). Histological studies demonstrate a non-specific vasculitis with mononuclear cells or neutrophilic infiltration, endothelial cell proliferation, destruction of internal elastic lamina, fibrinoid necrosis and thrombus formation (Matsumoto *et al.*, 1991). Vasculitis of vasa vasorum is generally held responsible for aneurysm or pseudo-aneurysm formation (Matsumoto *et al.*, 1991). Cerebral vasculature can also be involved in BD. While intra- or extra-cranial isolated fusiform or saccular aneurysm formation is a rather well-known entity, intra-cranial cerebral artery stenosis or occlusion are very rare and only five cases have been reported in the literature (Bienenstock and Murray, 1961; Iragui and Maravi, 1986; Buge *et al.*, 1987; Zelenski *et al.*, 1989; Nishimura *et al.*, 1991). Except one patient (Zelenski *et al.*, 1989), all these cases were neurologically symptomatic and presented with transient (Bienenstock and Murray, 1961; Iragui and Maravi, 1986) or established neurological deficits contralateral to the affected artery (Bienenstock and Murray, 1961; Buge *et al.*, 1987; Nishimura *et al.*, 1991); hemiparesis being the most frequent manifestation (Bienenstock and Murray, 1961; Iragui and Maravi, 1986; Buge *et al.*, 1987; Nishimura *et al.*, 1991). In one report the neurological deficit was considered to be the result of a cerebral infarction in the deep territory of the middle cerebral artery (MCA), but brain imaging findings were not provided (Buge *et al.*, 1987). Angiography disclosed fusiform aneurysmal dilatations (Buge *et al.*, 1987; Zelenski *et al.*, 1989), stenoses (Iragui and Maravi,

1986; Buge *et al.*, 1987; Zelenski *et al.*, 1989) or occlusions (Bienenstock and Murray, 1961; Buge *et al.*, 1987; Nishimura *et al.*, 1991) of proximal segments of medium sized intra-cranial vessels, usually of the MCA that was sometimes associated with more peripheral small vessel involvement (Zelenski *et al.*, 1989). In all cases there was convincing evidence that a vasculitic process underlined the arterial changes. High protein content and/or pleocytosis of CSF were seen in all the patients. In two patients there was vasculitis elsewhere; pulmonary in one (Buge *et al.*, 1987) and retinal in two cases (Buge *et al.*, 1987; Zelenski *et al.*, 1989). Spontaneous progression (Buge *et al.*, 1987) or regression of the arterial changes under immunosuppressive therapy (Iragui and Maravi, 1986; Zelenski *et al.*, 1989) pleaded also in favour of vasculitis in three patients. One autopsy study clearly demonstrated neuropathological findings consistent with panarteritis of branches of the MCA causing occlusion and infarction in its territories (Nishimura *et al.*, 1991).

Usually rather than a true vasculitis, a low grade chronic meningoencephalitis is considered to be the principal neuropathological process in neuro-Behçet's disease (Hadfield *et al.*, 1997). On the other hand, BD is a systemic disease known to cause vasculitis and can rarely lead to cerebral vasculitis. This is the exception and one should always be cautious in making this diagnosis. In routine clinical practice BD is usually not part of the differential diagnosis of cerebral vasculitis but it should, nevertheless be borne in mind especially in endemic areas of the disease and in patients from these areas.

## References

- Akman-Demir G, Bahar S, Baykan-Kurt B, Hakan Gürvit I, Serdaroğlu P (1996). Intracranial hypertension in Behçet's disease. *European J Neurol* **3**:66–70.
- Akman-Demir G, Serdaroğlu P, Taşçı B and the Neuro-Behçet Study Group (1999). Clinical patterns of neurological involvement in Behçet's disease: evaluation of 200 patients. *Brain* **122**:2171–2181.
- Bahar S, Coban O, Gürvit IH, Akman-Demir G, Gokyigit A (1993). Spontaneous dissection of the extracranial vertebral artery with spinal subarachnoid haemorrhage in a patient with Behçet's disease. *Neuroradiology* **35**:352–354.
- Bienenstock H, Murray EM (1961). Behçet's syndrome: report of a case with extensive neurologic manifestations. *New England J Med* **264**:1342–1345.
- Buge A, Vincent G, Rancurel D, Dorra M, Betourne C (1987). Maladie de Behçet avec anevrysmes arteriels multiples intracranien. *Revue Neurologique (Paris)* **143**:832–835.
- Çoban O, Bahar S, Akman-Demir G *et al.* (1999). Masked assessment of MRI findings: is it possible to differentiate neuro-Behçet's disease from other CNS diseases. *Neuroradiology* **41**:255–260.
- Dilsen N, Koniçe M, Aral O, Aykut S (1986). Standardization and evaluation of the skin pathergy test in Behçet's disease

- and controls. In: Lehner T, Barnes CG, eds. *Recent Advances in Behçet's Disease*. London Royal Society of Medicine Services, pp. 169–172.
- Dilsen N, Koniçe M, Aral O, Ocal L, Inanç M, Gül A (1993). Risk factors for vital organ involvement in Behçet's disease. In: Wechsler B, Godeau P, eds. *Behçet's Disease*. Amsterdam: Elsevier, pp. 165–169.
- Hadfield MG, Aydin F, Lippman HR, Sanders KM (1997). Neuro-Behçet's disease. *Clin Neuropathol* **16**:55–60.
- International Study Group For Behçet's Disease (1990). Criteria for diagnosis of Behçet's disease. *Lancet* **335**:1078–1080.
- Iragui VJ, Maravi E (1986). Behçet's syndrome presenting as cerebrovascular disease (letter). *J Neurol Neurosurgery Psychiatry* **49**:838–840.
- Matsumoto T, Uekusa T, Fukuda Y (1991). Vasculo-Behçet's disease: a pathologic study of eight cases. *Human Pathol* **22**:45–51.
- Nishimura M, Satoh K, Suga M, Oda M (1991). Cerebral angio- and neuro- Behçet's syndrome: neuroradiological and pathological study of one case. *J Neurol Sci* **106**:19–24.
- Park JH, Han MC, Bettmann MA (1984). Arterial manifestations of Behçet's disease. *Am J Roentgenol* **143**:821–825.
- Zelenski JD, Capraro JA, Holden D, Calabrese LH (1989). Central nervous system vasculitis in Behçet's syndrome: angiographic improvement after therapy with cytotoxic agents. *Arthritis Rheumatism* **32**:217–220.